HemaClear®

Sterile & Bloodless Surgical Field

Sterile Exsanguination Tourniquet

WHITE PAPERS

www.HemaClear.com

HemaClear®
Sterile & Bloodless Surgical Field

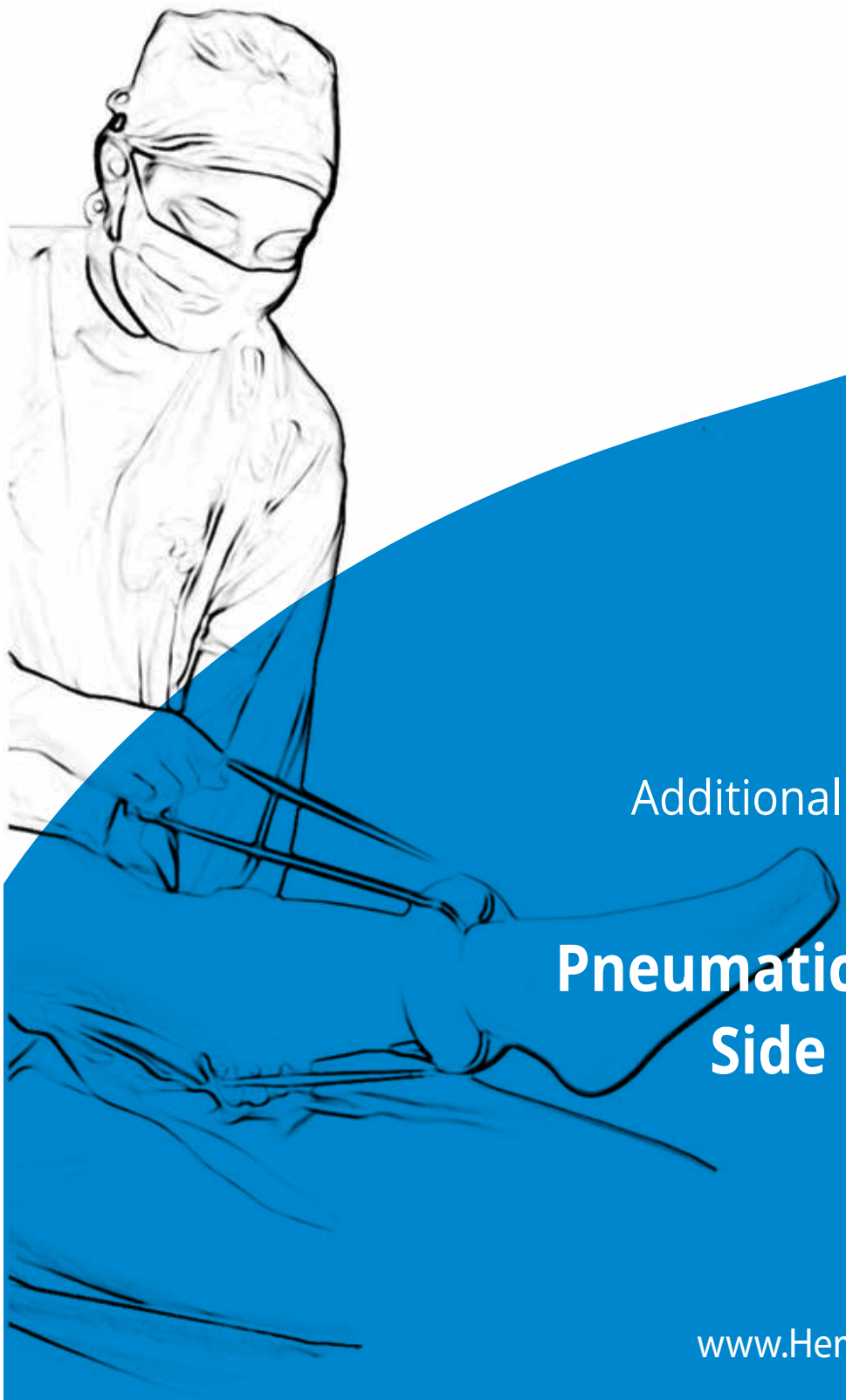

Additional Manuscripts

Pneumatic Tourniquet Side Effects

www.HemaClear.com

Table of Contents

Additional Manuscripts - Pneumatic Tourniquet Side Effects

1. Reusable tourniquets. An underestimated means for patient transfer of multi-resistant bacteria, T Gottlieb*, T Phan, EYL Cheong, G Sala, S Siarakas, A Pinto 3
2. Microbial Colonization of Tourniquets Used in Orthopedic Surgery 5
3. Tourniquet associated chemical burn, Jae-Hyuk Yang, Hyungtae Lim, Jung-Ro Yoon, and Hyeon-Il Jeong Lower 15
4. Lower Tourniquet Cuff Pressure Reduces Postoperative Wound Complications After Total Knee Arthroplasty, Charlotta Olivecrona, RN, Sari Ponzer, MD, PhD, Per Hamberg, MD, PhD, and Richard Blomfeldt, MD, PhD (A Randomized Controlled Study of 164 Patients) 23

White Paper
Anesthesiology

5. Pathophysiology and Prevention of HemaClear Tourniquet Failure, Prof. Noam Gavriely, MD, DSc. 29
6. Incomplete Leg Exsanguination: A Possible Cause of Post Total Knee Arthroplasty (TKA) Cognitive Deficit (CD), Noam Gavriely, MD, DSc. 33
7. Regional and Local Anesthesia of the Wrist and Hand Aided by a Forearm Sterile Elastic Exsanguination Tourniquet - A Review 43
8. Exsanguination of lower limbs in healthy male subjects ,Lars Blond1 Klaus Kirketerp-Møller, Stig Sonne-Holm, and Jan L. Madsen 51
9. Tourniquet Use Improves Cement Penetration and Reduces Radiolucent Line Progression at 5 Years After Total Knee Arthroplasty תVishal Hegde, MD, Daniel N. Bracey, MD, PhD, Roseann M. Johnson, BS, CCRP, Douglas A. Dennis, MD, Jason M. Jennings, MD, DPT 55
10. Use of HemaClear on the Lower Leg for Foot and Ankle Surgery, Prof. Noam Gavriely, MD 61
11. Anatomical changes in peripheral nerves compressed by a pneumatic tourniquet, J. Ochoa, T. J. Fowler, and R. W. Gilliatt 63

Additional manuscripts -Pneumatic Tourniquet Contamination and Side Effects

12. The Use of Non-Sterile Pneumatic Tourniquets in Limb, Noam Gavriely MD, DSc and Larry Murdock, RRT 107
13. Exsanguinating tourniquet assessed, The Clinical Services Journal 2006 115
14. Carpal Tunnel Syndrome: Background Information for HemaClear®Product Specialists, Edith R. Gavriely 119
15. Forearm Sterile Elastic Tourniquet – A Preferred Method For Carpal Tunnel Release (CTR), Prof. Noam Gavriely, MD 125
16. Tourniquet and the Obese Patient White Paper Prepared for OHK Medical Devices, Prof. Noam Gavriely, Scott Freer, Navit Suchard, Oren Gavriely 131
17. Moving to a new type of sterile and single-use tourniquet for orthopedic surgery, de Kiewiet GP 137
18. Understanding and Mitigating Tourniquet Risks, Noam Gavriely MD, DSc 141

19. Optimizing the bloodless surgical field in the limb surgery,
Noam Gavriely, md, dsc 159

Gottlieb *et al. BMC Proceedings* 2011, **5**(Suppl 6):P38
http://www.biomedcentral.com/1753-6561/5/S6/P38

BMC Proceedings

POSTER PRESENTATION Open Access

Reusable tourniquets. An underestimated means for patient transfer of multi-resistant bacteria

T Gottlieb*, T Phan, EYL Cheong, G Sala, S Siarakas, A Pinto

From International Conference on Prevention & Infection Control (ICPIC 2011)
Geneva, Switzerland. 29 June – 2 July 2011

Introduction / objectives

We sought to investigate the use of reusable tourniquets as potential sources of MRO transmission.

Methods

100 reusable tourniquets were collected over 10 weeks in a 503-bed Sydney teaching hospital. Tourniquets were incubated overnight in BHI enrichment broth and subcultured.

Results

The colonisation rate was 78% (78/100). Ten grew non multi-resistant Gram- positives - MSSA (1) and Enterococcus species (9), 17 grew commensals. Non multi-resistant Gram-negatives grew in 38 specimens: Pseudomonas species (13) and 'coliforms' (26). MROs were found on 25% of tourniquets, including 3 from MRO isolation rooms. An IMP-4 positive *E. cloacae* and an ESBL *E. cloacae* were isolated from a single tourniquet each. MRSA was isolated from 14; vanB *E. faecium* was isolated from 18 and vanA *E. faecalis* from a single tourniquet. MRSA and VRE were isolated together from nine tourniquets, and 24 tourniquets grew either one. Van B positive *E.faecium* were typed using DiversiLab rep-PCR system This revealed five clusters without adominant clone. Six of 9 tourniquets from ICU grew at least one MRO. MROs were isolated throughout the 10 week period from a wide variety of locations including general wards, ICU, Burns, theatre anaesthetic bay and the blood collection unit.

Conclusion

Reusable tourniquets are frequently colonised with MROs and may be a potential source of cross-transmission. Using broth enrichment, 24% harboured either MRSA or VRE. Astourniquets are carried from ward to ward by hospital staff and used repeatedly, they may become a 'sleeper' mechanism for unrecognised hospital MRO transmission. They are also a surrogate marker for environmental colonisation and deficiencies in hospital cleaning. Continued use of reusable tourniquets may not be justified in the current hospital setting.

Disclosure of interest

None declared.

Published: 29 June 2011

doi:10.1186/1753-6561-5-S6-P38
Cite this article as: Gottlieb *et al.*: Reusable tourniquets. An underestimated means for patient transfer of multi-resistant bacteria. *BMC Proceedings* 2011 **5**(Suppl 6):P38.

Submit your next manuscript to BioMed Central and take full advantage of:

- Convenient online submission
- Thorough peer review
- No space constraints or color figure charges
- Immediate publication on acceptance
- Inclusion in PubMed, CAS, Scopus and Google Scholar
- Research which is freely available for redistribution

Submit your manuscript at
www.biomedcentral.com/submit

BioMed Central

Microbiology and Infectious Diseases, Concord Hospital, Concord, Australia

BioMed Central

© 2011 Gottlieb et al; licensee BioMed Central Ltd. This is an open access article distributed under the terms of the Creative Commons Attribution License (http://creativecommons.org/licenses/by/2.0), which permits unrestricted use, distribution, and reproduction in any medium, provided the original work is properly cited.

Microbial Colonization of Tourniquets Used in Orthopedic Surgery

By Eric F. Walsh, MD; Debby Ben-David, MD; Mark Ritter, MD; Anthony P. Mechrefe, MD; Leonard A. Mermel, DO, ScM; Christopher W. DiGiovanni, MD
ORTHOPEDICS 2006; 29:709

August 2006

Abstract

This study analyzed tourniquets used for orthopedic surgery in our hospital to determine the frequency and type of microbial contamination. Group A tourniquets were from our main operating room, Group B tourniquets were from our ambulatory surgicenter, Group C tourniquets were unused, prepackaged, sterile tourniquets from our main operating room, and Group D tourniquets were sterilely packed tourniquets from our ambulatory surgicenter. Tourniquets from Groups A, B, C, and D had 100%, 40%, 0%, and 0% microbial growth, respectively. For Group A tourniquets, coagulase-negative staphylococci, *Bacillus*, and *Staphylococcus aureus* were present in 100%, 60%, and 20% of tourniquets, respectively. Twenty percent were contaminated either with *Streptococcus sanguis*, *Aerococcus viridans*, or *Cornyebacterium* species. Coagulase-negative staphylococci and *Bacillus* were present in 40% and 30% of Group B tourniquets, respectively. Tourniquet contamination may be a risk factor for the development of surgical site infection in orthopedic surgery.

Nonsterile tourniquets are routinely used in orthopedic surgery. Because there are no published recommendations specifically regarding sterility of tourniquets used in surgical cases, we aimed to define the microbial status of nonsterile tourniquets used in our operating rooms. This is particularly important given the fact that, currently, the same tourniquets routinely are used on patients with both clean and contaminated wounds, without standardized policies for tourniquet disinfection between cases.

Portable medical equipment such as stethoscopes, otoscopes, and blood pressure cuffs become contaminated during routine use, and may result in transmission of antimicrobial-resistant pathogens.[1-3] Reusable tourniquets also have been demonstrated to be contaminated with microbial pathogens.[3-6] To our knowledge, few hospitals require sterile tourniquet use for orthopedic surgery. We hypothesized that nonsterile tourniquets ready for use in orthopedic surgery may be contaminated with microbial skin flora since they are not routinely disinfected between cases.

Materials and Methods

We analyzed 30 tourniquets at our institution in July 2003. The tourniquets were of variable sizes, ranging from 42 to 62 inches in length. The tourniquets were manufactured by Zimmer (Warsaw, Ind), DePuy (Warsaw, Ind), and Smith and Nephew (Memphis, Tenn) (Figure 1). Groups A and B were nonsterile, repetitively used tourniquets from the main operating room and the ambulatory surgicenter operating room, respectively. Groups C and D tourniquets were re-packaged, sterilized tourniquets from the ambulatory surgicenter operating room and sterile, never used, and pre-packaged from the main operating room, respectively.

Figure 1: Modern tourniquet cuffs: reusable single bladder standard rectangular cuff (top left), reusable contour lower leg cuff (center), sterile disposable single bladder cuff (lower right), and reusable pediatric cuff (bottom center) (A). Pictures of various types and sizes of tourniquets used at our institution and the exact same kind of tourniquets tested for bacteria in our study (B).

Ten tourniquets from Group A were randomly selected for testing. They are used in major trauma and reconstructive procedures at our hospital, which is a Level 1 trauma center. These tourniquets are used repetitively and often sequentially in elective cases involving total joint replacement, arthroscopy, contaminated open fracture care, and irrigation and debridement of infected wounds.

All Group A and B tourniquets are located in a basket in each operating room. Surgeons choose an appropriate tourniquet length and place it on the operative limb of the patient (Figure 2). This is routinely done without gloves, prior to hand hygiene, and after anesthesia induction. The limb of a patient then is prepped to the level of the tourniquet, and draped with sterile sheets beyond the level of the tourniquet so it is not in the sterile

field. Occasionally, the surgeon may opt to not use or apply a nonsterile tourniquet at the beginning of the case. If the surgeon later required the use of a tourniquet for hemostasis in the operative field, a Group C or D tourniquet would be applied.

Figure 2: Proper placement of the tourniquets on the upper leg (A) and upper arm (B). Note the orientation of the tourniquets with the pneumatic hose connector pointing proximally. These are the areas most often handled by the surgeon and the areas tested in our study.

After each case, the limb is dressed, sterile sheets are removed, and the tourniquets subsequently removed and placed back in their respective bins for later use. Group A tourniquets from the main operating room routinely are not cleansed before reuse. The decision to send a tourniquet to central processing for cleaning is at the discretion of the scrub technician or circulating registered nurse in the operating room, as there is no written protocol for reuse, reprocessing, or decontamination of our nonsterile tourniquets. Once sent for disinfection, these tourniquets are washed by hand with Manu-Klenz instrument detergent (Sterris Corp, Mentor, Ohio).

Ten tourniquets in Group B from the ambulatory surgicenter operating room were randomly selected for testing. These are not cleaned between cases. They are discarded or changed only when they wear out or malfunction, also at the discretion of the operating room nursing staff. Group B tourniquets are used mainly for elective, clean surgery and are only rarely used for cases involving septic joints or open wounds. Five Group C tourniquets from the ambulatory surgicenter operating room were randomly selected for testing after being sterilized in central processing and repackaged for reuse. Five Group D tourniquets were similarly selected from the main operating room to be tested and represented unused, prepackaged tourniquets made available by the manufacturer.

Using aseptic technique, approximately 5 cm of each tourniquet from the four groups was cultured from four sites. Both sides of each tourniquet were pressed on blood agar plates and labeled as “internal proximal” and “internal distal.” These areas come in direct contact with patient skin during routine use. The external proximal and distal sides of each tourniquet also were cultured (Figures 3 and 4). A 5-cm area from each tourniquet

was pressed onto the trypticase-soy agar plates with 5% sheep blood. Plates were incubated at 37° C for 48 hours. Colonies were identified and antimicrobial susceptibilities determined using NCCLS (National College of Clinical Lab Sciences) criteria. All values from sampling each tourniquet were compared using Chi-square tests for categorical variables. Statistical analysis was performed using student *t* tests, and *P* values <.05 were considered significant. Odds ratios and 95% confidence intervals were determined using EpiInfo (Center for Disease Control and Prevention, Atlanta, Ga).

Figure 3: The area of the outer part of the tourniquet tested in our study. The yellow ring marks the proximal edge and the blue ring marks the distal edge.



Figure 4: The area of the inner part of the tourniquet tested in our study. The yellow ring marks the proximal edge and the blue ring marks the distal edge.

Finally, we also queried five other New England teaching hospitals regarding their policies for routine disinfection of orthopedic operative tourniquets between cases, and recorded our results.

Results

One hundred percent (10/10) and 40% (4/10) of tourniquets in Groups A and B, respectively, demonstrated microbial growth. No growth was noted for any of the tourniquets cultured in Groups C and D (the sterilized tourniquets). For Group A, 10 of 10 tourniquets were contaminated with coagulase-negative staphylococci, including 35 (88%) of 40 agar plates. Six of 10 tourniquets (10 of 40 agar plates) were contaminated with *Bacillus* species. Two of 10 tourniquets (4 of 40 agar plates) were contaminated with *Staphylococcus aureus* and 2 of 10 (3 of 40 agar plates) each were contaminated with one of the following: *Streptococcus sanguis*, *Aerococcus viridans*, or *Corynebacterium* species. For Group B tourniquets, 4 of 10 had contamination with coagulase-negative staphylococci, including 10 of 40 agar plates, and 3 of 10 tourniquets (5 of 40 agar plates) were contaminated with *Bacillus* species. Overall, 70% of all nonsterile (Group A and B) tourniquets were contaminated with coagulase-negative staphylococci, 45% were contaminated with *Bacillus* species, and 10% were contaminated with *S aureus*. None of the coagulase-negative staphylococci or *S aureus* were methicillin-resistant. Antimicrobial susceptibility patterns are listed in the Table.

Contamination of Group A tourniquets was found to be significantly greater than those in Group B (*P*=.018).

Table

Percentage of Cultures Positive for Microbial Organisms Found on Tourniquets

	No. (%)				
	Staphylococcus Coagulase Negative	*Bacillus*	*Staphylococcus Aureus*	Other	No Growth
Group A					
Plates	35/40 (87.5)	10/40 (25)	4/40 (10)*	3/40 (7.5)	2/40 (5)
Tourniquets	10/10 (100)	6/10 (60)	2/10 (20)	2/10 (20)	0/10 (0)
Group B					
Plates	10/40 (25)	5/40 (12.5)	0/40 (0)	0/40 (0)	25/40 (62.5)
Tourniquets	4/10 (40)	3/10 (30)	0/10 (0)	0/10 (0)	4/10 (40)
Group C (Main)					
Plates	0/40 (0)	0/40 (0)	0/40 (0)	0/40 (0)	40/40 (100)
Group D (ASC)					
Plates	0/40 (0)	0/40 (0)	0/40 (0)	0/40 (0)	40/40 (100)
Groups A & B					
Plates	45/80 (56.3)	15/80 (18.8)	4/80 (5)*	3/80 (3.8)	27/80 (33.8)
Tourniquets	14/20 (70)	9/20 (45)	2/40 (5)	2/20 (10)	4/20 (20)
Groups C & D)					
Tourniquets	0/80 (0)	0/80 (0)	0/80 (0)	0/80 (0)	0/80 (0)

**Represent positive cultures for* Staphylococcus aureus *that on subsequent testing were determined to not to be methicillin-resistant.*

After we reviewed our results with the department of infection control and the operating room staff, policies were written and approved for routine disinfection of tourniquets between cases. Of the five New England teaching hospitals we queried regarding their policies for routine disinfection of orthopedic operative tourniquets between cases, four lacked standardized policies for routine tourniquet disinfection, and one required sterile tourniquet use for orthopedic surgical procedures. We also identified significant variability in how each institution used their tourniquets. For instance, the hospital that uses only sterile tourniquets opens and places them on the nonsterile extremity while another sends the nonsterile tourniquets after each case to be “cleaned” and packaged but not sterilized.

Discussion

As perioperative infection control becomes an increasingly scrutinized issue because of increasing antimicrobial resistance and the associated adverse outcomes, minimizing surgical field contamination is paramount.[7] This changing pattern of bacterial flora is supported by the observations of our own orthopedic department and has prompted us to find new ways of decreasing exposure and risk to surgical infection.

Operative tourniquets used by orthopedic surgeons often are nonsterile. Cultures of tourniquets at our institution demonstrated 80% of nonsterile, ready-for-use tourniquets were colonized with bacteria. The results of our data prompted our hospital to institute a

new policy for routine disinfection prior to reuse of any surgical tourniquet. Types of tourniquet care and cleaning protocols are presented in the Sidebar.[8]

Methicillin-susceptible coagulase-negative staphylococci were the predominant microbes contaminating tourniquets. While the majority of contaminants isolated are considered normal skin flora, many of these are prevalent offenders in orthopedic surgical site infections, particularly infections involving prosthetic joints and other hardware. Recent studies have reported an increasing incidence of orthopedic surgical site infections caused by coagulase-negative staphylococci that have led to delayed diagnosis and increased morbidity.[9]

If tourniquet application or use plays a role in potential contamination of the surgical field, certainly this would lend greater concern towards proper tourniquet disinfection when considering the implications on patient outcome and treatment. Results from our data have resulted in the institution of a new policy for tourniquet handling that we consider to be an important step in potential prevention of any tourniquet contamination of the surgical field. It remains unclear, however, if such contamination is a risk factor for orthopedic surgical site infections since these tourniquets are handled by the orthopedic surgeons prior to hand hygiene and they are not in the sterile field. Nevertheless, a solution to this unproven but potential problem, is of low cost and easy to implement. We recommend that hospitals institute a policy of either tourniquet sterilization between cases or the use of only prepackaged sterile tourniquets in the operating room. Beyond the concerns raised by our data, the need for such a recommendation also is supported by the fact that only one of the five other New England institutions we investigated had any protocol in place for disinfection of potentially contaminated tourniquets prior to reuse.

More About Tourniquet Cuffs

Disposable Versus Reusable Cuffs

- Sterile, disposable cuffs are available for situations that require placement of a sterile tourniquet near the operative site, or for use in contaminated surgical cases.
- The design and materials of disposable cuffs are suitable for a single sterilization cycle and must not be resterilized or reused.
- Disposable cuffs must be discarded at the end of the procedure.
- Reusable cuffs are not designed to be sterilized and must be used with sufficient sterile draping to isolate the cuff from the sterile field.

Care and Handling of Pneumatic Tourniquet Cuffs

- Various types of microorganisms are commonly found on contact closure–covered tourniquets and on Penrose drains. The tourniquet cuff, which is placed near the patient's axilla or groin, may be a

source of pathogenic microorganisms. After each use, it is important to decontaminate the tourniquet components, by following the manufacturer's recommended cleaning procedures. The following cleaning procedure is presented as an example only:

If the tourniquet cuff is adequately protected during surgery, hand washing of the cuff and bladder in lukewarm water is the only decontamination procedure indicated. If the bladder and plastic liner are removable, wash them as separate items. Do not immerse the bladder unless the connectors are sealed; if fluid enters the bladder, mildew may form, or subsequent deflation of a wet bladder during use may cause minute droplets of water to be forced back into the tourniquet regulating mechanism. Prevent rapid deterioration, shrinkage, and fading of the cuff fabric by avoiding hot water, harsh detergents, or bleaches.

- If blood or other body fluid comes in contact with these items, add an enzymatic detergent to the wash water to remove blood components from the fabric and rubber.
- If necessary, use a hand brush to remove encrusted material.
- If loose fibers are present in the contact closure straps, it may be possible to remove them using a nonmetallic brush or a comb in a side-to-side manner.
- Rinse the cuff and bladder thoroughly; detergent residue increases the chances for allergic reactions and may decrease the life of the cuff.
- Carefully follow manufacturer's instructions for drying. As a rule, air-dry the cuff and bladder flat, at room temperature, in their original shapes. Drip drying over a rack may stretch the cuff over time.
- Clean the exterior of the cuff hoses using a mild detergent solution, or a disinfectant that is not deleterious to rubber or polyethylene.
- After each use, decontaminate the exterior of the tourniquet instrument by wiping it with a cloth that has been dampened (not dripping) with a mild detergent.
- Avoid storing the cuff tightly rolled up to a small diameter as this may cause permanent kinking and ridging of the stiffened inner structure of the cuff. If possible, store the cuff rolled loosely to approximately its normal in-use diameter.

Conclusion

Standard, nonsterile tourniquets used in orthopedic surgery are contaminated with *Staphylococcus*, *Bacillus*, and occasionally other bacteria. Greater contamination of tourniquets from our main operating room may be due to tourniquet use in the

contaminated trauma and infected wound or joint cases that are more commonly performed. Tourniquet contamination may be a risk factor for the development of surgical site infection in orthopedic surgery.

What is already known on this topic

- Studies have analyzed the flora on other types of tourniquets routinely used in medicine (ie, phlebotomy); however, no studies exist regarding surgical tourniquets.

What this article adds

- Microbial colonization status can be found on tourniquets routinely used in repeated surgeries. Tourniquets should be routinely checked for possible dirt and contamination.
- We continue to identify possible sources of microbial contamination in orthopedic surgical cases to improve the outcomes of our patients undergoing surgery.

References

1. Husdon H. Stethoscopes and infection control: a study into the use of stethoscopes in a pediatric ward and their possible contamination. *J Child Health Care.* 2003; 2:142-143.
2. Kennedy KJ, Dreimanis DE, Beckingham WD, Bowden FJ. *Staphylococcus aureus* and stethoscopes. *Med J Aust.* 2003; 178:468.
3. Bowen T. Nondisposable sphygmomanometer cuffs harbor frequent bacterial colonization and significant contamination by organic and inorganic matter. *AANA J.* 1997; 65:28.
4. Golder M, Chan CLH, O'Shea S, Corbett K, Chrystie IL, French G. Potential risk of cross-infection during peripheral-venous access by contamination of tourniquets. *Lancet.* 2000; 355:44.
5. Berman DS, Schaefler S, Simberkoff MS, Rahal JJ. Tourniquets and nosocomial methicillin-resistant Staphylococcus aureus infections. *N Engl J Med.* 1986; 315:514-515.
6. Rourke C, Bates C, Read RC. Poor hospital infection control practice in venepuncture and use of tourniquets. *J Hosp Infect.* 2001; 49:59-61.
7. DiGiovanni CW, Saleh KJ, Salvati EA, Pellicci PM, Masri BA. Deep infection complicating total hip arthroplasty. In: Pellicci PM, Tria AJ, Garvin KL, eds. *Orthopaedic Knowledge Update, Hip and Knee Reconstruction 2.* Rosemont, Ill: American Academy of Orthopedic Surgeons; 2000:137-148.
8. Association of Operating Room Nurses. Recommended practices for use of the pneumatic tourniquet. *AORN J.* 2002; 75:379-382,384-386.
9. Babcock HM, Matava MJ, Fraser V. Postarthroscopy surgical site infections: review of the literature. *Clin Infect Dis.* 2002; 34:65-71.

Authors

Drs Walsh, Ritter, and Mechrefe are from the Department of Orthopedic Surgery and Dr Mermel is from the Department of Infection Control, Rhode Island Hospital; Dr Ben-David is from the Division of Infectious Diseases and Dr DiGiovanni is from the Department of Orthopedic Surgery, Brown Medical School, Providence, RI.

The authors thank Adele Angelone, MLT, ASCPML, BS for assistance in identification of bacteria from tourniquets and for determining their antimicrobial susceptibilities.

Reprint requests: Christopher DiGiovanni, MD, Dept of Orthopedic Surgery, Brown Medical School, 1287 N Main St, Providence, RI 02904.

IJO Indian Journal of Orthopaedics

Home
Current issue
Instructions
Submit article

Indian J Orthop. 2012 May-Jun; 46(3): 356–359. PMCID: PMC3377150
doi: 10.4103/0019-5413.96366

Tourniquet associated chemical burn

Jae-Hyuk Yang, Hyungtae Lim, Jung-Ro Yoon, and Hyeon-Il Jeong[1]

Department of Orthopedic Surgery, Seoul Veterans Hospital, Korea
[1]Korea Orthopedic Clinic, Seoul, Korea
Address for correspondence: Dr. Jung-Ro Yoon, Department of Orthopedic Surgery, Seoul Veterans Hospital, 6-2 Dunchon Dong, Kangdong Ku, Seoul, Korea. E-mail: zenyjr@yahoo.co.kr

Copyright : © Indian Journal of Orthopaedics

This is an open-access article distributed under the terms of the Creative Commons Attribution-Noncommercial-Share Alike 3.0 Unported, which permits unrestricted use, distribution, and reproduction in any medium, provided the original work is properly cited.

Abstract

Chemical burn under pneumatic tourniquet is an iatrogenic preventable injury and is rarely reported in the literature. The two important mechanisms are maceration (friction) and wetness underneath the tourniquent. In this report, our experience with two illustrative patients who presented with iatrogenic tourniquet associated burn is described.

Keywords: Chemical burn, irritation, maceration, tourniquet

INTRODUCTION

Pneumatic tourniquets have been commonly utilized during orthopedic extremity surgeries to attain a bloodless field facilitating operative procedures. Although tourniquet associated complications including postoperative swelling, delay of recovery of muscle power, compression neuropraxia, wound hematoma with the potential for infection, vascular injury, tissue necrosis, compartment syndrome, and systemic complications have been reported in the literature, the iatrogenic chemical burn during pneumatic tourniquet use has been rarely reported.[1–4] Here, we report two cases of chemical burn to sensitize the orthopaedic surgeons about its possible occurrence.

CASE REPORTS

Case 1

A 24 year old male underwent lateral meniscus allograft transplantation on his left knee. The patient did not have thin skin and any underlying skin disease and allergies. The patient's operation was performed under tourniquet control. The tourniquet cuff used was a standard leg tourniquet (18 cm) and was applied with four layers of adequate wool padding. The skin preparation used was a 10% povidone-iodine (betadine) solution. The set pressure was 250 mmHg which was about 100 mmHg higher than the patient's systolic pressure. The tourniquet compression time was 2 h (total operation time=3 h). When the tourniquet was removed after operation, the burn was seen on the medial aspect of thigh [Figure 1a]. While inspecting the padding where the burn was present, the drape preparation seemed to have run down the patient's thigh during painting and had been left in wet condition underneath the tourniquet. The wound was of intermediate to deep second degree burn with blisters of size about 5 × 6 cm. The patient was treated conservatively with a furazone gauze occlusive dressing

and was discharged from orthopedic department without skin grafting. However, he underwent multiple treatments with the dermatologist for complete healing which took almost 12 months [Figure 1b]. Even to this time (2 years postoperation), the patient continuously complains of hypersensitivity on the scar area, which aggravates during normal gait.

Case 2

A 65 year old female patient, underwent elective unicompartmental knee arthroplasty for medial compartment osteoarthritis of the knee. The patient was free of chronic underlying diseases and had moderate skin thickness. The tourniquet cuff used was a standard leg tourniquet and was applied with four layers of adequate wool padding. The skin preparation used was a 10% povidone-iodine (betadine) solution. The set pressure was 250 mmHg which was about 100 mmHg higher than the patient's systolic pressure. The tourniquet compression time was 1.5 h (total operation time=2 h). When the tourniquet was removed, the burn was seen on the medial aspect of thigh. The burn was also of intermediate to deep second degree with dermis involvement. Betadine soaked padding was also observed at the site of burn. One week postoperatively, blisters and crusts were found roughly at the proximal margin of tourniquet [Figure 2a]. Local furazone gauze was applied for dressing and complete healing needed almost 1 year after operation. During this followup period, analgesics were continuously prescribed for the irritating, hypersensitive scar. Scar revision excising this hypersensitive, hypertrophic scar was needed after 1 year 4 months postoperatively [Figure 2b].

DISCUSSION

The chemical burn resulting from tourniquet application cause more in-depth injury to the skin than the abrasion wound because there is greater time exposure and the anesthesia prevents the patient from reacting to the noxious burn stimulus.[5] Consequently, multiple debridement, skin graft, and even flap surgeries may be needed in such injuries with prolonged treatment period. Both of our cases had intermediate to deep second degree burn extending into deep dermis. Not only a long duration of healing time (up to 1 year postoperatively) was needed, but also hypersensitive and painful scar remained thereafter. The iatrogenic chemical burn induced by tourniquet application can have an impact on surgeon patient relationship.

Tourniquet associated chemical burns have been reported previously also. Dickinson and Bailey[1] reported four burns beneath the cuffs of pneumatic tourniquets. In all cases, the burns were seen when the tourniquet was removed. In two cases, the area of iodine staining corresponded exactly with the area of the burn, while in the other two cases the burns were smaller. All burns were of partial thickness and healed within 4 weeks, leaving minimal scarring. Nahlieli *et al.*[2] reported three adult cases. One of these patients had a partial thickness burn under the tourniquet cuff, after a 2-h surgery on his right palm. Similar experiences were reported by other authors.[3,6] The scars described in these reports seem to have healed without much complications. Unlike the previous reported cases, our cases required prolonged healing time and patients continuously complained discomfort in the scar area. The basic mechanism of tourniquet induced chemical burn involves irritation by antiseptics[2,4,7,8] coupled with maceration,[9–11] compression pressure,[12–14] duration of compression,[13,14] and wetness underneath the tourniquet.[15,16] Polyvinylpyrrolidone-iodine (PI) is a widely used antiseptic which was introduced by Shelanski and Shelanski in 1965.[17] It is a water-soluble compound that results from the combination of molecular iodine and polyvinylpyrrolidone. The preparations of commercially available PI are povidone-iodine (betadine) solution, scrub, ointment, tincture, and foam; of these, the solution is the most commonly used. The 10% PI solution generally contains 90% water, 8.5% polyvinylpyrrolidone, and 1% available iodine and iodide (pH 4.5–5.5). Although uncommon, chemical burns have been reported with this solution.[2,5,18–21] Alcohol (70%), which is used for draping, may also cause hypersensitivity.[2,4,7] By using alcohol, the epidermal

lipid barrier acting to the skin may be decreased by de-esterification.

To prevent tourniquet associated chemical burn, two important points should be noted. First, friction between the skin and the tourniquet should be avoided because macerated skin becomes more permeable to PI which may become prone for damage. Movement of tourniquet during draping and compression should also be prevented. An elastic stockinette is known to be effective in preventing the development of maceration induced blisters.[22] The shape mismatch between the tourniquet and the thigh should be considered when applying tourniquet to minimize friction. Very muscular or obese patients tend to have conical shaped thigh.[14] Even distribution moving the skin and the soft tissues distally underneath the tourniquet may overcome this mismatch. Second, emphasis should be made on some form of barrier occluding the tourniquet, preventing wool soaking from antiseptics.[15,16] In addition to a number of commercial covers, a variety of simple, non commercial alternatives have been proposed. Sarkhel and Stride[15] suggested using the disposable reservoir bag from a single use anesthetic circuit, while the use of surgical glove was proposed by Tomlinson and Harries.[16] Our department has been using adhesive plaster (Sinsin Pharm Co. Ltd., Korea) and antimicrobial incise drape (Ioban™ 2®, 3M Health care, USA) for mechanical barrier [Figure 3a and b]. On taking these precautions, further occurrence of tourniquet associated chemical burns was prevented.

The chemical burn due to pneumatic tourniquet is a relatively under-reported problem which may be more frequent than believed. The PI related chemical burn in tourniquet use may be prevented by understanding the mechanism of occurrence of this complication to prevent this devastating iatrogenic injury.

Footnotes

Source of Support: Nil

Conflict of Interest: None.

REFERENCES

1. Dickinson JC, Bailey BN. Chemical burns beneath tourniquets. Br Med J. 1988;297:1513. [PMCID: PMC1835189] [PubMed: 3147050]

2. Nahlieli O, Baruchin AM, Levi D, Shapira Y, Yoffe B. Povidone-iodine related burns. Burns. 2001;27:185–8. [PubMed: 11226660]

3. Handley R. Chemical burns beneath tourniquets. Br Med J. 1989;298:254.

4. Chiang YC, Lin TS, Yeh MC. Povidone-iodine-related burn under the tourniquet of a child - a case report and literature review. J Plast Reconstr Aesthet Surg. 2011;64:412–5. [PubMed: 20558121]

5. Hodgkinson DJ, Irons GB, Williams TJ. Chemical burns and skin preparation solutions. Surg Gynecol Obstet. 1978;147:534–6. [PubMed: 705572]

6. Madhok R. Chemical burns beneath tourniquets. Br Med J. 1989;298:254.

7. Lowe DO, Knowles SR, Weber EA, Railton CJ, Shear NH. Povidone-iodine-induced burn: Case report and review of the literature. Pharmacotherapy. 2006;26:1641–5. [PubMed: 17064209]

8. Okano M. Irritant contact dermatitis caused by povidone-iodine. J Am Acad Dermatol. 1989;20:860. [PubMed: 2715439]

9. Bruner JM. Safety factors in the use of the pneumatic tourniquet for hemostasis in surgery of the hand. J Bone Joint Surg Am. 1951;33:221–4. [PubMed: 14803491]

10. Kutty S, McElwain JP. Padding under tourniquets in tourniquet controlled surgery: Bruner's ten

rules revisited. Injury. 2002;33:75. [PubMed: 11879838]

11. McEwen JA, Kelly DL, Jardanowski T, Inkpen K. Tourniquet safety in lower leg applications. Orthop Nurs. 2002;21:55–62. [PubMed: 12432700]

12. Delgado-Martinez AD. Pneumatic tourniquets in extremity surgery. J Am Acad Orthop Surg. 2002;10:232. [PubMed: 12041945]

13. Noordin S, McEwen JA, Kragh JF, Jr, Eisen A, Masri BA. Surgical tourniquets in orthopaedics. J Bone Joint Surg Am. 2009;91:2958–67. [PubMed: 19952261]

14. Wakai A, Winter DC, Street JT, Redmond PH. Pneumatic tourniquets in extremity surgery. J Am Acad Orthop Surg. 2001;9:345–51. [PubMed: 11575914]

15. Sarkhel T, Stride V. The Tourniqu Aid: Prevention of chemical burns. Injury. 2002;33:73–4. [PubMed: 11879837]

16. Tomlinson PJ, Harries WJ. The use of a surgical glove in the prevention of tourniquet-associated chemical burns. Ann R Coll Surg Engl. 2008;90:255. [PMCID: PMC2430456] [PubMed: 18434994]

17. Shelanski HA, Shelanski MV. PVP-iodine: History, toxicity and therapeutic uses. J Int Coll Surg. 1956;25:727–34. [PubMed: 13332267]

18. Bayne D. Prevention of chemical burns. Ann R Coll Surg Engl. 2008;90:715. [PMCID: PMC2727846] [PubMed: 18990295]

19. Hubik DJ, Connors A, Cleland H. Iatrogenic chemical burns associated with tourniquet use and prep solution. ANZ J Surg. 2009;79:762. [PubMed: 19878182]

20. Liu FC, Liou JT, Hui YL, Hsu JC, Yang CY, Yu HP, et al. Chemical burn caused by povidone-iodine alcohol solution – a case report. Acta Anaesthesiol Sin. 2003;41:93–6. [PubMed: 12934425]

21. Nakano S, Uchiyama A, Ueyama H, Nishimura M, Tashiro C, Azuma T. Chemical burn caused by povidone-iodine. Masui. 1991;40:812–5. [PubMed: 2072525]

22. Saleh KJ. An elastic stockinette under a pneumatic tourniquet protected against the development of blisters during total knee arthroplasty. J Bone Joint Surg Am. 2007;89:459. [PubMed: 17272479]

Figures and Tables

Figure 1

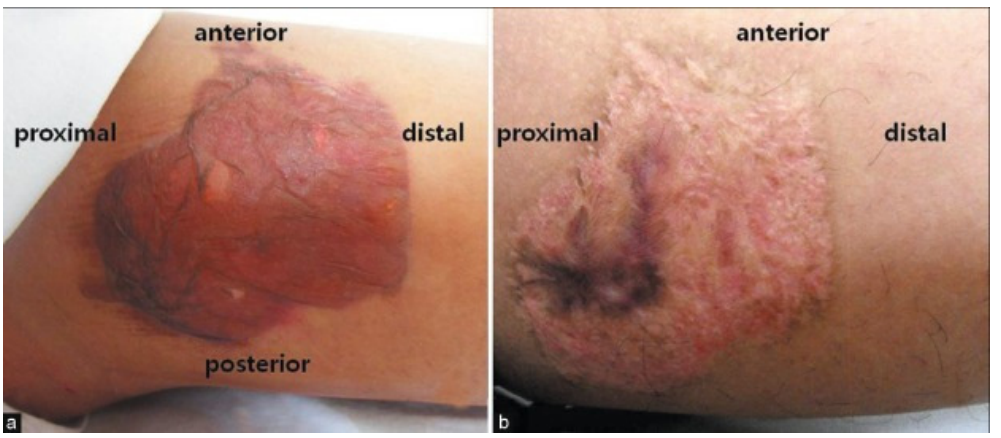

Case 1. Tourniquet-associated chemical burn developed on medial aspect of thigh: (a) immediate postoperative; (b) 1year and 9 months postoperative

Figure 2

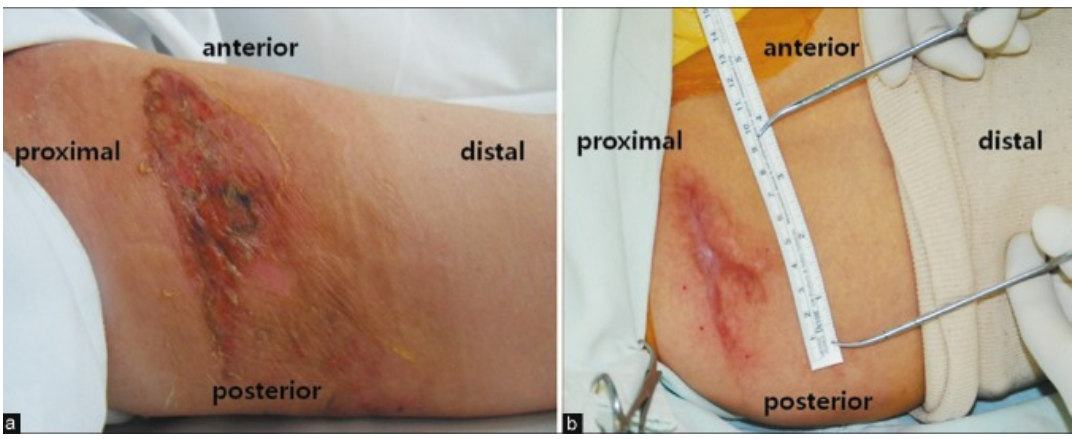

Case 2. Tourniquet-associated chemical burn developed on medial aspect of thigh: (a) 1 week postoperative; (b) 1 year and 4 months postoperative (just prior to scar excision)

Figure 3

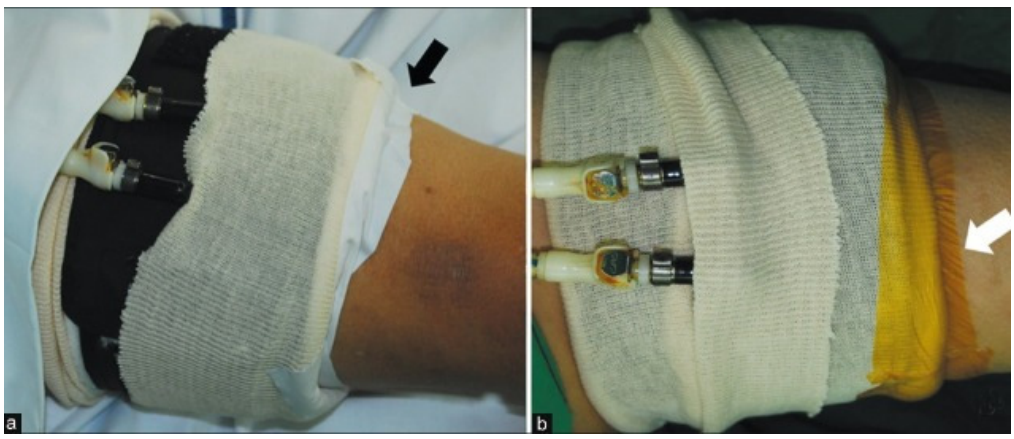

Suggested method for tourniquet application with elastic stockinette and wool padding. Note the adhesive plaster (black arrow) (a) and antimicrobial incise drape (white arrow) (b) used for mechanical barrier

Articles from Indian Journal of Orthopaedics are provided here courtesy of **Medknow Publications**

Copyright © 2012 by The Journal of Bone and Joint Surgery, Incorporated

Lower Tourniquet Cuff Pressure Reduces Postoperative Wound Complications After Total Knee Arthroplasty

A Randomized Controlled Study of 164 Patients

Charlotta Olivecrona, RN, Sari Ponzer, MD, PhD, Per Hamberg, MD, PhD, and Richard Blomfeldt, MD, PhD

Investigation performed at the Department of Orthopaedics, Södersjukhuset Karolinska Institutet, Stockholm, Sweden

Background: Measurement of limb occlusion pressure before surgery might lead to the use of a lower tourniquet cuff pressure during surgery and thereby reduce the risk of postoperative pain and complications. The primary aim of this study was to investigate whether the limb-occlusion-pressure method reduces the tourniquet cuff pressure used during total knee arthroplasty and if this leads to less postoperative pain compared with that experienced by patients on whom this method is not used. The secondary aim was to investigate whether there were any differences regarding the quality of the bloodless field, range of motion, and postoperative wound complications.

Methods: One hundred and sixty-four patients scheduled to be treated with a total knee arthroplasty were randomized to a control group or to undergo the intervention under study (the limb-occlusion-pressure [LOP] group). In the control group, the tourniquet cuff pressure was based on the patient's systolic blood pressure and a margin decided by the surgeon (the routine method). In the LOP group, the tourniquet cuff pressure was based on the measurement of the limb occlusion pressure. The primary outcome measure was postoperative pain, and the secondary outcome measures were the quality of the bloodless field, knee motion, and wound-related complications at discharge and two months after surgery.

Results: The tourniquet cuff pressure was significantly lower in the LOP group than in the control group ($p < 0.001$). We could not demonstrate any differences between the groups regarding postoperative pain or complications, although the number of postoperative complications was relatively high in both groups. However, at discharge forty of the forty-seven patients with a wound complication had had a cuff pressure above 225 mm Hg and at the two-month follow-up evaluation fourteen of the sixteen patients with a wound complication had had a cuff pressure above 225 mm Hg.

Conclusions: The limb-occlusion-pressure method reduces the cuff pressure without reducing the quality of the bloodless field, but there were no differences in outcomes between the groups. An important secondary finding was that patients with a cuff pressure of ≤225 mm Hg had no postoperative infections and a lower rate of wound complications.

Level of Evidence: Therapeutic Level I. See Instructions for Authors for a complete description of levels of evidence.

The use of a pneumatic tourniquet during a total knee arthroplasty improves visualization by preventing intraoperative bleeding. However, some studies have demonstrated lower rates of postoperative complications and better initial recovery of knee movement when the knee arthroplasty was performed without use of a pneumatic tourniquet[1-3]. When a tourniquet is used, the cuff pressure should be minimized to reduce the risk of tourniquet-related postoperative complications[2,4]. Setting the thigh tourniquet cuff pressure on the basis of the systolic blood pressure plus a margin of 100 mm Hg has been reported to reduce the cuff pressure and early postoperative pain[5]. According to another study, limb occlusion pressure and systolic blood pressure were not correlated well enough for the systolic blood pressure alone to be used to determine the optimal cuff

Disclosure: None of the authors received payments or services, either directly or indirectly (i.e., via his or her institution), from a third party in support of any aspect of this work. None of the authors, or their institution(s), have had any financial relationship, in the thirty-six months prior to submission of this work, with any entity in the biomedical arena that could be perceived to influence or have the potential to influence what is written in this work. Also, no author has had any other relationships, or has engaged in any other activities, that could be perceived to influence or have the potential to influence what is written in this work. The complete **Disclosures of Potential Conflicts of Interest** submitted by authors are always provided with the online version of the article.

pressure[6]. Wide conical cuffs require a lower cuff pressure[7,8] and are less painful[7], although the authors of most published studies did not report whether a straight or a wider conical cuff had been used.

Measuring the limb occlusion pressure just before surgery by means of an automated photoplethysmographic sensor connected to a tourniquet apparatus takes into account such variables as the type and width of the cuff, the tightness of cuff application, the fit of the cuff to the limb, and the properties of the patient's soft tissues and vessels[6] and therefore has been suggested to result in a more optimal cuff pressure. However, automated measurement of limb occlusion pressure has been investigated in only a few clinical studies[6,9,10].

The primary aim of this study was to investigate whether the limb-occlusion-pressure method reduces the tourniquet cuff pressure used during surgery and if this leads to less postoperative pain. The secondary aim was to investigate whether there were any differences between the group treated with this method and a control group regarding the quality of the bloodless field, range of knee motion, and postoperative wound complications. We hypothesized that there would be no differences between the limb-occlusion-pressure measurement method and the control method.

Materials and Methods

This prospective randomized controlled clinical trial was performed from October 2008 to July 2010. Patients scheduled to be treated with a primary total knee arthroplasty, who were seventy-five years of age or younger, and who were classified as American Society of Anesthesiologists (ASA) 1, 2, or 3 were considered eligible for inclusion[11,12]. Patients who were unable to read and understand Swedish, had a systolic blood pressure of >200 mm Hg, or had a thigh girth of >78 cm were excluded.

All patients gave their informed consent to participate and were randomized preoperatively to a control or intervention (limb-occlusion-pressure [LOP]) group with use of opaque sealed envelopes.

The study was conducted according to the principles of the Helsinki Declaration and was approved by the Ethics Committee of Karolinska Institutet (Ref. No. 2007/757-31/1-4), Stockholm. It was registered at ClinicalTrials.gov (NCT01442298).

The standard method at our department was used for the patients in the control group. The tourniquet cuff pressure was based on the patient's systolic blood pressure and a margin that was decided by the surgeon. In the LOP group, the tourniquet cuff pressure was decided by measuring the limb occlusion pressure with use of an automated photoplethysmographic sensor connected to an ATS 3000 tourniquet apparatus (Zimmer Sweden, Sävedalen, Sweden). The recommended tourniquet pressure was defined as the limb occlusion pressure plus a safety margin of 50 mm Hg for those with a limb occlusion pressure of ≤130 mm Hg, 75 mm Hg for those with a pressure between 131 and 190 mm Hg, and 100 mm Hg for those with a pressure of >190 mm Hg. These recommended margins were higher than those reported earlier[4,6], but were the preadjustable margins indicated by the manufacturer (Zimmer Sweden).

The limb underneath the tourniquet cuff was protected by a two-layer elastic stockinette[13]. The operating room nurse applied a standard 140-mm-wide contour thigh cuff for all but seven patients (three in the control group and four in the LOP group), for whom the operating room nurse selected a 100-mm-wide cylindrical cuff because of difficulties in positioning the contour cuff due to a short lower limb or a very straight thigh.

The operating room nurse chose the tourniquet cuff and measured the limb occlusion pressure. Before starting the surgery, the surgeon determined the tourniquet cuff pressure according to the standard method. The operating room personnel applied this pressure if the patient had been randomized to the control group. If the patient had been randomized to the LOP group, they applied the pressure suggested by the limb-occlusion-pressure method. The surgeon was blinded to the randomization and was not told which tourniquet pressure was applied.The surgery was performed according to the routine at our department.

The surgeon used a midline skin incision with a medial parapatellar capsular incision of the joint, and all patients received a cemented NexGen Cruciate Retaining total knee arthroplasty (Zimmer Sweden).

All patients received perioperative antibiotics (cloxacillin, 2 g × 3) and low-molecular-weight heparin (dalteparin). All patients also received a local infiltration analgesic (300 mg of ropivacaine/0.5 mg of epinephrine/30 mg of ketorolac) at the end of the surgery by infiltration into the fascia, muscles, and subcutaneous tissue, regardless of whether they had had spinal or general anesthesia. In 147 patients, a catheter was also inserted into the knee joint for pain treatment with a local anesthetic (150 mg of ropivacain/30 mg of ketorolac). It was used during the day after the surgery and was then withdrawn[14].

After the surgery was completed, the surgeon was asked to rate the quality of the bloodless field on a visual analog scale (VAS), with 1 indicating the worst possible rating and 10, the most optimal. The surgeon was also asked to rate whether any technical difficulties had been encountered due to the quality of the bloodless field (1 indicating no difficulties and 10, extreme difficulties).

The skin underneath the tourniquet was inspected immediately after the surgery and on day four, when a ward nurse also performed a wound check. The functional assessment was done on the third postoperative day by an independent physiotherapist and included measurement of knee motion (with the patient lying down and sitting up) and a straight-leg lifting test (with a 1-kg weight). Furthermore, the patients filled out the modified Western Ontario and McMaster Universities Osteoarthritis Index (WOMAC) questionnaire daily during their hospital stay. The WOMAC is a self-administered, well-validated health status instrument with three domains: pain, physical function, and stiffness[15,16].

All patients were followed at two months postoperatively (with inspection of the wound, measurement of knee motion, and completion of the WOMAC questionnaire). The medical records were scanned for complications such as nerve injury and deep venous thrombosis. The orthopaedic surgeon in charge and all staff at the department, except the operating room personnel who measured the limb occlusion pressure, were blinded to the allocation group during the hospital stay and at the follow-up evaluations.

Power Analysis

The sample size was calculated to detect a difference of 5 points (standard deviation [SD], 10 points) in the WOMAC pain score between the control and LOP groups on day four. A total of sixty-four patients in each group (128 patients in the series) were required to detect this difference with an 80% power at the 5% significance level, two-tailed. As we anticipated a drop-out rate of about 25%, the recruitment goal was determined to be 164 patients. When we were planning for this study, we knew of no earlier randomized study with cuff pressure as the outcome, so our sample size was calculated for detecting differences in postoperative pain.

Statistical Methods

Categorical variables were presented as absolute and relative frequencies and tested for differences between randomization groups with the chi-square test. Continuous variables were presented throughout as the mean and SD and tested with the Mann-Whitney U test. The nonparametric test was used because it was deemed more appropriate for the subjective scale variables, and for the remaining continuous variables the assumption of normality was not satisfied. Cuff pressure was partly analyzed as a continuous variable and partly as a categorical variable, whereby the cutoffs of 225 and 260 mm Hg were chosen on the basis of their clinical relevance. The results were regarded as significant if p was < 0.05 (two-tailed).

All analyses were performed according to the intention-to-treat principle.

Source of Funding

The authors did not receive any external funding or grants in support of their research for this work.

Results

Three patients were excluded after inclusion: one because of a change to a unicompartmental knee arthroplasty, one because of a change to a high-flex prosthesis, and one who was scheduled

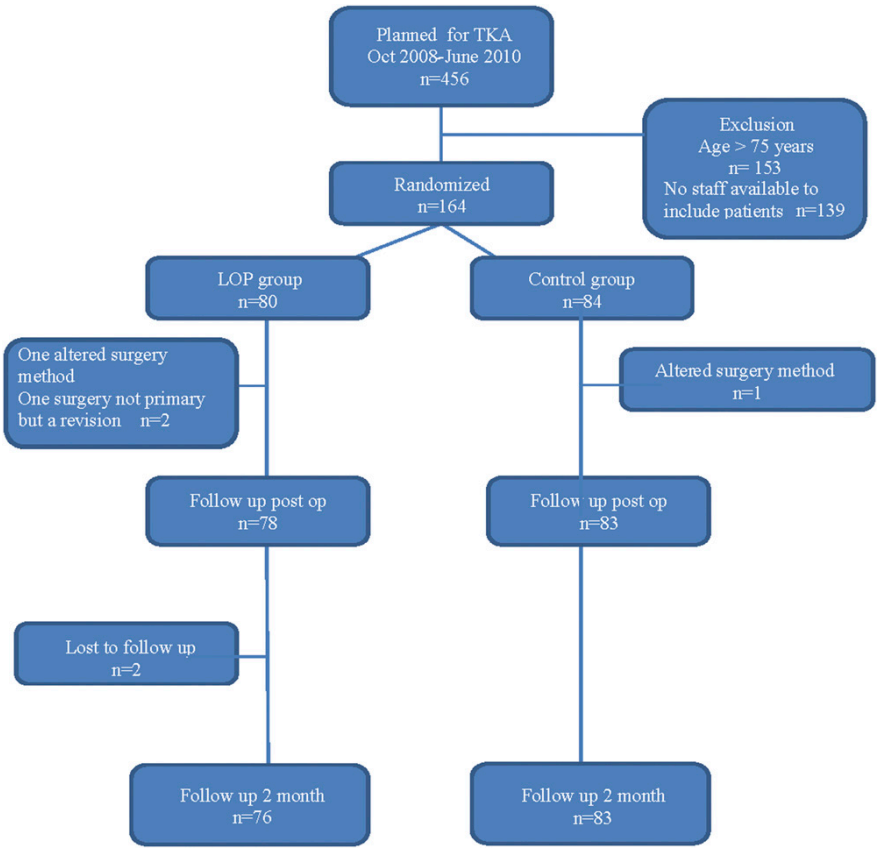

Fig. 1
CONSORT (Consolidated Standards of Reporting Trials) diagram. TKA = total knee arthroplasty.

for revision surgery and thus had been incorrectly included in the study. In total, 161 patients—eighty-three in the control group and seventy-eight in the LOP group—were included in the analysis. Two patients were lost to follow-up at two months (Fig. 1).

There were no differences between the LOP group and the control group regarding sex, age, ASA class, body mass index (BMI), preoperative systolic blood pressure, or the bloodless-field time during surgery (see Appendix). Systolic blood pressure, measured on the arm routinely at the start of surgery, was a mean (and SD) of 122 ± 20 mm Hg in the LOP group compared with 119 ± 19 mm Hg in the control group (difference not significant). The mean limb occlusion pressure (measured on the thigh in the LOP group) was 169 ± 34 mm Hg.

As shown in Table I, a tourniquet cuff pressure of ≤225 mm Hg was found more often in the LOP group than in the control group ($p < 0.001$). The mean tourniquet cuff pressure was also generally lower in the patients in the LOP group, but this difference was not significant ($p = 0.362$). No significant difference between the groups could be detected regarding the quality of the bloodless field or the technical difficulties as judged by the surgeon (Table I). There were incidents of break-through bleeding in three cases. In one of these cases, the tourniquet was deflated after only three minutes and the surgery was performed without a bloodless field.

Ratings of postoperative pain on the self-administered WOMAC questionnaire during hospitalization did not differ between the randomization groups, but the patients in the LOP group reported significantly less stiffness in the knee on day four ($p = 0.020$) (see Appendix). The range of motion of the knee on postoperative day three and the ability to do a straight-leg lift did not differ between the groups (see Appendix).

Three patients (out of 131 available) had blisters underneath the tourniquet cuff immediately after surgery, but there was no difference between the LOP group and the control group ($p = 0.227$). All three patients had had a cuff pressure of ≥260 mm Hg.

On day four, eight patients (out of the 111 available) had developed blisters or other pressure-related injuries underneath the tourniquet cuff and sixty-five patients reported that they had pain in the quadriceps muscle underneath the tourniquet cuff (no differences between the groups, $p = 0.400$).

At the time of discharge, forty-seven patients (30% of the 158 available) had developed a surgical wound complication such as blisters, oozing from the wound, or signs of infection. As shown in Table II, forty of these forty-seven patients had had a cuff pressure of >225 mm Hg during surgery. None of the patients with a cuff pressure of ≤225 mm Hg had any signs of wound secretion or infection, but seven patients had blisters

TABLE I Cuff Pressures and Ratings by the Surgeon Regarding the Quality of the Bloodless Field and Technical Difficulties

	Control Group (N = 83)	LOP Group (N = 78)	P Value
Cuff pressure *(no. [%] of patients)*			<0.001
≤225 mm Hg	7 (8)	26 (33)	
226-259 mm Hg	45 (54)	22 (28)	
≥260 mm Hg	31 (37)	30 (38)	
Mean cuff pressure (±SD) *(mm Hg)*	252 ± 17*	246 ± 45†	0.362
Mean preanesthetic systolic blood pressure (±SD) *(mm Hg)*	154 ± 18	155 ± 21	0.426
Mean preoperative systolic blood pressure/limb occlusion pressure (±SD) *(mm Hg)*	119 ± 19‡	169 ± 34§	
Mean VAS score (±SD) for quality of bloodless field	9.4 ± 1.3	8.7 ± 2.4	0.364
Mean VAS score (±SD) for technical difficulties	1.4 ± 1.3	2.04 ± 2.3	0.307

*Chosen by the surgeon. †Recommended by the apparatus. ‡Preoperative systolic blood pressure measured on the arm, immediately before the tourniquet was applied and the skin incision was made, for determination of the cuff pressure by the surgeon. §Limb occlusion pressure measured on the thigh by the limb-occlusion-pressure apparatus.

TABLE II Results of Wound Check on Postoperative Day Four, According to Group and Cuff Pressure, for the 158 Patients Available*

	Control Group			LOP Group		
	≤225 mm Hg (N = 7)	226-259 mm Hg (N = 45)	≥260 mm Hg (N = 31)	≤225 mm Hg (N = 24)	226-259 mm Hg (N = 22)	≥260 mm Hg (N = 29)
No wound complication	5	31	24	19	15	17
Blisters	2	8	4	5	5	10
Oozing from the wound	0	5	3	0	1	1
Signs of infection	0	1	0	0	1	1

*The values are given as the number of patients. P = 0.149 for the difference between the LOP and the control groups.

TABLE III Results of Wound Check at Two-Month Follow-up Visit for the 156 Patients Available*

	Control Group			LOP Group		
	≤225 mm Hg (N = 7)	226-259 mm Hg (N = 44)	≥260 mm Hg (N = 30)	≤225 mm Hg (N = 25)	226-259 mm Hg (N = 21)	≥260 mm Hg (N = 29)
No wound complications	7	39	27	23	19	25
Blisters	0	0	0	0	0	0
Delayed wound-healing	0	3	1	2	1	2
Wound infection	0	2	2	0	1	2

*The values are given as the number of patients. P = 0.869 for the difference between the LOP and the control groups.

around the knee. There were no significant differences between the LOP and the control groups (p = 0.149).

At the time of follow-up two months after surgery, seven patients (4%) had a postoperative wound infection and nine patients (6%) were recorded as having delayed wound-healing. Four of these patients had developed a deep wound infection after they were discharged from the ward and had been rehospitalized and reoperated on. Of the sixteen patients with a surgical wound complication at the two-month follow-up visit, fourteen had had a cuff pressure of >225 mm Hg. Two patients who had had a cuff pressure of ≤225 mm Hg had delayed wound-healing (Table III). There were no differences between the LOP group and the control group (p = 0.869).

Six of the seven patients who had a postoperative wound infection and all four patients who had a deep wound infection were men. We found no difference in cuff pressures between men and women, but men had significantly longer bloodless-field times (mean, eighty-nine minutes compared with seventy-three minutes for women; p = 0.027).

Two patients had a deep venous thrombosis, and one patient had a nerve injury. There were no differences between the LOP group and the control group (p = 0.752), but the patient with a nerve injury had had a cuff pressure >260 mm Hg.

At the two-month follow-up visit, knee motion, assessed by a blinded orthopaedic surgeon, did not differ between the groups. No difference in any of the three domains of the self-administered WOMAC questionnaire was detected between the LOP group and the control group (data not shown).

Discussion

This study shows that the limb-occlusion-pressure measuring technique reduces the tourniquet cuff pressures in patients undergoing a total knee arthroplasty, but we could not demonstrate any differences in postoperative pain between our LOP and control groups.

The generally lower cuff pressure in the LOP group provided a good-quality bloodless field but did not have any impact on the risk of developing a postoperative wound complication or on the range of motion, although the patients in the LOP group reported less stiffness of the knee on postoperative day four.

An important secondary finding was that, regardless of the randomization group, patients with a cuff pressure of ≤225 mm Hg had no postoperative infections and a lower rate of wound complications at discharge and at the two-month follow-up evaluation.

In contrast to the reports by Reilly et al.[9] and Younger et al.[6,10], we could not demonstrate any significant differences in the mean cuff pressures between the LOP group and the control group. The chosen cuff pressure depends on such factors as the experience of the surgeon as well as on local traditions. The surgeons in our study generally used a rather low cuff pressure, with a mean of 252 mm Hg in the control group, compared with surgeons in other published studies, in which cuff pressures of 300 to 350 mm Hg have been reported[2,4,6,17,18]. However, the limb-occlusion-pressure method led to more individual cuff pressures among our patients, since the pressures ranged from 150 to 300 mm Hg (SD, ±45) in the LOP group compared with 200 to 300 mm Hg (SD, ±17) in the control group. The mean measured limb occlusion pressure in our study was 169 mm Hg, which is higher than the mean of 142 mm Hg in the study by Younger et al.[6]. Our tourniquet apparatus also had a higher preadjustable margin from the manufacturer than earlier described[6,9,10], which resulted in higher recommended tourniquet pressures and therefore also higher mean values—246 mm Hg in our study compared with 202 mm Hg in the study by Younger et al. and 198 mm Hg in the study by Reilly et al. Nevertheless, the limb-occlusion-pressure measuring technique led to lower margins: 77 mm Hg in the LOP group compared with 133 mm Hg in the control group.

All of our patients received local infiltration analgesia at the end of surgery, and most of them received it the next day as well. This was a rather new routine at our department and was effective for treatment of postoperative pain. The fact that postoperative pain treatment was good in all patients could be one of the reasons why we could not demonstrate any differences in postoperative pain between groups. Another reason could be that the WOMAC questionnaire might not be sensitive enough to capture relatively small differences in postoperative pain ratings.

We could not demonstrate any differences in knee motion between the groups. All patients achieved good knee flexion as early as on day three: the mean was 78° in the control group and 77° in the LOP group, compared with 47° on day three after total knee arthroplasty done with a tourniquet in the study by Li et al.[3]. Earlier studies comparing knee or ankle surgery with and without a tourniquet have shown significantly better knee flexion after surgery without a tourniquet[3,17,19]. The authors suggested that the swelling of the limb after use of a tourniquet might be an explanation. Tourniquet release is known to be associated with an immediate 10% increase in limb girth[20], which was reported to increase up to 50% over the first postoperative day[17].

There was a rather large number of wound complications in our study. One reason could be that we did not exclude patients with diabetes, as has been done in other studies[1,3,17,19]. In our study, even patients classified as ASA 3, and some later classified as ASA 4, were included. However, no patient in our study who had a cuff pressure of ≤225 mm Hg developed a postoperative wound infection. This finding is in accordance with the report by Clarke et al.[2], who studied the pattern of postoperative wound hypoxia seven days after knee surgery and found that a tourniquet cuff pressure of about 225 mm Hg yielded a significantly better return of the oxygen levels compared with cuff pressures of 350 mm Hg.

Butt et al.[21] demonstrated a significant association between increased tourniquet time and wound oozing after total knee arthroplasty. They had a mean tourniquet time of eighty-three minutes with a range of thirty-eight to 125 minutes. In our study, the mean tourniquet time was eighty-seven minutes. Six of the seven patients who had a postoperative wound infection in our study were men. We found no other differences between men and women other than a significantly longer bloodless-field time for men. In this study, we focused on cuff pressures and complications; however, the duration of the bloodless field is probably another important factor that requires further investigation.

The strength of this study is that it was a randomized controlled trial of a "nonselected" study population, with few exclusion criteria. A limitation might be that we used the WOMAC questionnaire as the primary outcome measure

since it may not be reliable enough to capture the small differences regarding postoperative pain. Another limitation of our study is that very few of our patients had a BMI of >35 kg/m^2 and therefore our results may not be valid for that patient group.

In conclusion, the generally lower tourniquet cuff pressure in the LOP group did not decrease the postoperative pain or other outcomes in our patients. However, patients who had undergone total knee arthroplasty in a bloodless field with a cuff pressure of ≤225 mm Hg had a lower rate of wound complications such as delayed healing and infections.

The limb-occlusion-pressure measuring technique can help the surgeon to choose more individual, often lower, cuff pressures. However, if the surgeon carefully chooses an optimal and not too high cuff pressure and considers the type and width of the cuff, the circumference of the limb, and the patient's individual vessel characteristics, both methods appear to yield a good outcome in terms of postoperative complications.

Appendix

eA Tables showing demographic baseline data and the duration of the bloodless field as well as the results of the WOMAC, range of motion, and straight-leg lifting are available with the online version of this article as a data supplement at jbjs.org. ■

Charlotta Olivecrona, RN
Sari Ponzer, MD, PhD
Per Hamberg, MD, PhD
Richard Blomfeldt, MD, PhD
Section of Orthopaedics,
Department of Clinical Science and Education,
Södersjukhuset Karolinska Institutet,
SE-118 83 Stockholm, Sweden.
E-mail address for C. Olivecrona: charlotta.olivecrona@sodersjukhuset.se.
E-mail address for S. Ponzer: sari.ponzer@ki.se.
E-mail address for P. Hamberg: per.hamberg@sodersjukhuset.se.
E-mail address for R. Blomfeldt: richard.blomfeldt@sodersjukhuset.se

References

1. Abdel-Salam A, Eyres KS. Effects of tourniquet during total knee arthroplasty. A prospective randomised study. J Bone Joint Surg Br. 1995 Mar;77(2):250-3.
2. Clarke MT, Longstaff L, Edwards D, Rushton N. Tourniquet-induced wound hypoxia after total knee replacement. J Bone Joint Surg Br. 2001 Jan;83(1):40-4.
3. Li B, Wen Y, Wu H, Qian Q, Lin X, Zhao H. The effect of tourniquet use on hidden blood loss in total knee arthroplasty. Int Orthop. 2009 Oct;33(5):1263-8. Epub 2008 Aug 27.
4. Noordin S, McEwen JA, Kragh JF Jr, Eisen A, Masri BA. Surgical tourniquets in orthopaedics. J Bone Joint Surg Am. 2009 Dec;91(12):2958-67.
5. Worland RL, Arredondo J, Angles F, Lopez-Jimenez F, Jessup DE. Thigh pain following tourniquet application in simultaneous bilateral total knee replacement arthroplasty. J Arthroplasty. 1997 Dec;12(8):848-52.
6. Younger AS, McEwen JA, Inkpen K. Wide contoured thigh cuffs and automated limb occlusion measurement allow lower tourniquet pressures. Clin Orthop Relat Res. 2004 Nov;(428):286-93.
7. Estebe JP, Le Naoures A, Chemaly L, Ecoffey C. Tourniquet pain in a volunteer study: effect of changes in cuff width and pressure. Anaesthesia. 2000 Jan;55(1):21-6.
8. Pedowitz RA, Gershuni DH, Botte MJ, Kuiper S, Rydevik BL, Hargens AR. The use of lower tourniquet inflation pressures in extremity surgery facilitated by curved and wide tourniquets and an integrated cuff inflation system. Clin Orthop Relat Res. 1993 Feb;(287):237-44.
9. Reilly CW, McEwen JA, Leveille L, Perdios A, Mulpuri K. Minimizing tourniquet pressure in pediatric anterior cruciate ligament reconstructive surgery: a blinded, prospective randomized controlled trial. J Pediatr Orthop. 2009 Apr-May;29(3):275-80.
10. Younger AS, Manzary M, Wing KJ, Stothers K. Automated cuff occlusion pressure effect on quality of operative fields in foot and ankle surgery: a randomized prospective study. Foot Ankle Int. 2011 Mar;32(3):239-43.
11. American Society of Anesthesiologists. ASA Physical Status Classification System. http://www.asahq.org/home/for-members/clinical-information/asa-physical-status-classification-system. Accessed 2012 Sep 4.
12. Dripps RD, Lamont A, Eckenhoff JE. The role of anesthesia in surgical mortality. JAMA. 1961 Oct 21;178:261-6.
13. Olivecrona C, Tidermark J, Hamberg P, Ponzer S, Cederfjäll C. Skin protection underneath the pneumatic tourniquet during total knee arthroplasty: a randomized controlled trial of 92 patients. Acta Orthop. 2006 Jun;77(3):519-23.
14. Kerr DR, Kohan L. Local infiltration analgesia: a technique for the control of acute postoperative pain following knee and hip surgery: a case study of 325 patients. Acta Orthop. 2008 Apr;79(2):174-83.
15. Bellamy N, Buchanan WW, Goldsmith CH, Campbell J, Stitt LW. Validation study of WOMAC: a health status instrument for measuring clinically important patient relevant outcomes to antirheumatic drug therapy in patients with osteoarthritis of the hip or knee. J Rheumatol. 1988 Dec;15(12):1833-40.
16. Roos EM, Klässbo M, Lohmander LS. WOMAC osteoarthritis index. Reliability, validity, and responsiveness in patients with arthroscopically assessed osteoarthritis. Western Ontario and MacMaster Universities. Scand J Rheumatol. 1999;28(4):210-5.
17. Konrad G, Markmiller M, Lenich A, Mayr E, Rüter A. Tourniquets may increase postoperative swelling and pain after internal fixation of ankle fractures. Clin Orthop Relat Res. 2005 Apr;(433):189-94.
18. Tejwani NC, Immerman I, Achan P, Egol KA, McLaurin T. Tourniquet cuff pressure: the gulf between science and practice. J Trauma. 2006 Dec;61(6):1415-8.
19. Wakankar HM, Nicholl JE, Koka R, D'Arcy JC. The tourniquet in total knee arthroplasty. A prospective, randomised study. J Bone Joint Surg Br. 1999 Jan;81(1):30-3.
20. Estebe JP, Davies JM, Richebe P. The pneumatic tourniquet: mechanical, ischaemia-reperfusion and systemic effects. Eur J Anaesthesiol. 2011 Jun;28(6):404-11.
21. Butt U, Ahmad R, Aspros D, Bannister GC. Factors affecting wound ooze in total knee replacement. Ann R Coll Surg Engl. 2011 Jan;93(1):54-6. Epub 2010 Sep 10.

HemaClear®

Sterile & Bloodless Surgical Field

White Papers

Anesthesiology

www.HemaClear.com

Pathophysiology and Prevention of HemaClear Tourniquet Failure

Prof. Noam Gavriely, MD, DSc.

Chief Medical Office, OHK Medical Devices - HemaClear®, Haifa, Israel

Abstract

Tourniquet failure (TF) occurs when blood enters a limb beneath the tourniquet. This review analyzes the causes of primary TF – when the blood flow is not occluded a-priori, and secondary TF – when arterial flow is initially stopped, but resumes some time into the case. If TF occurs, the tourniquet must be removed to prevent venous engorgement, stagnation and clotting.

Arterial tourniquets are used to block the blood flow into a limb during surgery to achieve a blood-free surgical site. Tourniquet failure is defined as a condition whereby blood enters the limb beneath the occluding tourniquet. As such, the tourniquet becomes a venous occlusion device with blood accumulating in the vascular bed distal to the occlusion.

There are three factors that determine the ability of a tourniquet to block blood flow into a limb:

1. Arterial systolic blood pressure ($P_{systolic}$);
2. The pressure the tourniquet exerts right outside of the artery ($P_{tourniquet}$); and
3. The stiffness of the artery ($P_{buckling}$).

This can be expressed by a simple expression:

$$P_{tourniquet} - (P_{systolic} + P_{buckling}) > 0$$

Or, in other words, the pressure of the tourniquet on the artery must overcome the systolic blood pressure and the stiffness of the arterial wall.

In addition, it is imperative that the tourniquet is placed in the correct anatomical location.

We shall now evaluate each parameter with respect to the two types of tourniquet failure (TF) that one may encounter: (a) primary tourniquet failure (1° TF), and (b) secondary tourniquet failure (2° TF).

1° TF

This is a condition where arterial blocking was never achieved and blood continues to flow into the limb right after the application of the tourniquet. This is an uncommon situation and there are three main conditions that lead to it:

1. **Calcified arteries.** This can be seen on x-ray of the limb and TF may be anticipated. It has been described with pneumatic tourniquets[1] and was recently encountered in Cardiff, Wales with the HemaClear (HC) tourniquet (Figure 1).

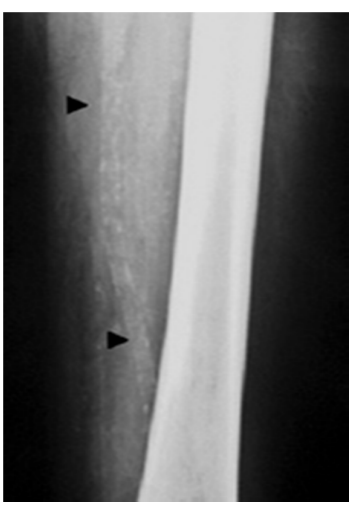

Figure 1. X-Ray of calcified arteries.

©2012 OHK Medical Devices – HemaClear®

2. **A steep increase in arterial blood pressure (BP) immediately following the application of the HC on a leg.** This has particularly been observed in obese patients (Figure 2). The two lower images were taken just before and just after HC application on the obese leg shown in the top photo. Note the 40mmHg rise in systolic BP with virtually the same heart rate). The pathophysiology underlying this is the rapid shifting of blood from the leg into the central circulation. An adult leg holds about 500 ml of blood and in the obese person it can be as much as 750 ml. When HemaClear is applied, it exsanguinates the leg almost completely (~95%). This amount of blood is rapidly auto-transfused, and an elevation of BP is unavoidable. This is particularly so in patients who have a tendency for hypertension. As such, we currently recommend that when the HC-XL is used, the application is done in two steps. First, the device should be rolled up to the knee level, where a pause for 30-90 sec is taken. During this time, it is recommended that the anesthesiologist take a BP reading. If the systolic level approaches 160 mm Hg, it is suggested that hypotensive measures are taken (e.g. small dose of NTG be administered). Once the BP is back to normal levels (i.e. <140 mmHg), the HC can be brought up all the way to the groin. The above mentioned process will prevent this type of 1° TF.

3. **Incorrect selection of HC type.** HC pressure is factory-set and cannot be changed. However, there are 4 HC sizes (Small, 40, 55 and XL) and from the 40 and 55 there are 3 pressure levels: 130 mmHg, 160 mmHg and 190 mmHg. The HC-SM is rated to 130 mm Hg and the HC-XL is rated to 160 mm Hg. Selecting an incorrect size (e.g. an HC-40 which is rated for 24-40 cm circumference for a 20 cm forearm) will result in a primary non-occlusion. Likewise, a selection of the incorrect pressure model (e.g. an HC-55 blue which is rated to 130 mm Hg for a hypertensive patient with a systolic blood pressure of 155 mm Hg) will result in primary TF.

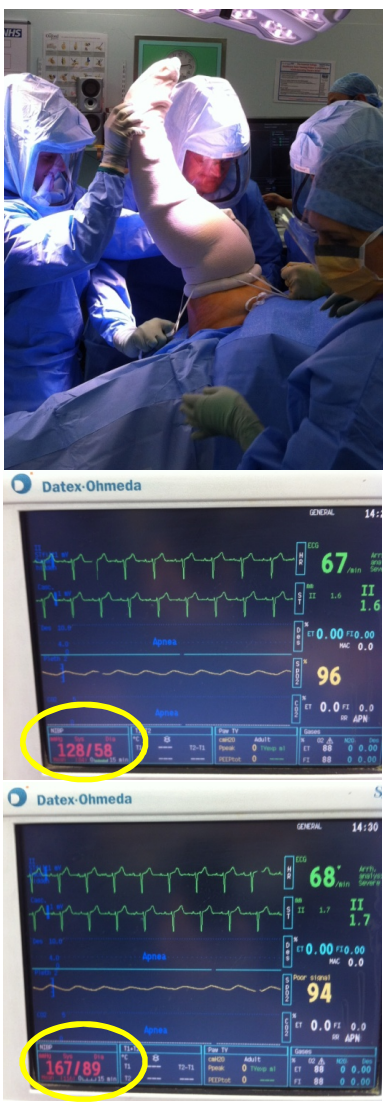

Figure 2. Surgical images from obese patient using HemaClear.

©2012 OHK Medical Devices – HemaClear®

2° TF

This is a situation where the blood flow into the limb is initially blocked and there is no bleeding at the beginning of the case, but blood appears in the surgical field later in the procedure. There are two main causes of 2° TF:

1. **The rise in arterial blood pressure in the middle of the case.** As is well known to anesthesiologists, a rise of BP is almost always is due to the activation of the autonomic nervous system secondary to pain or anxiety. In a patient under general anesthesia, this is the result of inadequate analgesia. In a conscious patient managed with spinal or regional block, this is usually caused by anxiety, other stimulation from within, or from the environment. Either way, it is important to monitor BP closely in all patients where HC is used, particularly if there is a history of hypertension. This can be done by taking measurements frequently (e.g. every 5 minutes), especially at times during surgery where there could be increased pain or acoustic stimuli.

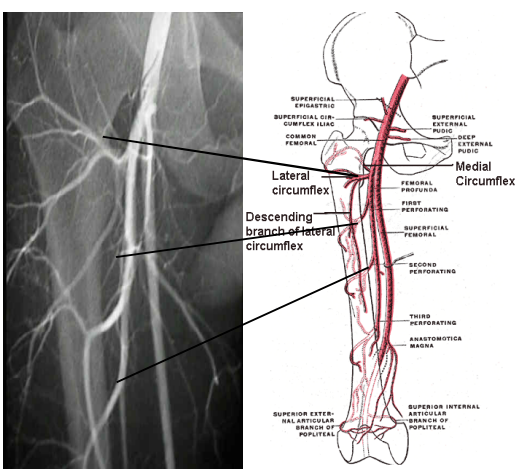

Figure 3. X-Ray & diagram of femoral artery.

2. **A special case of 2° TF is when bleeding starts once the bone is being cut.** The cause of this is related to the arterial anatomy of the upper leg circulation (Figure 3). The femoral artery has three branches that feed the femur: the proximal, middle and distal femoris arteries. It is easy to see that if the HC is not placed high enough on the thigh, the proximal femoris artery will not be blocked and, as a result, the medulla of the femur will continue to receive blood supply. As such, if the bone is being cut, blood can seep through the trabecullae and the surgical field will fill with blood. This, of course, defeats the purpose of the arterial blocking, particularly at the cementing time when it is most desired.

Summary and Checklist

The above discussion clearly shows that TF can almost always be prevented and, in the case of calcification, at least anticipated. It is important to pay attention to the details of the product and anesthesia care. Below is a table that contains a checklist that can provide further assistance in the process.

It is important to note that if TF is encountered it is important to remove the tourniquet right away and restore circulation. This is needed in order to prevent intravascular clotting of the blood that entered the limb, even if active bleeding has stopped. Once the cause of the TF has been determined and corrected (e.g. lower BP, correct product selection, better HC position, etc.), a second HC can be used to exsanguinate the limb and block blood flow. The sterile HC can be safely rolled over the open incision.

©2012 OHK Medical Devices – HemaClear®

Table – Summary and Checklist

	Condition	Action or reaction
Pre-op evaluation	Patient has calcified arteries on x-ray	Anticipate 1° TF. Evaluate arterial occlusion before making first incision. If bleed-through, remove HC and proceed without tourniquet.
	Patient has tendency for hypertension.	Alert anesthesiologist for need to monitor BP frequently and control systolic pressure. Use tightest HC model.
	HC model selection	Nurse/technician should measure circumference and prepare the correct HC size.
During surgery	Obese patient	Use the two-stage method. Coordinate with anesthesiologist with possible need for NTG. Secure HC in as proximal position near groin as possible.
	Anesthesia, analgesia and sedation	Patient's level of anesthesia should be monitored. Any rise in heart rate should be viewed as a potential sign of subconscious pain or, if under regional/spinal block - anxiety.
If bleed-through occurs	**Remove HC immediately**	**Even if bleeding has stopped**

References:

[1] Chandrappa HN, Deepak BS. Tourniquet failure during total knee replacement due to femoral arterial calcification. J Anaesthesiol Clin Pharmacol [serial online] 2010 [cited 2012 May 1];26:551-2. Available from: http://www.joacp.org/text.asp?2010/26/4/551/74612)

©2012 OHK Medical Devices – HemaClear®

Incomplete Leg Exsanguination: A Possible Cause of Post Total Knee Arthroplasty (TKA) Cognitive Deficit (CD)

Noam Gavriely, MD, DSc.

Chief Medical Officer, OHK Medical Devices - HemaClear®, Haifa, Israel

Abstract

Introduction & Aims: Mild to moderate CD after TKA is a common side-effect of an otherwise successful procedure. Despite improvement in the majority of the cases within weeks to a few months, this is a source of concern and disappointment. This analysis presents a possible mechanism for post-TKA cognitive changes.

Method: We reviewed the literature on the hemodynamic events around limb exsanguination, tourniquet placement and release during TKA. The majority of this literature is in anesthesia journals, with only a few in orthopedic journals (e.g., Berman, *JBJS*, 1998, 389-96). Once the data were collected, we scrutinized it for validity and in order to identify a plausible etiology that links between the TKA operating procedure and CD.

Results: Limb elevation, Esmarch bandage, or Rhys-Davis exsanguinators are used prior to tourniquet inflation. Blond et al, (*Acta Orthop Scand*. 2002; 73:89–92) showed that at best, 70% of the limb's blood was exsanguinated. Miller et al. (*Ann. Surg*. 1979; 190: 227-230) demonstrated that blood remaining inside the vessels of an occluded limb coagulates. Parmet et al (*Lancet*. 1993; 341:1057-8) observed a shower of echogenic material in the right atrium approximately 30 seconds after tourniquet release in ALL patients. Berman et al., (*JBJS*, 1998, 389-96) documented that this echogenic material consisted of fresh thrombi and not fat, bone marrow or cement. These thrombi partially occlude the pulmonary circulation, elevating the pressure in the right heart. As such, the blood pressure balance across the septum of the right atrium reverses. For patients with patent foramen ovale, blood flows from right to left. This brings echogenic material to the cerebral circulation in over 50% of TKA patients as detected by transcranial Doppler ~50 seconds after tourniquet release (Sulek, *Anesthesiology* 1999; 91:672–6). These cerebral emboli were associated with new brain infarcts detected by pre- and post-TKA MRI imaging (Koch, *J Neuroimaging*. 2007 17:332-5). The last step in this chain-of-evidence analysis is the statistics of CD post-TKA (Rodriguez, *J Arthroplasty.* 2005 20:763-71.)

Conclusions: The disproportionate prevalence of CD post-TKA as compared to other surgical procedures performed under similar types of anesthesia and in similar patients is worrisome. This hemodynamic analysis invokes a hypothesis that links incomplete limb exsanguination with cognitive dysfunction. Prospective studies where near-perfect exsanguination is applied in comparison with the current methods should be performed.

Bloodless Surgical Field

Most surgeons exsanguinate the leg and use a tourniquet to occlude blood flow as a routine method of maintaining a bloodless surgical field during total knee arthroplasty. Some prefer using it for the entire duration of the operation, while others only block the arterial flow into the leg for cementing of the implanted knee. In any event blood flow is stopped for anywhere between 30-120 minutes (maximum). This brief review is focused on the practice of limb exsanguination and the consequences of the incomplete removal of the blood from the vessels in the leg.

Exsanguination

The current methods of limb exsanguination before application of the tourniquet include the following methods:

©2012 OHK Medical Devices – HemaClear®

1) Esmarch bandage wrapped tightly from distal to proximal;
2) Limb elevation;
3) Rhys-Davies exsanguinator (Woodville Polymer Engineering, Derbyshire, UK)[1] and the Pomidor roll-cuff (Pomidor AB, Varnamo, Sweden);
4) an elastic exsanguination tourniquet (HemaClear®, OHK Medical Devices, Haifa, Israel).[2]

In a series of studies, Blond et al.[3] used Tc99-tagged red blood cells to measure the extent of blood removal from a limb by applying each of the first three methods listed above.

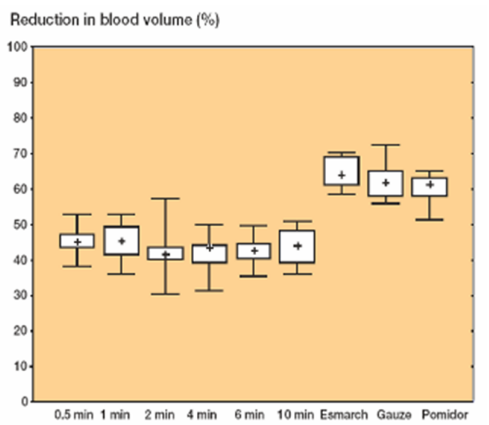

Figure 1. Results of various exsanguination methods in 12 subjects expressed as median (+), range and inter quartile percentage reduction in blood volume calculated from counts before and after exsanguination. Limb elevation achieved less than 50% count reduction. Esmarch about 65%.[4]

Figure 1 summarizes Blond's findings. They found that the best level of exsanguination was obtained with the Esmarch bandage. It was able to remove nearly 70% of the blood. The Pomidor, a device that is similar to, but smaller than the Rhys-Davies, was found to have removed slightly over 60% of the blood. Limb elevation was the least effective with no more than 45% of the blood was removed irrespective of the duration of holding the limb up.[5] As such, these studies clearly indicate that a substantial (eg. 30-55%) amount of the blood remains in the limb at the time the tourniquet is applied and blood flow ceases. No similar studies have been done so far with the elastic exsanguinating tourniquet, but multiple clinical studies have indicated that the exsanguination is near perfect (Fig. 2).[6]

Figure 2. A nearly bloodless surgical field when using silicone exsanguinating ring.

Intravascular Coagulation

When blood stops flowing or becomes stagnant, it tends to coagulate and form fresh thrombi. Clot formation during tourniquet application has been demonstrated in 1979 in subhuman primates.[7] There are several factors that promote coagulation during total knee arthroplasty. These include reduced temperature, hypoxia and seepage of activated complement components from the incision site.

The time it takes for blood to coagulate from the onset of tourniquet application is under 6 minutes and is certainly less than 30 minutes[8]. With more than a pint of blood in the vessels of a normal sized leg. Incomplete exsanguination as outlined above will leave behind 120-250 mL of blood in the leg. When this residual blood clots, there is a certain degree of separation between the plasma and the clot so that the actual clot volume is probably 50-120 mL, depending on the pre-operative hematocrit.

The Events at Tourniquet Release

When tourniquet pressure is reduced ("tourniquet down"), blood floods into the limb first into the arterial side and shortly thereafter blood starts flowing in the veins. The blood flow sweeps with it the fresh thrombi from the

©2012 OHK Medical Devices – HemaClear®

veins into the inferior vena cava and into the right atrium. Multiple studies where the right atrium was monitored with trans-esophageal Doppler have identified a shower of echogenic material in the atrium in all the patients. Several of these studies are worth mentioning more in detail. In 2002, Hirota et al.[9] did a quantitative analysis of the extent of the material traveling across the atrium. They found a peak density of about 20% of the atrium cross sectional area. This peak occurred approximately 30 seconds after the release of the tourniquet and gradually subsided over the next 10-15 minutes.

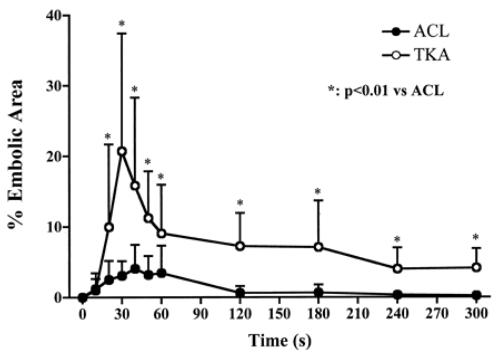

Figure 3. Time course of emboli formation in the right atrium (RA) after tourniquet release in the anterior cruciate ligament (ACL) and total knee arthroplasty (TKA) groups. *P < 0.01 versus ACL. All data are mean ± sd.

Another important publication is a study by Berman et al. in the JBJS in 1998.[10] In addition to documenting the fact that all the patients had echogenic material passing through their right atrium, they specifically evaluated the nature of the material. They inserted catheters into the femoral veins in the right atria in some of the patients that participated in the study, and aspirated blood immediately after the release of the pneumatic tourniquet. All the aspirates that contained solid material consisted of soft thrombus and did not contain fat, marrow, or cement material. The ongoing existing controversy on the nature of this echogenic material before the publication of this study was ended by these results.

Another study that shed light on this phenomenon was done by Parmet at al.[11] in 1998, where they compared the extent of the echogenic material in patients undergoing total knee arthroplasty with and without a pneumatic tourniquet. They found a 5.3 fold increase in the amount of material at the time of the tourniquet release in the tourniquet group compared to those patients where a tourniquet was not used. As such, it is clear from this study that the presence of thrombi is directly and unequivocally related to the stagnation of the blood in the leg.

Some of the studies attempted to correlate the duration of the application of the tourniquet with the extent of the thrombi recognized by the trans-esophageal Doppler. These studies did not show any statistically significant correlation. However, it should be noted that in all the studies tourniquet time was substantially greater than typical clotting time of blood. As such, one would not expect to see a correlation if in all patients clotting had already occurred. To date, no studies have yet been published on the extent of the echogenic material at the release of newer elastic exsanguination tourniquet.

Hemodynamic Effect of Thrombi Migration into the Right Heart

The clots that sweep through the right atrium continue into the right ventricle and the pulmonary arteries, and eventually lodge in the more distal arteries and arterioles in the pulmonary circulation. There they occlude the blood flow, thereby diverting the blood into other parts of the lung. Pulmonary vascular resistance goes up and the afterload of the right ventricle increases. In most normal patients the right ventricle reacts by increasing its end systolic pressure, as well as the end diastolic pressure. However, the pulmonary blood flow may be impeded to a degree, leading to a transient reduction in the venous return into the left atrium and ventricle. It is safe to assume that the Frank-Starling mechanism will reduce the left ventricular contractility and cardiac output. The negative inotropic effect is compounded

©2012 OHK Medical Devices – HemaClear®

by the effect of the acidic blood coming from the legs' veins, which may also include high levels of carbon dioxide and potassium. During the period of occlusion of blood flow there is tissue hypoxia and a buildup vasodilator. These dilate the arterioles causing a decrease in vascular resistance. When tourniquet is released and perfusion is restored, blood flow is elevated leads to reactive hyperemia. The reactive hyperemia results in a washout of the acidic blood

The accumulated effect of these factors cause a sudden drop in systolic and diastolic blood pressure which is very familiar to anesthesiologists who care for patients undergoing TKA. The common practice is to infuse 560-1000 mL of fluids just prior to tourniquet release in anticipation of this pressure drop. As such, one may conclude that the effect of the pulmonary emboli at the time of the tourniquet release is not associated with the detrimental cardio pulmonary consequences of any lasting importance. However patients with preexisting conditions, such as pulmonary hypertension, COPD, congestive heart failure and related illnesses, should be given special attention to these effects.

Right-Left Shunt and Thrombi into the Arterial Circulation

In about 20%[12] of the population, the foramen ovale is closed by a detachable flap that prevents blood from moving from the higher pressure left atrium into the right atrium. This flap can open like a one way valve when the pressure in the right atrium rises above that on the left. This happens when emboli occlude the pulmonary circulation, as described in the previous section. This circumstance causes the right to left flow of blood which is saturated with thrombi from the limb clot. Once in the left side, the thrombi readily move into the left ventricle and are pumped into the arterial system. With the carotid arteries being the first branches out from the aortic arch in a straight line orientation, it is not surprising that at least some of these clots move into the cerebral circulation. This has been documented by trans-cranial Doppler in a number of studies that showed nearly 60% prevalence of echogenic material in the Circle of Willis with a peak at 50 seconds after the pneumatic tourniquet is released.[13] Other paths of the right-left shunt of blood and clots are through AV connections in the lungs that open up when pulmonary blood pressure rises.

Brain Infarcts Post Total Knee Arthroplasty

The first publication on cerebral emboli post TKA[14] failed to document cerebral infarcts by brain CT. However, a subsequent study by Monk et al[15] in 2005 clearly showed by MRI before and after TKA that 5 from 22 patients had new brain infarcts. The difference between the two papers is probably explained by the fact that small brain infarcts surrounded by edematous brain tissue are more readily detected by MRI than CT scan.

Post TKA Cognitive Dysfunction

The entity of reduced cognition after elective TKA is well known and well documented. The prevalence has been researched in a number of studies with observations that more than 40% of the patients have cognitive dysfunction seven days after surgery and more than 15% still had cognitive dysfunction 3 months after surgery. The percentages are much higher than observed in other procedures by general surgeons with similar types of anesthetics. As such, the notion that this cognitive dysfunction has to do with the performance of the anesthesiologist is not supported by the evidence. On the contrary, it is quite plausible and at least indirectly documented that these cognitive changes are the result of cerebral emboli infarction.

Summary

A flow diagram below summarizes the events leading from incomplete limb exsanguination to cognitive dysfunction during TKA.

©2012 OHK Medical Devices – HemaClear®

Conclusions

Prevention of blood stagnation in the exsanguinated limb seems to be the critical element in this chain of events described above. This can be done by avoiding the use of the tourniquet all together or by using a technology that exsanguinates the blood better than with the current methods (Esmarch, limb elevation, Rhys-Davis). HemaClear® is one such device that exsanguinates the entire blood from the limb (except the blood within the bone marrow).

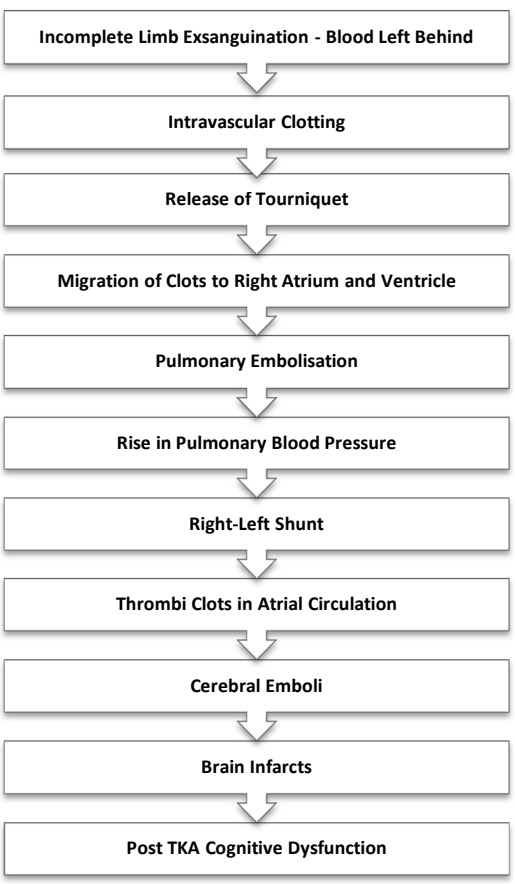

Figure 4. Cascade of events that link post TKA CD with incomplete leg exsanguination. See text for details.

References

[1] Rhys-Davies NC, Stotter AT. The Rhys-Davies Exsanguintor, Annals of the Royal College of Surgeons of England. 1985; 67: 193-195.

[2] HemaClear® [homepage on the internet]. Haifa: OHK Medical Devices; c2010 [cited 2012 Apr 3]. Available from: http://www.hemaclear.com/

[3] Blond L, et al. Exsanguination of lower limbs in healthy male subjects, Acta Orthop Scand. 2002; 73 (1):89–92.

[4] *Ibid.*

[5] *Ibid.*

[6] Boiko M, Roffman M. Evaluation of a novel tourniquet device for bloodless surgery of the hand. .J Hand Surg [Br]. 2004;29B:185–187.

[7] Miller SH, et al. Intravascular coagulation and fibrinolysis within primate extremities during tourniquet ischemia. Ann Surg. 1979;190:227-230.

[8] Kohro M, et al. Surgical/tourniquet pain accelerates blood coagulability but not fibrinolysis. Br. J. Anesth. 1998; 80: 460-463.

[9] Hirota K, et al. Quantification and comparison of pulmonary emboli formation after pneumatic tourniquet release in patients undergoing reconstruction of anterior cruciate ligament and total knee arthroscopy. Anesth Analg. 2002; 94(6):1633-38.

[10] Berman AT, et al. Emboli observed with use of transesophageal echocardiography immediately after tourniquet release during total knee arthroplasty with cement. J Bone Joint Surg Am. 1998 Mar;80(3):389-96.

[11] Parmet JL, et al. The incidence of large venous emboli during total knee arthroplasty without pneumatic tourniquet use. Anesth Analg. 1998 Aug;87(2):439-44.

[12] Lechet PH, et al. Prevalence of patent foramen ovale in patients with stroke. N Engl J Med 1988;1148–52.

[13] Sulek CA, et al. Cerebral microembolism diagnosed by transcranial Doppler during total knee arthroplasty. Anesthesiology. 1999; 91:672–6.

[14] *Ibid.*

[15] Monk TG, et al. The influence of tourniquet time on cerebral embolic events in elderly patients undergoing total knee arhtroplasty. Tallahassee (FL): National High Magnetic Field Laboratory; 2004. Report No.: 2004-NHMFL-Report165.

©2012 OHK Medical Devices – HemaClear®

Regional and Local Anesthesia of the Wrist and Hand Aided by a Forearm Sterile Elastic Exsanguination Tourniquet - A Review

Noam Gavriely, MD, DSc.

Chief Medical Officer, OHK Medical Devices - HemaClear®, Haifa, Israel

Antonios Kotsirakis, MD.

Surgical Department 251, General Air Force Hospital, Hellenic Air Force Base, Athens, Greece

Keywords:

Intravenous regional anesthesia, IVRA, Carpal Tunnel Release, Hand surgery

Running Header:

Regional Anesthesia of the Hand with Forearm Sterile Exsanguination Tourniquet

Corresponding Author:

1) Noam Gavriely, MD, DSc.
   16 Palyam St., Haifa 33095, Israel
   Phone: +972-544-661337, Fax: +972-4-8346753
   E-mail: noam@hemaclear.com
2) Antonios Kotsirakis, MD.
   http://gr.linkedin.com/pub/antonios-kotsirakis/44/ab5/696

Conflicts of Interest:

Noam Gavriely is the founder, shareholder and salaried Chief Medical Officer of OHK Medical Devices Ltd., the manufacturer of the HemaClear® device used in this study.

Abstract

Hand and wrist procedures range in various lengths of time and are performed under bleeding-free conditions achieved by exsanguination and tourniquet. The purpose of this paper is to describe regional and local anesthesia options facilitated by the use of forearm tourniquet, in particular the forearm sterile elastic exsanguination tourniquet (FA-SET). The paper will focus on two main strategies: (i) Local incision-site infiltration while the FA-SET is tolerated by the patient without anesthesia or with additional topical anesthesia at the site of the tourniquet; and (ii) Intravenous regional anesthesia (IVRA – Bier Block) performed with the FA-SET in place. The conclusions from our experience is that (a) for short procedures local infiltration with FA-SET in place is well tolerated by the patient; and (b) the use of the FA-SET for IVRA is superior and safer over the traditional method of using an upper arm pneumatic tourniquet.

©2012 OHK Medical Devices – HemaClear®

Introduction

Hand and wrist surgical procedures range from very short, such as carpal tunnel release (CTR), to medium (e.g. distal radius internal fixation), to long (e.g. multiple digital joint replacements). These procedures do have in common the need for effective anesthesia and in the majority of cases are performed under bleeding-free conditions achieved by some sort of exsanguination and tourniquet. The purpose of this paper is to describe regional and local anesthesia options facilitated by the use of the forearm tourniquet, in particular the forearm sterile elastic exsanguination tourniquet (FA-SET).

Our focus is on two main strategies: (i) Local incision site infiltration while the FA-SET is tolerated by the patient without or with additional topical anesthesia at the site of the tourniquet; and (ii) Intravenous regional anesthesia (IVRA – Bier Block) performed with the FA-SET in place. We hereby describe our experience with the FA-SET in both categories.

The Forearm Sterile Elastic Exsanguination Tourniquet

The FA-SET (HemaClear®, OHK Medical Devices Ltd. Haifa Israel) consists of an elastic silicone ring, wrapped around by a tubular stockinet and four straps terminated by two handles (App. Figure 1a). The FA-SET is placed on a conical application cup that helps in its placement on the fingers and the initiation of its rolling up the hand. The FA-SET is sterile (Ethylene Oxide sterilization) and comes double wrapped in individual packs. When the straps are pulled proximally along the axis of the arm, the ring rolls over the hand, wrist and forearm and the stockinet is released to cover the skin (App. Figure 1b). The final position of the FA-SET is 10-12 cm above the root of the palm. The rolling applies uniform circumferential force on the tissues, translated into radial pressure that effectively squeezes the blood out (exsanguination) and blocks the arterial flow into the hand. The application of the FA-SET is quick and smooth, taking 3-5 seconds.

Short procedures

Hand procedures that take no more than 15 minutes (e.g. Carpal Tunnel Release) may be performed with the FA-SET and local infiltration without any additional sedation or anesthesia. The patient should be alerted in advance about the discomfort associated with the compression of the FA-SET and should be verbally coached during the short duration of discomfort. For patients who are not in complete control of their faculties (i.e. cognitive dysfunction) or patients who seem very apprehensive, an alternative method should be offered (see below). Studies conducted with both pneumatic tourniquets and with the SET show significantly better tolerance of a tourniquet on the forearm as compared to the upper arm ( ).

©2012 OHK Medical Devices – HemaClear®

When the patient, the surgeon, or the anesthesiologist determine that supplemental analgesia is needed to obviate tourniquet discomfort and pain, there are two techniques that are readily available:

1. Ring anesthesia – infiltration of the subcutaneous tissue in the area where the FA-SET will be placed with a local anesthetic (e.g. 50% diluted Citanest solution using 22 G × 3 1/2″ size spinal needle (Sujia®)); or
2. Circumferential spreading of a cream composed of 5% lidocaine and 5% prilocaine (Emla® Astra) on the skin over the area where the FA-SET will be placed.

In a prospective randomized study using a forearm pneumatic tourniquet, Inal, et al.(2009) found that anesthesia using Emla cream is equally effective and less disturbing than using the subcutaneous injection technique. They also commented that a tourniquet placed at the distal forearm is effective, safe, and a useful technique for hand surgery.

Longer procedures

Intravenous regional anesthesia (IVRA) or Bier Block becomes safer and more efficient when the FA-SET is used. This is primarily due to the smaller dose of lidocaine needed to effect surgical anesthesia of the hand. The following is a step-by-step annotated description of FA-SET – assisted IVRA:

1. An IV cannula is inserted and secured (App. Figure 1a). It is preferred to use a cannula with no side port (not as shown) which is flatter, but not a “butterfly”. The hand and forearm are disinfected. Securing the catheter in place can be done with a sterile bandage to prevent dislodgement when the FA-SET is applied.
2. The FA-SET is applied as usual (see description above) using the sterile technique. The optimal position is about 10-13 cm (4-5”) proximal to the root of the palm (App. Figure 1b).
3. The IV cannula is exposed (App. Figure 1c) and lidocaine 0.5% or another local anesthetic commonly used for IVRA is injected into the cannula (Figure 1d). We use 20-25 ml of the solution (100-125 mg). Given the fact that the veins are emptied, the intra-vascular pressure associated with the injection of such small volume is low, certainly under arterial pressure, thereby avoiding leakage of anesthetics beneath the FA-SET into the central circulation.
4. In our experience, the hand is fully under surgical anesthesia in 3-7 minutes, verified by pricking the skin with a sterile needle. The level of exsanguination is very good as seen by the minimal stain on the pad and the surgeon’s gloves (App. Figure 1e). In case the patient complains about tourniquet discomfort and pain, the FA-SET is simply moved distally a few centimeters by manually rolling it in the distal direction to a position that has already been anesthetized.

©2012 OHK Medical Devices – HemaClear®

5. Suturing (App. Figure 1f) and compression dressing (App. Figure 1g) can be done before or after release of the FA-SET. Note that in view of the fact that the overall quantity of lidocaine is kept low (e.g. not more than 1.5 mg/kg) and within the therapeutic dose typically used for multiple PVCs, there is no risk associated with early release of the occlusion.
6. The removal of the FA-SET is done by cutting the ring with a scalpel (App. Figure 1h) and the fabric with scissors. App. Figure 1i shows the compression marks on the skin after the removal of the FA-SET ring.
7. The "dissected" FA-SET is shown in App. Figure 1j. The blue silicone ring is the elastic mechanism which applies calibrated pressure on the forearm.

It should be noted that performing IVRA with the FA-SET is tolerated well by the patients. It saves a few minutes of tourniquet time as the FA-SET can be removed as soon as the surgical procedure is completed, and it increases significantly the overall OR throughput. The fact that the FA-SET is sterile, as compared with the non-sterile and often dirty (App. Figure 2) pneumatic cuff, enhances the overall margin of safety.

The main differences from the traditional IVRA are the forearm placement of the FA-SET, its sterility, and the elimination of the pneumatic system from the process, notwithstanding the concern about sudden pressure loss or confusion between distal vs. proximal cuff inflation. In addition, while the IV cannula can be placed by the anesthesiologist or anesthesia nurse, the injection of the anesthetics is typically done by the surgeon, necessitating the drawing of the liquid into a sterile syringe.

Summary and conclusions

- The FA-SET is sterile and tolerated well by the patient. The forearm placement limits the volume of ischemic tissue to the minimum.
- Using the FA-SET for small hand/fingers procedures is logistically straight forward. It does not require capital equipment and calibration and the preparations for the case are simple (single item). As such, these cases can be performed in a procedure room with minimal support personnel, freeing the anesthesiologist for more complex cases.
- Subcutaneous infiltration of local anesthetics combined with the FA-SET is a safe, efficient and cost-effective way of optimizing the surgical field for short hand/fingers procedures. The addition of topical Emla® type cream can be applied in those patients where discomfort tolerance is low or unpredictable.
- Intravenous Regional Anesthesia with the FA-SET is safer than the traditional upper arm double cuff pneumatic tourniquet due to the fact that a much lower dose of local anesthetics

©2012 OHK Medical Devices – HemaClear®

is required in order to obtain surgical anesthesia. It is also safer because there is no risk of sudden loss of tourniquet pressure.

The use of the FA-SET for IVRA is also logistically superior over the traditional methods. The elimination of the pneumatic system with only a single item needed for the blocking of blood flow into the hand and seepage of anesthetics into central circulation. The early release of the tourniquet allows for a more efficient use of OR facility and personnel. The FA-SET presents a useful option for effecting wrist, hand and finger surgical anesthesia. In our experience, the safety margin is better than the traditional use of upper-arm pneumatic tourniquet and should be considered as first choice in most hand cases.

Bibliography

1) HemaClear® [homepage on the internet]. Haifa: OHK Medical Devices; c2010.
2) Inal S., et al. Comparison of two different anesthesia techniques for tourniquet pain with the use of forearm tourniquet. Iowa Orthop J. 2009; 29: 55–59.

©2012 OHK Medical Devices – HemaClear®

Appendix – Figures

Figure 1a

Figure 1b

Figure 1c

Figure 1d

Figure 1e

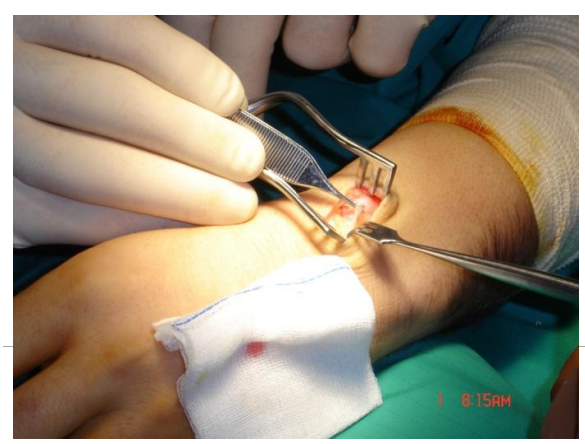

Figure 1f

Figure 1g

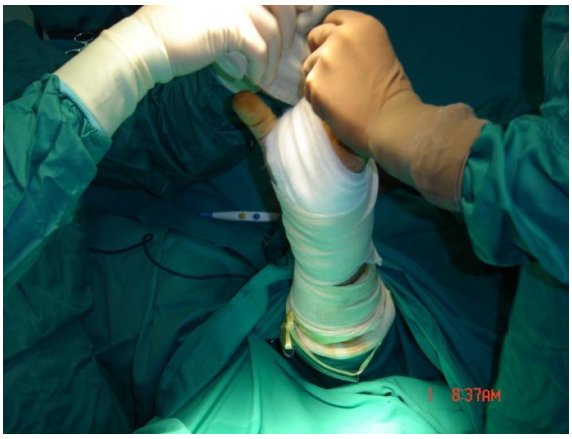

Figure 1h

Figure 1i

Figure 1j

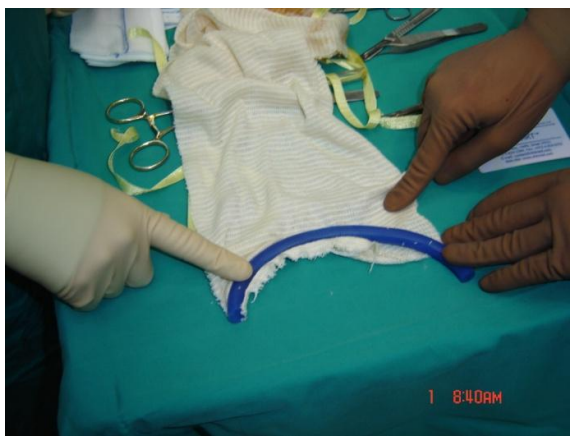

Figure 2

©2012 OHK Medical Devices – HemaClear®

Acta Orthop Scand 2002; 73 (1): 89–92

Exsanguination of lower limbs in healthy male subjects

Lars Blond[1], Klaus Kirketerp-Møller[2], Stig Sonne-Holm[1] and Jan L Madsen[3]

Departments of [1]Orthopedic Surgery and [2]Orthopedic Surgery, Gentofte Hospital, Copenhagen, [3]Clinical Physiology & Nuclear Medicine, Hvidovre Hospital, Denmark. E-mail: lars-blond@dadlnet.dk
Submitted 0007-11. Accepted 01-09-04

Acta Orthop Downloaded from informahealthcare.com by 180.250.182.51 on 05/20/14
For personal use only.

ABSTRACT – Gamma camera technique was used to assess the effectiveness of various exsanguination methods in 12 healthy male volunteers given an autologous injection of 99mTc-labeled erythrocytes. The methods used included elevation alone, Esmarch bandage, gauze bandage, and the Pomidor roll-cuff. The median times spent on use of these methods were: Esmarch 85 sec, gauze 104 sec, and Pomidor roll-cuff 18 sec. The various exsanguination methods caused a median percentage reduction in regional blood volume of the lower limbs: elevation 1/2 minute 45%, 1 minute 45%, 2 minutes 42%, 4 minutes 44%, 6 minutes 43%, 10 minutes 44%, Esmarch bandage 64%, gauze bandage 62%, and Pomidor roll-cuff 61%. No statistically significant differences were found between the elevation procedures. The external methods were more effective than elevation alone ($p < 0.001$).

■

Although exsanguination is a routine method in most orthopedic departments, only a few studies have dealt with this topic. Sir Lord Lister (1909) emphasized the importance of elevation and, after some observations, he recommended 4 minutes of elevation before applying of a tourniquet. However, DiStefano et al. (1974) in a plethysmographic study, noticed that a maximum reduction in blood volume after elevation seemed to occur even after 20 seconds with no noticeable change thereafter. Subsequently, in another plethysmographic study, Warren et al. (1992a) showed that optimal duration of elevation was 5 minutes. Apart from elevation, many methods for exsanguination have been suggested, all based on external compression (Esmarch 1873, Winnie and Ramamurthy 1970, Burchell and Stack 1973, Rhys-Davies and Stotter 1985, Colville and Small 1986, Löfqvist 1988).

The Esmarch bandage is generally thought to provide the most effective exsanguination (DiStefano et al. 1974, Rhys-Davies and Stotter 1985, Colville and Small 1986, Fancourt-Smith et al. 1990, Marshall et al. 1994). Previous studies on changes in local blood volumes in limbs have been based on plethysmographic methods . In this study, we used a new scintigraphic method to evaluate the effect of ordinary procedures for exsanguination of the lower limb before surgery (Blond and Madsen 2000).

Subjects and methods

12 healthy males subjects with a mean age of 29 (24–39) years, mean height of 179 (173–189) cm, and mean weights of 79 (61–91) kg participated in the study. All had normal blood pressure. The method for evaluating changes in blood volumes was based on the autologuous injection of 99mTc-radiolabeled erythrocytes and the use of a pneumatic tourniquet (Blond and Madsen 2000). The median radioactivity was 737 MBq. Each subject was placed supine on a horizontal inflexible bed with the lower leg aligned in a frame. Using gamma camera technique, a one-minute scintigram representing the lower leg and foot was taken before and after the exsanguination (Figure 1). To ensure reproducibility of the position of a region of interest (ROI) for subsequent integration of radioactivity, a 57Co source was placed 5 cm distal to the proximal demarcation of the right tibia. As ROI we used the smallest rectangle that included the

Copyright © Taylor & Francis *2002. ISSN 0001–6470. Printed in Sweden – all rights reserved.*

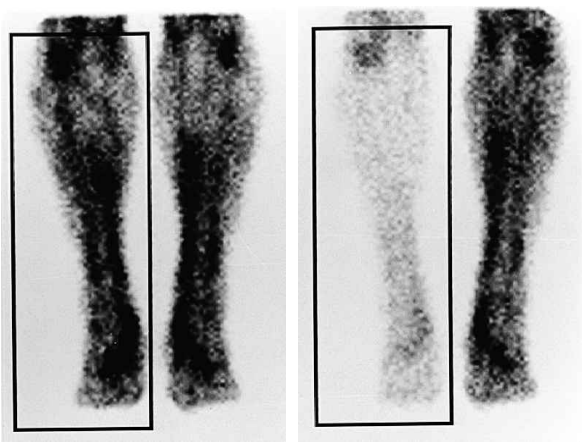

Figure 1. An example of a 1-minute scintigram of the lower limbs of a 25-year-old man obtained by 99mTc-radiolabeled erythrocytes showing the limbs from an anterior projection before and after an Esmarch exsanguination of the right limb. The frame represents the region of interest. The percentage reduction in blood volume, calculated from counts obtained before and after the exsanguination, was 61% here.

Acta Orthop Downloaded from informahealthcare.com by 180.250.182.51 on 05/20/14
For personal use only.

right foot and that part of the right crus distal to the marking. The same ROI was used for all measurements in each subject. The percentage reduction in blood volume was then calculated from counts obtained before and after the exsanguination.

The following exsanguination method were evaluated: elevation, Esmarch bandage, Pomidor roll-cuff (Pomidor AB, Varnamo, Sweden), and gauze bandage.

Elevation was done by the examiner who raised the limb to 60 degrees for half a minute, 1 minute, 2 minutes, 4 minutes, 6 minutes, and 10 minutes. The external methods were done with the limb raised to 60 degrees. After exsanguination, a 14 cm wide pneumatic cuff mounted on the thigh was inflated in a few seconds to 300 mm Hg. The pneumatic cuff was omitted when the Pomidor roll-cuff was used, because it also acts as a tourniquet when kept in place with two rubber wedges. The roll-cuff was used in accord with the recommendations of the manufacturer—i.e., the cuff size was chosen in relation to the circumference of the thigh and the cuff was inflated to a pressure of 120 mm Hg before use. Both the Esmarch and gauze bandages were applied using half of the width overlap. With the cuff inflated, the limb was realigned on the gamma camera and a one-minute scintigram was taken. The tourniquet was then deflated and in order to ensure that the phase of hyperemia was over, 12 one-minute scintigrams were taken before the next exsanguination. All 9 types of exsanguinations done in the 12 subjects were performed in random order, using the drawing lot principle. The time taken to apply and remove the external methods was noted.

Statistics

Friedman's test was used to compare the median values of the various exsanguination methods. A value of $p < 0.05$ was considered significant in all tests. Two-tailed tests were used. The data were analyzed with STATISTICA software package.

The local committee on ethics in Copenhagen approved the study. The subjects gave their written informed consent.

Results

The hyperemia phase lasted less than s4 minutes (median and quartiles 1.003 (0.963–1.057)) versus the opposite limb.

The median times for use of the exsanguination methods were: Esmarch 85 (81–94) sec, gauze 104 (90–107) sec, and Pomidor roll-cuff 18 (15–21) sec. The Pomidor roll-cuff took less time than the Esmarch bandage and gauze bandage ($p = 0.009$).

The various exsanguination methods resulted in the following median percentage reductions in regional blood volume in the lower limbs: elevation 1/2 minute 45%, Esmarch bandage 64%, gauze bandage 62%, and Pomidor roll-cuff 61%. For more details, see Figure 2.

As regards the results of elevation alone, no significant differences were found between the various durations of elevation ($p = 0.2$). All the external methods were more effective than half a minute of elevation ($p < 0.001$). No significant differences were found among the Esmarch bandage, gauze bandage and the Pomidor roll-cuff.

Discussion

The method we used with autologous injection of 99mTc-radiolabeled erythrocytes evaluated changes in blood volume in limbs (coefficient of variation: within subjects 6%, between subjects 14%) more

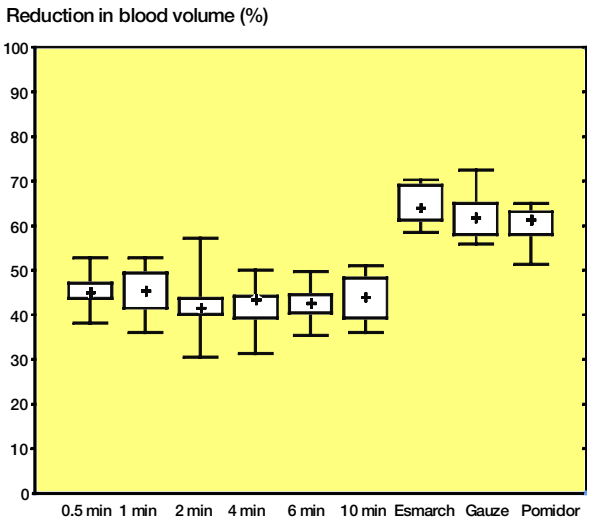

Figure 2. Results of various exsanguination methods in 12 subjects expressed as median (+), range and interquartil (box) percentage reduction in blood volume calculated from counts before and after the exsanguination.

precisely than other plethysmographic methods (Blond and Madsen 2000). It is also a more physiological approach for exsanguination.

We found that external methods induce more effective exsanguination than elevation alone, as reported by others (DiStefano et al. 1974, Rhys-Davies and Stotter 1985, Fancourt-Smith et al. 1990). As regards exsanguination with elevation alone, we found no significant difference between half a minute of elevation and a longer elevation time. This does not accord with Lister's (1909) and by Warren et al.'s (1992a, b) findings but is in the line with the observation of DiStefano et al. (1974) and Notcutt (1978). The discrepancy between ours and those of Warren et al. (1992a, b) may be methodological. Warren et al. (1992a, b) used a strain gauge plethysmographic method that indirectly estimates changes in blood volume since it measures only changes in the circumference of a limb. We believe that some of the interstitial fluid is drained when a limb is raised for more than a few seconds, and such drainage is probably the reason why the circumference of the leg continues to diminish for more than 5 minutes. The problem of stasis, which has previously been shown to occur when the lower limb is elevated to 90 degrees as a result of obstruction in the venous outflow (Warren et al. 1992b), does not seem to occur when using 60 degrees of elevation as in this study.

The oldest subject in our study was 39. To our knowledge no study has addressed the dynamic changes of the venous system in relation to age, gender or vascular diseases. However, it seems likely that some changes can occur, but how this may influence the exsanguination is unclear. Our subjects did not receive any anesthetic, which is common with the use of a bloodless field. We do not know whether this affected our findings.

We regret not to have included an elevation time shorter than half a minute in our study design, because it remains uncertain whether even shorter elevation times are sufficient for optimum exsanguination.

The fact that half a minute of elevation for exsanguination is as effective as longer elevation should change the practice in operating rooms when using elevation alone for exsanguination. A common practice is to inflate the tourniquet immediately after use of antiseptics, since the limb has just been raised for several minutes and has been regarded as optimally exsanguinated. We have learned that this is wrong and in order to minimize the tourniquet time, we believe that the inflation of the cuff should be postponed until the surgical cover has been applied and the surgeon is ready to exsanguinate. If a more effective exsanguination is required one of the external methods can also be used. The times taken for the various external methods differed. More than one minute was spent on putting on the Esmarch bandage, whereas the Pomidor roll-cuff may be putting on very quickly. The Esmarch and gauze bandages are not only time-consuming (O'Hara et al. 1991), but should not be used in the event of a fracture; they can damage the skin, because they induce torsional andlongitudinal shearing stresses (Hallet 1983, Marshall et al. 1994). However, none of the young healthy subjects in our experiment complained of pain when we used these bandages. Furthermore autoclaving the Esmarch bandage is troublesome (Asirvatham et al. 1990, O'Hara et al. 1991). In our experience, the Pomidor roll-cuff is easy to handle and gives fast, good, and constant exsanguination. It also allows placement of the surgical cover more proximal than normal, since the cuff is sterile, gives more freedom to move the leg and see the alignment. However, it has the disadvantage that when reperfusion is needed during an operation, the cuff must pass the operating field.

Acta Orthop Downloaded from informahealthcare.com by 180.250.182.51 on 05/20/14
For personal use only.

This study was financially supported by the "Danish Hospital Foundation for Medical Research. Region of Copenhagen, the Faroe Islands and Greenland".

Asirvatham R, Watts H G, Ware B J, Rooney R J. The reliability of sterilising Esmarch bandages. J Bone Joint Surg (Br) 1990; 72 (5): 924.

Blond L, Madsen J L. Scintigraphic method for evaluating reductions in local blood volumes in human extremities. Scand J Clin Lab Invest 2000; 60 (5): 333-9.

Burchell G, Stack G. Exsanguination of the arm and hand. Hand 1973; 5 (2):124-6.

Colville J, Small J O. Exsanguination of the upper limb in hand surgery. Comparison of four methods. J Hand Surg (Br) 1986; 11 (3): 469-70.

DiStefano V, Nixon J E, Stone R H. Bioelectic impedance plethysmography as an investigative tool in orthopaedic surgery–a comparative study of limb exsanguination techniques. Clin Orthop 1974; 99: 203-6.

Esmarch J F A von. Ueber Künstliche Blutleere Bei Operationen. Sammlung Klinisher Vortäge in Verbindung Mit Deutschen Klinikern. Chirurgie 1873; 19 (58): 373.

Fancourt-Smith P F, McEwen J A, Warriner C B, Moore R. Comparison of two methods of limb exsanguination. Can J Anaesth 1990; 37 (4): 55.

Hallet J. Use of the tourniquet in hand surgery. In: Rob and Smith's operative surgery. 4th ed. (Eds. Birch R, Brooks D). Butterworths, London 1983.

Lister J. Collected papers. Oxford: at the Clarendon Press 1909; 1: 176-85.

Löfqvist J. Chirugie in Blutleere Mit Rollmanchetten. Chirurg 1988; 59: 853-4.

Marshall P D, Patil M, Fairclough J A. Should Esmarch bandages be used for exsanguination in knee arthroscopy and knee replacement surgery? A prospective trial of Esmarch exsanguination versus simple elevation. J R Coll Surg Edinb 1994; 39 (3):189-90.

Notcutt W G. Limb exsanguination for Bier's block. Anaesthesia 1978; 33 (7): 652.

O'Hara J N, Coleman M, Hutton R M. A simple and effective method of sterilizing Esmarch bandages. J Arthroplasty 1991; 6 (2): 95-6.

Rhys-Davies N C, Stotter A T. The Rhys-Davies exsanguinator. Ann R Coll Surg Engl 1985; 67 (3): 193-5.

Warren P J, Hardiman P J, Woolf V J. Limb exsanguination. I. The arm: effect of angle of elevation and arterial compression. Ann R Coll Surg Engl 1992a; 74 (5): 320-2.

Warren P J, Hardiman P J, Woolf V J. Limb exsanguination. II. The leg: effect of angle of elevation. Ann R Coll Surg Engl 1992b; 74 (5): 323-5.

Winnie A P, Ramamurthy S. Pneumatic exsanguination for intravenous regional anesthesia. Anesthesiology 1970; 33 (6): 664-5.

Acta Orthop Downloaded from informahealthcare.com by 180.250.182.51 on 05/20/14
For personal use only.

View publication stats

The Journal of Arthroplasty 36 (2021) S209–S214

Contents lists available at ScienceDirect

The Journal of Arthroplasty

journal homepage: www.arthroplastyjournal.org

Primary Knee

Tourniquet Use Improves Cement Penetration and Reduces Radiolucent Line Progression at 5 Years After Total Knee Arthroplasty

Vishal Hegde, MD [a, b], Daniel N. Bracey, MD, PhD [a, c], Roseann M. Johnson, BS, CCRP [a], Douglas A. Dennis, MD [a, d, e, f], Jason M. Jennings, MD, DPT [a, d, *]

[a] Colorado Joint Replacement, Denver, CO
[b] Department of Orthopaedic Surgery, The Johns Hopkins University, Baltimore, MD
[c] Department of Orthopaedic Surgery, University of North Carolina, Chapel Hill, NC
[d] Department of Mechanical and Materials Engineering, University of Denver, Denver, CO
[e] Department of Orthopaedics, University of Colorado School of Medicine, Denver, CO
[f] Department of Biomedical Engineering, University of Tennessee, Knoxville, TN

ARTICLE INFO

Article history:
Received 16 November 2020
Received in revised form
14 December 2020
Accepted 28 December 2020
Available online 5 January 2021

Keywords:
tourniquet
cement penetration
total knee arthroplasty
aseptic revision
radiolucent lines

ABSTRACT

Background: Although the effect of tourniquet use during total knee arthroplasty (TKA) on functional outcomes is controversial, there are little data examining cement penetration and implant stability. This study examines the effect of tourniquet use on cement penetration and radiolucent line (RLL) progression.

Methods: Patients undergoing primary total knee arthroplasty with a single surgeon, implant, and cement with minimum 5-year follow-up were retrospectively reviewed. Tourniquet use was defined as 30 minutes minimum, while no tourniquet was 0 minutes. Patients were 1:1 matched (n = 61 per group) by age (±5), gender, body mass index (±5), and follow-up (±2 years). Cement penetration and RLL were measured on the tibia at 6 weeks, and RLL at 1, 2, and 5 years postoperatively using the Knee Society Radiographic Evaluation System.

Results: Cement penetration was significantly increased in the tourniquet group in anterior-posterior zones 1 (2.16 vs 1.03 mm, $P < .0005$), 2 (2.23 vs 1.51 mm, $P < .0005$), and 5 (8.56 vs 6.3 mm, $P = .009$), and lateral zones 1 (2.89 vs 2.17 mm, $P < .0005$), 2 (2.86 vs 2.12 mm, $P < .0005$), 3P (3.99 vs 3.5 mm, $P = .039$), and 5 (8.18 vs 5.93 mm, $P = .006$). Cumulative cement penetration averaged 34.48 vs 43.33 mm in the tourniquet group ($P < .005$). Progression of RLL >2 mm was observed in 27.8% (17/61) vs 11.4% (7/61) of patients in the tourniquet group ($P < .005$). There were 2 failures for aseptic tibial loosening in the no tourniquet group.

Conclusion: Tourniquet use improves cement penetration and reduces RLL progression. Dryer surfaces during cementation may improve penetration, resulting in superior initial fixation strength and potentially reducing the long-term risk of aseptic loosening.

© 2021 Elsevier Inc. All rights reserved.

The use of a tourniquet during total knee arthroplasty (TKA) and its effect on pain and functional recovery remains controversial [1–7]. One purported advantage of tourniquet use is the improved surgical field visualization due to a reduction in bleeding and clot debris encountered [1]. This is also thought to be advantageous in the cementation of TKA components, as there is currently a plethora of evidence that contamination from fat or blood contents can impact cement penetration into trabecular bone and reduce adhesive/tensile strength by up to 50% [8–13].

To minimize the risk of aseptic loosening of the tibial component, appropriate cement technique with a 3-mm to 4-mm cement mantle has been deemed critical to ensure adequate bone-cement interface strength to minimize micromotion for long-term implant survival [14–17]. This has led some surgeons to use a tourniquet

One or more of the authors of this paper have disclosed potential or pertinent conflicts of interest, which may include receipt of payment, either direct or indirect, institutional support, or association with an entity in the biomedical field which may be perceived to have potential conflict of interest with this work. For full disclosure statements refer to https://doi.org/10.1016/j.arth.2020.12.048.

* Reprint requests: Jason M. Jennings, MD, DPT, Colorado Joint Replacement, 2535 S Downing Street, Suite 100, Denver, CO 80210.

https://doi.org/10.1016/j.arth.2020.12.048
0883-5403/© 2021 Elsevier Inc. All rights reserved.

only during cementation, to utilize the advantages of tourniquet use during bone preparation while minimizing the potentially deleterious effects of long-term tourniquet use, such as diminished quadriceps strength [4]. Current evidence evaluating the difference in cement penetration with and without the use of a tourniquet in TKA is conflicting, and limited by low patient numbers and short-term radiographic and clinical follow-up [18–22]. In addition, no studies to date have evaluated differences in implant survival.

The aim of this study is to determine (1) the effect of tourniquet use on cement penetration under the tibial prosthesis in TKA and (2) if differences in cement penetration impact implant stability by examining radiolucent line (RLL) progression and implant survival. Our hypothesis is that by enhancing bone preparation, tourniquet use will improve cement penetration. This will subsequently increase implant stability, resulting in a reduction in RLL progression and an improvement in implant survival.

Materials and Methods

Study Design and Participants

This study was approved by our Institutional Review Board prior to initiation. The study period was from September 2011 to October 2015. We utilized our institution's prospective, longitudinally maintained total joint arthroplasty database to retrospectively identify all patients who underwent a cemented, fixed bearing, posterior-stabilized unilateral primary TKA by a single surgeon with a single implant (Triathlon; Stryker Orthopedics Inc, Mahwah, NJ). The surgeon used an extension-first gap balancing technique with computer navigation (Stryker OrthoMap Express Knee Navigation System; Stryker Orthopedics Inc). Patients with a minimum 5-year follow-up duration were included. Demographic, preoperative, perioperative, and postoperative clinical and radiographic data were collected from the database.

Patients were categorized as having undergone TKA either with a tourniquet or without a tourniquet. The operating surgeon switched from using a tourniquet to not using a tourniquet for all primary TKAs during the study period. Tourniquet use was defined as a minimum of 30 minutes of inflation, while no tourniquet was 0 minutes. Patients with documented tourniquet use between 1 and 29 minutes (n = 19) were excluded from this study, as the tourniquet was deemed to have been inflated after skin incision. Patients requiring augmentation, stem extension, or increased constraint as a part of their TKA were also excluded. Patients from each group were then matched 1:1 by age (±5 years), gender, body mass index (BMI) (±5), and duration of follow-up (±2 years), resulting in 61 patients matched in each group.

Surgical Technique

If used, a pneumatic tourniquet was applied before surgery at the level of the proximal thigh and inflated to 250 mm Hg prior to skin incision using an esmarch bandage for exsanguination. The tourniquet remained inflated until after cementation. For all patients, the blood pressure was maintained relatively hypotensive as long as there were no contraindications, otherwise the patient was maintained normotensive. A medial parapatellar approach was used for all cases. Simplex P bone cement with tobramycin 80 g (2 packets) (Stryker Orthopedics Inc) was used for all patients as a single mix. A fourth-generation cementation technique with pulsatile lavage, vacuum mixing, and cement gun pressurization was utilized. Bony surfaces were dried prior to cementation. Both the implant and bone surfaces were coated with cement prior to implantation. The tibial component was implanted first, followed by the femoral component. The polyethylene was then inserted, and the knee was brought into extension and the patella was implanted. Motion was limited until the cement was cured in all cases prior to arthrotomy closure.

Radiological Evaluation

At the preoperative and 6-week postoperative visit, standing long leg films of the bilateral lower extremities were obtained. These films were used to measure the preoperative and postoperative hip-knee-ankle (HKA) axis, as well as the postoperative tibial component axis (TCA), using the institution's Picture Archiving and Communication System (PACS) Synapse (Fujifilm USA, Lemoyne, PA). The 6-week postoperative anterior-posterior (AP) and lateral view knee X-rays were used to measure tibial component cement penetration and RLL using the Knee Society Radiographic Evaluation System (KSRES) (Fig. 1) [23]. The 1, 2, and 5-year postoperative X-rays were also measured for RLL. Based on prior literature, progression was defined as an increase in the length of the RLL of more than 2 mm in subsequent X-rays [24]. Two authors (V.H., D.N.B.), blinded to the use of tourniquet, each independently evaluated all X-rays to measure cement mantle thickness and RLL length at each time point. To account for magnification error, the radiographic dimensions of the prosthesis were adjusted to match the true prosthesis dimensions. After inter-rater reliability was determined, the measurements from both authors were averaged for further analysis. In addition, the cement mantle and RLL measurements from each zone were summated to produce a cumulative measurement of the cement mantle and RLL size about the tibial prosthesis.

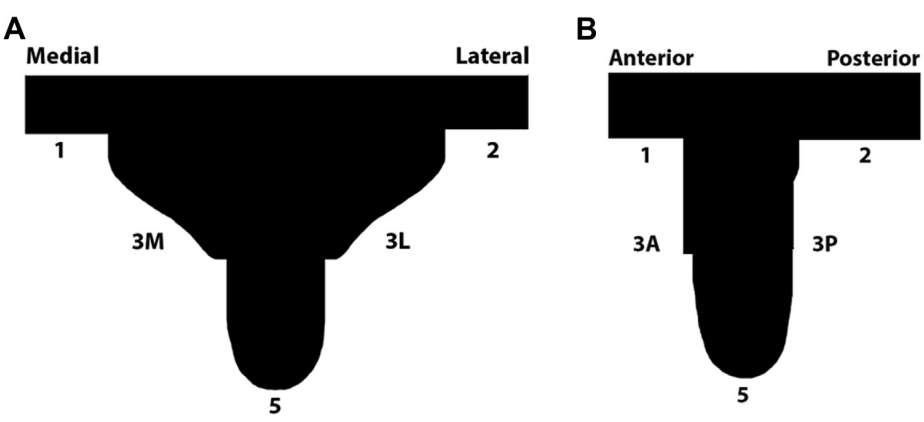

Fig. 1. (A) Anterior-posterior view of Knee Society Radiographic Evaluation System zones and (B) lateral view of Knee Society Radiographic Evaluation System zones.

Statistical Analysis

Categorical variables were compared using Fisher's exact test or Pearson's chi-squared test, whereas continuous variables were analyzed using the Mann-Whitney *U*-test or Student's *t*-test. Interrater reliability was evaluated using Cronbach's alpha and percentage agreement. Standardized mean differences were estimated for all the baseline covariates before and after matching to assess pre-match imbalance and post-match balance. The comparative risks of failure-free survival were compared using the log-rank test in a matched sample. All statistical analyses were performed using SPSS, version 26.0 (SPSS Inc, Chicago, IL).

Results

The study sample included 122 patients (61 per group) with a mean age of 63.65 ± 7.14 years (range 47-79). There was no difference in age, gender, BMI, or length of follow-up between groups (Table 1). There was no difference in preoperative HKA (2.42° vs 3.75° varus, $P = .27$), postoperative HKA (0.54° vs 1.21° varus, $P = .06$), or postoperative TCA (0.68° vs 0.5° valgus, $P = .43$).

The Cronbach alpha values indicated that the 2 observers' judgments corresponded very closely (Table 2). Consequently, the 2 raters' ratings were averaged together, and these average values were compared between the tourniquet and no tourniquet groups. Cement penetration was significantly increased in the tourniquet group in AP zones 1 (2.16 vs 1.03 mm, $P < .005$), 2 (2.23 vs 1.51 mm, $P < .005$), and 5 (8.56 vs 6.36 mm, $P = .01$), and lateral zones 1 (2.89 vs 2.17 mm, $P < .005$), 2 (2.86 vs 2.12 mm, $P < .005$), 3P (3.99 vs 3.5 mm, $P = .04$), and 5 (8.18 vs 5.93 mm, $P = .01$) (Table 3). There was no difference in AP zones 3M and 3L, or lateral zone 3A. The cumulative cement penetration was also significantly different, averaging 43.33 mm in the tourniquet vs 34.48 mm in the no tourniquet group ($P < .005$).

When determining interobserver reliability for RLL, since instances of RLL were so rare, presence or absence of RLL, rather than the actual measurement, was used as the outcome measure. The percentage of times the 2 raters agreed was used as the measure of reliability. The 2 raters agreed on the presence or absence of RLL in each zone for every X-ray except one (4879/4880, 99.9% agreement). Consequently, the 2 raters' RLL size measurements were averaged together, and these average values were compared between the tourniquet and no tourniquet groups. There was a significant difference in RLL at 5 years in AP zone 1 (0.33 vs 1.53 mm, $P = .006$) (Table 4). There was no difference in RLL at 5 years in any other zone. The cumulative RLL measurement at 5 years was significantly higher in the no tourniquet group vs the tourniquet group (5.58 vs 0.79 mm, $P = .04$). Progression of RLL was observed in 27.8% (17/61) of patients in the no tourniquet group vs 11.4% (7/61) of patients in the tourniquet group ($P < .005$).

There was no difference in preoperative or postoperative Knee Society Scores between the 2 groups (Table 2). There were 2 failures for aseptic tibial loosening requiring revision in the no tourniquet group vs 0 in the tourniquet group ($P = .15$) (Fig. 2). These failures occurred at 25 and 58 months postoperatively. There were no other complications or revision surgeries documented for both groups. Five-year survival rates for the 2 groups were thus 100% (61/61) for the tourniquet group vs 96.7% (59/61) for the no tourniquet group.

Table 1
Clinical and Radiographic Outcomes.

	Tourniquet	No Tourniquet	*P* Value
Age	63.64 ± 7.02[a]	63.66 ± 7.26[a]	.99
Gender	37 (60.7%) male 24 (34.3%) female	37 (60.7%) male 24 (34.3%) female	
BMI	30.43 ± 4.81[a]	29.48 ± 5.15[a]	.30
Length of follow-up (mo)	64 ± 12.6 (60-94)[b]	62 ± 6.5 (25-81)[b]	.26
Preop HKA angle	2.42 ± 6.79[a]	3.75 ± 6.36[a]	.27
Postop HKA angle	0.54 ± 2.09[a]	1.21 ± 1.86[a]	.06
Postop TCA angle	−0.68 ± 1.31[a]	−0.5 ± 1.16[a]	.43
Preop ROM	118 ± 19.3[a]	114.5 ± 17.3[a]	.292
Preop Function	62.9 ± 17.8[a]	64.7 ± 17.3[a]	.574
Preop Knee Score	49.4 ± 13.2[a]	49.2 ± 16.4[a]	.964
Postop ROM	126.1 ± 9.59[a]	124.87 ± 8.5[a]	.458
Postop Function	81.8 ± 24.9[a]	82.4 ± 22.1[a]	.893
Postop Knee Score	88.7 ± 15.1[a]	88.4 ± 15.9[a]	.915

BMI, body mass index; HKA, hip-knee-ankle; ROM, range of motion; TCA, tibial component axis.
[a] Values are presented as mean ± standard deviation.
[b] Values are presented as mean ± standard deviation (range).

Table 2
Interobserver Reliability of Cement Penetration Measurements.

View	KSRES Zone	Cronbach's Alpha	*P* Value
AP	1	0.939	<.005
	2	0.904	<.005
	3M	0.960	<.005
	3L	0.970	<.005
	5	0.996	<.005
Lateral	1	0.952	<.005
	2	0.922	<.005
	3A	0.919	<.005
	3P	0.929	<.005
	5	0.995	<.005

AP, anterior-posterior; KSRES, Knee Society Radiographic Evaluation System.

Discussion

To our knowledge, this is the first study that examines differences in cement penetration and mid-term implant stability (5-year minimum follow-up) of patients undergoing routine elective primary TKA with or without the use of a tourniquet. Cement penetration was significantly increased in the tourniquet group, with a cumulative difference of approximately 8.85 mm throughout all KSRES zones. Patients undergoing TKA without a tourniquet also had significantly increased RLL size and progression at mid-term follow-up, indicating a higher risk of decreased implant stability. There were 2 failures requiring revision for aseptic tibial loosening in the no tourniquet group, compared to 0 in the tourniquet group, although this difference was not significant.

The use of a tourniquet during TKA remains controversial due to debates over potential differences in perioperative blood loss, complications, postoperative quadriceps dysfunction, functional outcomes, and pain [1–7]. A critical component of this debate remains the effect of tourniquet use on the quality of the cement

Table 3
Cement Penetration in Each KSRES Zone at 6 wk Postoperatively.

View	KSRES Zone	Tourniquet	No Tourniquet	*P* Value
AP	1	2.16 ± 0.84	1.03 ± 0.93	<.005
	2	2.23 ± 0.86	1.51 ± 0.84	<.005
	3M	4.18 ± 1.38	4.31 ± 1.67	.66
	3L	4.48 ± 1.76	3.95 ± 1.52	.07
	5	8.56 ± 5.12	6.36 ± 4.01	.01
Lateral	1	2.89 ± 0.91	2.17 ± 0.79	<.005
	2	2.86 ± 0.99	2.12 ± 0.9	<.005
	3A	3.8 ± 1.07	3.6 ± 1.19	.30
	3P	3.99 ± 1.49	3.5 ± 1.19	.04
	5	8.18 ± 5.18	5.93 ± 3.57	.01
Cumulative		43.33 ± 11.35	34.48 ± 7.87	<.005

Values are in millimeters and presented as mean ± standard deviation.
AP, anterior-posterior; KSRES, Knee Society Radiographic Evaluation System.

Table 4
RLL Measurements in Each KSRES Zone at 5 y Postoperatively.

View	KSRES Zone	Tourniquet	No Tourniquet	*P* Value
AP	1	0.33 ± 1.56	1.53 ± 3.29	.006
	2	0.19 ± 1.09	0.50 ± 1.70	.11
	3M	0 ± 0	1.00 ± 6.00	.16
	3L	0 ± 0	1.00 ± 6.00	.16
	5	0 ± 0	0 ± 1.00	.16
Lateral	1	0.28 ± 1.08	0.85 ± 2.78	.07
	2	0 ± 0	0.50 ± 3.31	.12
	3A	0 ± 0	0.53 ± 4.12	.16
	3P	0 ± 0	0 ± 0	1
	5	0 ± 0	0 ± 0	1
Cumulative		0.79 ± 2.28	5.58 ± 21.78	.04

Values are in millimeters and presented as mean ± standard deviation.
AP, anterior-posterior; KSRES, Knee Society Radiographic Evaluation System; RLL, radiolucent line.

mantle, because it is well documented that TKA revisions for aseptic loosening may be secondary to inadequate initial cement penetration [25]. Prior literature has clearly established the essential role bone surface preparation has on initial fixation strength of cemented TKA components, in particular the use of pulsatile lavage and pressure injection [26–28]. This is due to the fact that cement contamination with fat and blood contents alters cement viscosity and reduces penetration into trabecular bone [9–11]. It remains unclear if good cement technique and hyperflexion of the knee to control bleeding without a tourniquet can compensate for the reduced blood contamination gained with the use of a tourniquet, particularly since placing the knee in hyperflexion following cementation risks tibial tray motion during curing of cement which can have adverse effects on long-term fixation [29].

Prior studies with smaller patient cohorts and shorter-term follow-up have attempted to examine the effect of tourniquet use on the cement mantle under the tibia. Jawhar et al [20] did not find a significant difference in the cumulative cement mantle between the 2 groups, with the tourniquet group's cumulative cement mantle being 1.9 mm greater than the no tourniquet group's cement mantle. Pfitzner et al and Touzopoulos et al both found a significantly increased cement mantle in the tourniquet group, but the cumulative difference was only 1.2 mm for both studies, which is of questionable clinical significance [21,22]. In contrast, our study found a significant difference in cement penetration, with a cumulative difference of 8.85 mm. The larger difference measured in our study may be due to differences in cement technique, type of cement used, and methodology used to measure the cement mantle. In addition, the average peripheral cement mantle in KSRES zones 1 and 2 on both the AP and lateral views in this study were much closer to the recommended 3-4 mm for optimal implant fixation in the tourniquet group compared to the no tourniquet group [15–17]. A prior biomechanical study indicated that a 1-mm cement mantle led to significant micromotion, while a 3-mm cement mantle led to excellent stability, indicating that the difference in the peripheral cement mantle of 0.5 mm to 1 mm in each zone may be of clinical significance [30].

Aside from the size of the cement mantle, there is a paucity of data available concerning the effect of tourniquet use on implant stability and survival in TKA. There have been 2 prior radiostereometric analyses that did not find a difference between the 2 groups [31,32]. However, as Ledin et al acknowledge in their study, the use of RSA in cemented TKA is mostly based on theoretical reasoning and it is unclear if it is predictive of implant survival, a major limitation of these studies.

A more established method of evaluating implant stability is the presence of RLL on postoperative X-rays. Vandenbussche et al reported no differences in radiolucency between the tourniquet vs no tourniquet groups at 3-month follow-up, but Touzopoulos et al reported an increased number of patients with RLL and cumulative width of RLL in the no tourniquet group of 5.55 mm at 3-year follow-up [21,33]. At longer term 5-year follow-up, our study also found a significantly larger cumulative RLL size of 4.79 mm, comparable to Touzopoulos et al., as well as an increased rate of RLL progression in the no tourniquet group. The difference in progressive RLL in particular is important, as this type of RLL at the cement-bone interface has been previously correlated with bone loss, component migration, and implant loosening [28,34]. Although the difference in implant survival was not significant in this study, potentially due to insufficient patient numbers and follow-up to appropriately evaluate this endpoint, RLL progression data may suggest that longer term follow-up could lead to more cases of

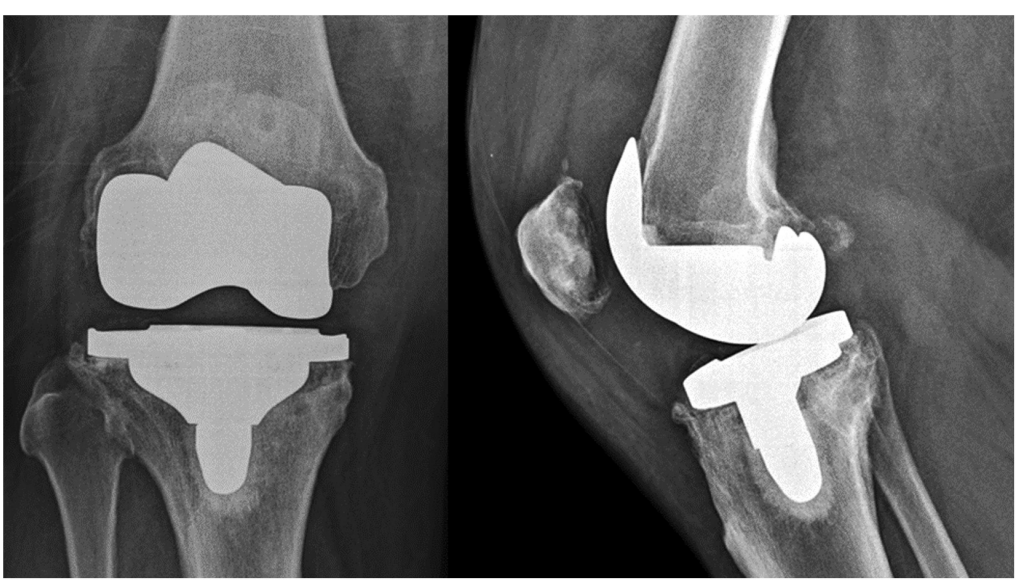

Fig. 2. Anterior-posterior and lateral view of patient in no tourniquet group demonstrating significant radiolucent line formation indicative of tibial component loosening.

aseptic tibial component loosening requiring revision in the no tourniquet group. Our institution will continue to follow these patients to determine if this becomes a long-term issue.

This study has several limitations. As a comparative retrospective analysis, it may be prone to bias compared to a prospective, randomized controlled trial, although significant effort was put into the selection of strong matching criteria for the 2 groups to minimize this as much as possible. This study involved a single surgeon, using a single implant and single cement type, ensuring a similar cement technique and consistency for all patients across both groups. In addition, the surgeon switched from using a tourniquet to no tourniquet during the study period for all routine primary TKAs, reducing potential selection bias as a part of the study, and ensuring familiarity with appropriate technique for both approaches. In spite of this, there may have been a learning curve when transitioning from cementation with a tourniquet to without. This learning curve may have increased the bias toward failure in the no tourniquet group. Ideally, this study would have had a larger sample size in each group, but in an attempt to strengthen the study by limiting confounding variables (ie, different implants, surgeon technique, cement type) as much as possible, the cohort size was reduced. The cohorts were also limited to patients who underwent TKA without the use of a tourniquet and those patients who had tourniquet utilization for at least 30 minutes. A cohort with limited tourniquet use (ie, use for cementation only) was not included for comparison secondary to insufficient numbers within the constraints of this study. The surgeon in this study used computer navigation for all TKAs in an attempt to more accurately reproduce the mechanical axis postoperatively. Many surgeons may not use computer navigation, and this may limit the generalizability of the results. Interestingly, the difference in postoperative HKA angle between groups approached significance, although both were within 3° of neutral and there was no difference in postoperative TCA. Although this may have played a role in the difference in RLL progression and aseptic loosening, restoration of the mechanical axis to within 3° of neutral is considered acceptable coronal alignment to protect against mid-term to long-term aseptic loosening in the literature, and the authors do not believe this had a significant effect on the results [35].

Cement penetration was only measured on the tibial component in this study. A decision was made not to measure cement penetration on the femoral component due to the potential inaccuracy caused by overlay of the medial and lateral femoral condyles, as well as the presence of the intercondylar box due to the posterior-stabilized design analyzed, making it difficult to measure cement mantle thickness at certain parts of the femur. The patella was also not examined due to difficulty obtaining accurate views of the patella on the merchant X-ray views. We concede that X-ray angle and variability of radiographic technique may have influenced even the tibial component measurements. Our practice is a total hip and knee arthroplasty institution, and we feel the repetition and radiographic protocol utilized at our facility limited this variable. A computed tomography scan or RSA analysis would likely be more accurate methods of evaluating the cement mantle to precisely identify the presence and progression of RLL over time. These methods may have identified more differences between the 2 groups. Bone density, which can impact cement penetration, was also not measured. An attempt was made to address this by ensuring matching by age, gender, and BMI between the cohorts. Despite these limitations we feel this is a valuable contribution to the growing knowledge of cement penetration as it relates to tourniquet utilization.

This study supports the conclusion that tourniquet use improves the cement mantle and subsequently may improve mid-term implant stability after cemented TKA. Although there was no difference in revision rate due to aseptic loosening of the tibial component, the length of follow-up and number of patients included in the study may not be sufficient to appropriately evaluate this outcome. At the author's institution, the tourniquet is inflated only during cementation (typically 8-12 minutes) to obtain clean bony surfaces while minimizing the potentially deleterious effects of tourniquet use, such as diminished quadriceps strength [4]. Further study is required to examine the effect of this limited tourniquet use on cement penetration and implant stability, as this technique is an area of interest in our practice and has been adopted by many surgeons in recent years. In addition, higher quality, prospective long-term studies are necessary to further evaluate the risk of aseptic loosening requiring revision in patients undergoing cemented TKA with and without a tourniquet.

References

[1] Zhang W, Li N, Chen S, Tan Y, Al-Aidaros M, Chen L. The effects of a tourniquet used in total knee arthroplasty: a meta-analysis. J Orthop Surg Res 2014;9:1–9.
[2] Liu D, Graham D, Gillies K, Gillies RM. Effects of tourniquet use on quadriceps function and pain in total knee arthroplasty. Knee Surg Relat Res 2014;26:207–13.
[3] Mizner RL, Petterson SC, Stevens JE, Vandenborne K, Snyder-Mackler L. Early quadriceps strength loss after total knee arthroplasty: the contributions of muscle atrophy and failure of voluntary muscle activation. J Bone Joint Surg Am 2005;87:1047–53.
[4] Dennis DA, Kittelson AJ, Yang CC, Miner TM, Kim RH, Stevens-Lapsley JE. Does tourniquet use in TKA affect recovery of lower extremity strength and function? A randomized trial. Clin Orthop Relat Res 2016;464:69–77.
[5] Goel R, Rondon AJ, Sydnor K, Blevins K, O'Malley M, Purtill JJ, et al. Tourniquet use does not affect functional outcomes or pain after total knee arthroplasty: a prospective, double-blinded, randomized controlled trial. J Bone Joint Surg Am 2019;101:1821–8.
[6] Alcelik I, Pollock RD, Sukeik M, Bettany-Saltikov J, Armstrong PM, Fismer P. A comparison of outcomes with and without a tourniquet in total knee arthroplasty. A systematic review and meta-analysis of randomized controlled trials. J Arthroplasty 2012;27:331–40.
[7] Rathod P, Deshmukh A, Robinson J, Greiz M, Ranawat A, Rodriguez J. Does tourniquet time in primary total knee arthroplasty influence clinical recovery? J Knee Surg 2015;28:335–42.
[8] Banwart JC, McQueen DA, Friis EA, Graber CD. Negative pressure intrusion cementing technique for total knee arthroplasty. J Arthroplasty 2000;15:360–7.
[9] Majkowski RS, Bannister GC, Miles AW. The effect of bleeding on the cement-bone interface: an experimental study. Clin Orthop Relat Res 1994:293–7.
[10] Juliusson R, Flivik G, Nilsson J, Ryd L, Onnerfalt R. Circulating blood diminishes cement penetration into cancellous bone. Acta Orthop Scand 1995;66:234–8.
[11] Breusch S, Heisel C, Müller J, Borchers T, Mau H. Influence of cement viscosity on cement interdigitation and venous fat content under in vivo conditions: a bilateral study of 13 sheep. Acta Orthop Scand 2002;73:409–15.
[12] Gruen TA, Markolf KL, Amstutz HC. Effects of laminations and blood entrapment on the strength of acrylic bone cement. Clin Orthop Relat Res 1976:250–5.
[13] Bannister GC, Miles AW. The influence of cementing technique and blood on the strength of the bone-cement interface. Eng Med 1988;17:131–3.
[14] Sharkey PF, Hozack WJ, Rothman RH, Shastri S, Jacoby SM. Why are total knee arthroplasties failing today? Clin Orthop Relat Res 2002;404:7–13.
[15] Lutz MJ, Pincus PF, Whitehouse SL, Halliday BR. The effect of cement gun and cement syringe use on the tibial cement mantle in total knee arthroplasty. J Arthroplasty 2009;24:461–7.
[16] Walker PS, Soudry M, Ewald FC, McVickar H. Control of cement penetration in total knee arthroplasty. Clin Orthop Relat Res 1984:155–64.
[17] Dorr LD, Lindberg JP, Claude-Faugere M, Malluche HH. Factors influencing the intrusion of methylmethacrylate into human tibiae. Clin Orthop Relat Res 1984:147–52.
[18] Ozkunt O, Sariyilmaz K, Gemalmaz HC, Dikici F. The effect of tourniquet usage on cement penetration in total knee arthroplasty: a prospective randomized study of 3 methods. Medicine (Baltimore) 2018;97:1–5.
[19] Vertullo CJ, Nagarajan M. Is cement penetration in TKR reduced by not using a tourniquet during cementation? A single blinded, randomized trial. J Orthop Surg 2017;25:1–7.
[20] Jawhar A, Stetzelberger V, Kollowa K, Obertacke U. Tourniquet application does not affect the periprosthetic bone cement penetration in total knee arthroplasty. Knee Surg Sport Traumatol Arthrosc 2019;27:2071–81. https://doi.org/10.1007/s00167-018-5330-7.
[21] Touzopoulos P, Ververidis A, Mpogiatzis C, Chatzigiannakis A, Drosos GI. The use of tourniquet may influence the cement mantle thickness under the tibial implant during total knee arthroplasty. Eur J Orthop Surg Traumatol 2019;29:869–75. https://doi.org/10.1007/s00590-019-02369-8.

[22] Pfitzner T, von Roth P, Voerkelius N, Mayr H, Perka C, Hube R. Influence of the tourniquet on tibial cement mantle thickness in primary total knee arthroplasty. Knee Surg Sport Traumatol Arthrosc 2016;24:96–101.
[23] Meneghini RM, Mont MA, Backstein DB, Bourne RB, Dennis DA, Scuderi GR. Development of a modern knee society radiographic evaluation system and methodology for total knee arthroplasty. J Arthroplasty 2015;30:2311–4. https://doi.org/10.1016/j.arth.2015.05.049.
[24] Park M ho, Bin S Il, Kim JM, Lee BS, Lee CR, Kwon YH. Using a tibial short extension stem reduces tibial component loosening after primary total knee arthroplasty in severely varus knees: long-term survival analysis with propensity score matching. J Arthroplasty 2018;33:2512–7. https://doi.org/10.1016/j.arth.2018.03.058.
[25] Lombardi AV, Mallory TH, Staab M, Herrington SM. Particulate debris presenting as radiographic dense masses following total knee arthroplasty. J Arthroplasty 1998;13:351–5.
[26] Krause WR, Krug W, Miller J. Strength of the cement-bone interface. Clin Orthop Relat Res 1982:290–9.
[27] Schlegel UJ, Bishop NE, Püschel K, Morlock MM, Nagel K. Comparison of different cement application techniques for tibial component fixation in TKA. Int Orthop 2014;39:47–54.
[28] Ritter MA, Herbst SA, Keating EM, Faris PM. Radiolucency at the bone-cement interface in total knee replacement. The effects of bone-surface preparation and cement technique. J Bone Joint Surg Am 1994;76:60–5.
[29] Lotke PA, Faralli VJ, Orenstein EM, Ecker ML. Blood loss after total knee replacement. J Bone Joint Surg Am 1991;73:1037–40.
[30] Bert JM, McShane M. Is it necessary to cement the tibial stem in cemented total knee arthroplasty? Clin Orthop Relat Res 1998:73–8.
[31] Ledin H, Aspenberg P, Good L. Tourniquet use in total knee replacement does not improve fixation, but appears to reduce final range of motion. Acta Orthop 2012;83:499–503.
[32] Molt M, Harsten A, Toksvig-Larsen S. The effect of tourniquet use on fixation quality in cemented total knee arthroplasty: a prospective randomized clinical controlled RSA trial. Knee 2014;21:396–401.
[33] Vandenbussche E, Duranthon LD, Couturier M, Pidhorz L, Augereau B. The effect of tourniquet use in total knee arthroplasty. Int Orthop 2002;26:306–9.
[34] Li MG, Nilsson KG. Changes in bone mineral density at the proximal tibia after total knee arthroplasty: a 2-year follow-up of 28 knees using dual energy X-ray absorptiometry. J Orthop Res 2000;18:40–7.
[35] Jeffery RS, Morris RW, Denham RA. Coronal alignment after total knee replacement. J Bone Joint Surg Am 1991;73:709–14.

Use of HemaClear on the Lower Leg for Foot and Ankle Surgery

Noam Gavriely, MD, DSc.

Chief Medical Officer, OHK Medical Devices - HemaClear®, Haifa, Israel

The HemaClear® is an excellent option for achieving a bleeding-free surgical field in Foot & Ankle procedures. The best choice for adults is the HC-55 (either Orange or Brown). This is better than using the HC-40 Yellow as is explained below using the charts that show the arteries of the lower leg.

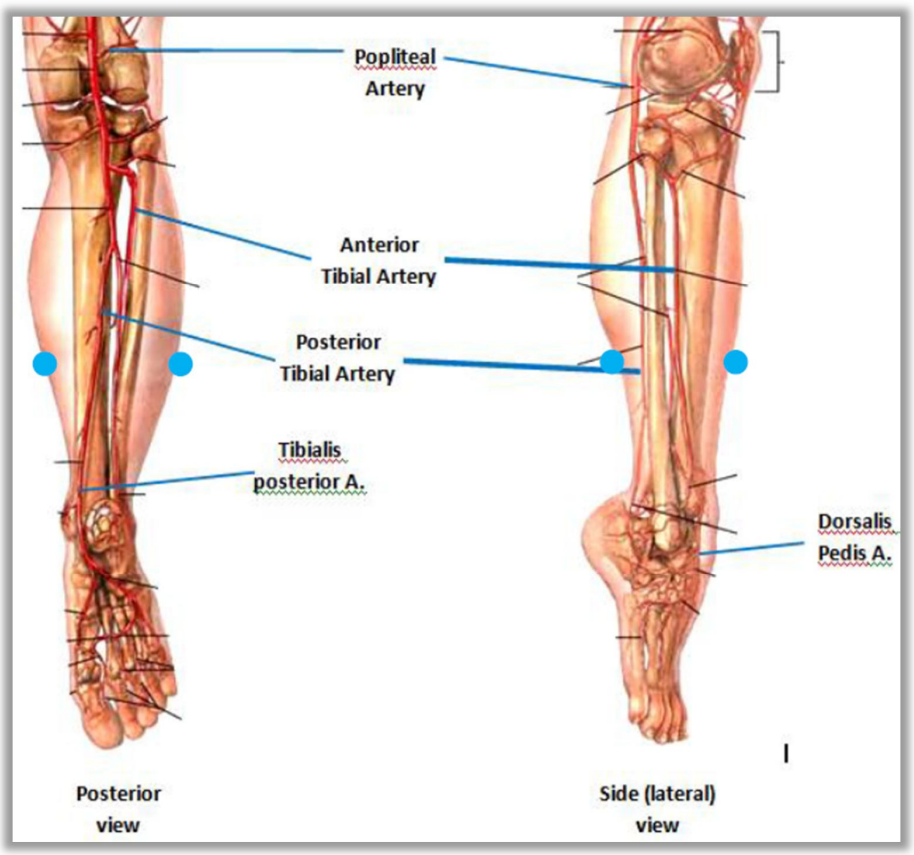

The optimal position of the HemaClear® is just below the calf muscles as shown in the chart above. The circumference at the position is typically 30+4 cm. At this point, there are 3 main arteries that descend into the ankle: the Anterior and Posterior Tibial arteries and the Fibular (Peroneal) artery. The Anterior Tibial artery is passing forward in between the tibia and fibula and is therefore partially shielded from direct pressure. The diagram below shows why the thicker HC-55 is better suited for use in this position.

<u>We do not recommend placing the HC directly on the calf muscles.</u>

©2012 OHK Medical Devices – HemaClear®

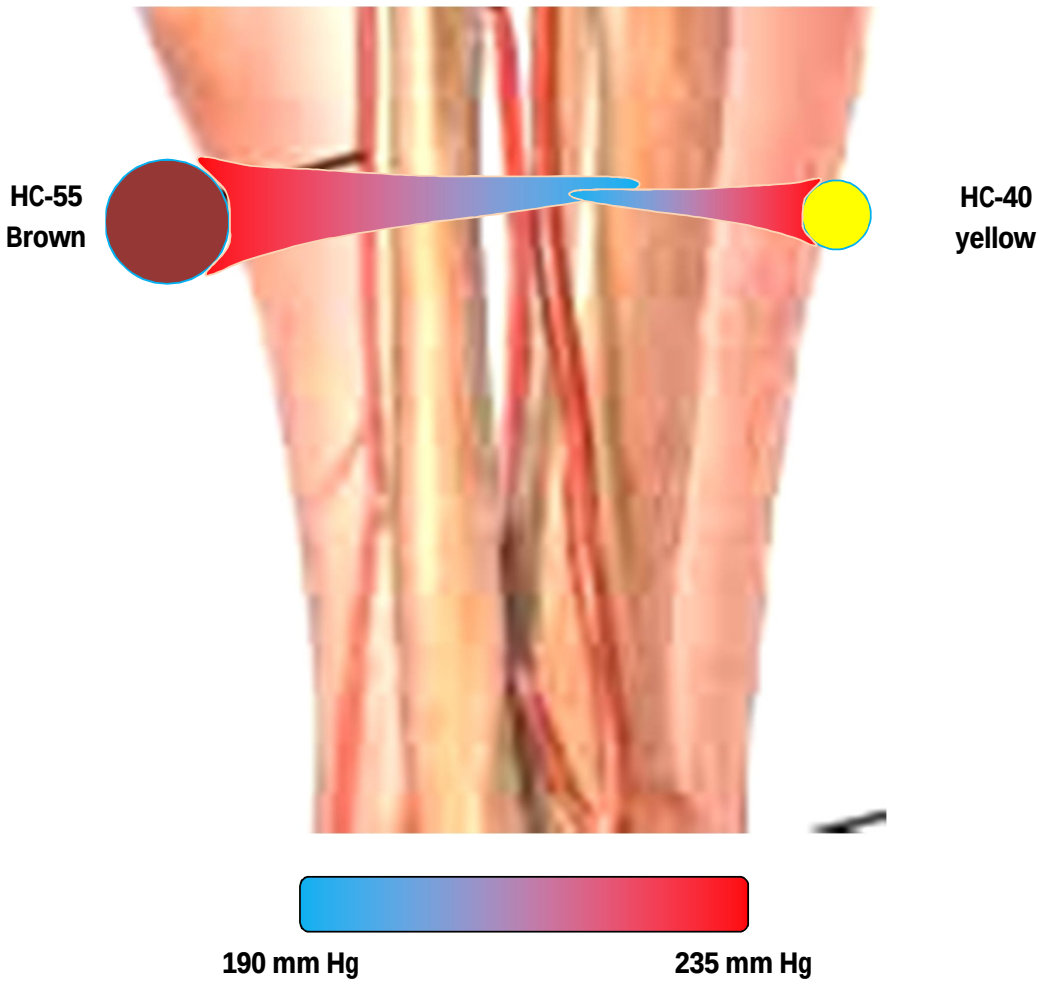

The diagram showing the distribution of pressure within the tissues of the lower leg, just distal to the calf muscles. The color-coded wedges indicate the pressure gradient from the skin to the inner aspect of the limb. The wider HC 55 applies essentially the same skin pressure, but because of the width, the pressure penetrates deeper to include the arteries within its effective range. Note that the narrower HC-40 may not exert enough pressure at the middle of the limb to block the arterial flow, even in normotensive patients.

©2012 OHK Medical Devices – HemaClear®

J. Anat. (1972), **113**, 3, pp. 433–455
With 10 *figures*
Printed in Great Britain

Anatomical changes in peripheral nerves compressed by a pneumatic tourniquet

J. OCHOA,* T. J. FOWLER AND R. W. GILLIATT
Institute of Neurology, Queen Square, London

(*Accepted* 18 *October* 1972)

INTRODUCTION

Local compression is known to damage peripheral nerves. Severe compression may actually crush the fibres and lead to Wallerian degeneration; the excitability of the nerve distal to the lesion is lost and recovery may take many months (Seddon, 1943; Denny-Brown & Brenner, 1944*a*). Mild compression produces a physiological block which is reversed as soon as the pressure is released. On the basis of their studies with pneumatic cuffs or clamps in man, Lewis, Pickering & Rothschild (1931) concluded that this physiological block was due to local asphyxia.

There is a lesion, distinct from either of the two described above, which follows compression of intermediate severity. In such a lesion there is a local conduction block with preservation of distal excitability; this may take several weeks to recover (Erb, 1876; Déjérine & Bernheim, 1899; Seddon, 1943). Using a tourniquet or a spring clip to produce compression, Denny-Brown & Brenner (1944*a*, *b*), found in cats that the anatomical basis for this was demyelination with preservation of axonal continuity at the site of compression. Denny-Brown & Brenner thought that this lesion, like that produced by Lewis *et al.* (1931), was due to local ischaemia of the nerve and that direct mechanical pressure was an unlikely explanation. In support of this they cited the experiments of Grundfest (1936) who had shown that enormous pressures were necessary to abolish conduction in excised frog nerve enclosed in an oxygenated pressure chamber.

During the course of recent experiments in which a tourniquet was used to produce long-standing conduction block in the peripheral nerves of baboons (Fowler, Danta & Gilliatt, 1972), we have found a characteristic lesion which precedes paranodal demyelination. The anatomical features and distribution of this lesion suggest that the damage to the nerve fibres is a direct result of the applied pressure, and not a consequence of secondary ischaemia. A brief preliminary account of our findings has been reported (Ochoa, Danta, Fowler & Gilliatt, 1971).

MATERIAL AND METHODS

Female baboons (*Papio papio*) weighing 9–12 kg were used. Their dates of birth were unknown, but from their dentition and the presence of regular menstrual cycles they were thought to be not less than 5 years old. All procedures were carried out

* Wellcome Senior Research Fellow.

under intravenous pentobarbitone sodium (60–120 mg) after preliminary tranquillization with intramuscular phencyclidine (2 mg/kg) and promazine (1 mg/kg).

A pneumatic cuff consisting of a rubber bag measuring 10 × 5 cm in a specially reinforced sleeve was placed round the knee, with the bag lying over the medial popliteal nerve. When the cuff was inflated the length of nerve compressed was approximately 5·5 cm. In most experiments a cuff pressure of 1000 mm Hg was maintained for 1–3 hours. This produced a local conduction block in the medial and lateral popliteal nerves with weakness of the leg and foot muscles. Both the clinical weakness and the conduction block then lasted for several weeks or months. In a few experiments a cuff pressure of 500 mm Hg was used, but this produced neither clinical paralysis nor a conduction block, although the conduction studies indicated that some nerve damage had occurred, resulting in a persistent conduction delay. Further details of the clinical state of the animals and of the nerve conduction studies are given by Fowler *et al.* (1972).

Animals were killed for anatomical study at intervals which varied from 2 to 3 minutes to six months after release of the pressure cuff. In all, 16 animals were examined. The abdominal aorta was cannulated prior to death and the lower half of the animal was perfused with 4 % glutaraldehyde in phosphate buffer at pH 7·4. Perfusion was maintained for 25–30 minutes at pressures of 150–200 mm Hg. Following this, the medial popliteal nerves were carefully exposed. Under a mark tattooed on the skin, where the upper edge of the cuff had been, a stitch was placed in the epineurium. Nerve samples were taken for three different techniques:

1. Some long stretches of nerve, including the portion under the cuff, were removed and immersed in 1 % osmium tetroxide; loose bundles were then teased in glycerine. This allowed the study of the distribution of the lesion in relation to the cuff.

2. Small samples for longitudinal and transverse sections were taken at measured distances from the stitch in the epineurium. They were post-fixed in 1 % osmium tetroxide in Dalton's solution, and were then dehydrated and embedded in Epon. 1 μm sections were made at different levels, stained with toluidine blue, and examined by light microscopy. Ultrathin sections were stained with uranyl acetate and lead citrate (Reynolds method) and examined under a Siemens Elmiskop I electron microscope.

3. To relate the ultrastructural changes in individual fibres to the positions of the nodes of Ranvier, single teased fibres were prepared for electron microscopy. Transverse sections had previously been prepared from single fibres by Spencer & Thomas (1970) and by Dyck & Lais (1970). In order to obtain longitudinal sections a modified method was developed which can be summarized as follows. Samples from the nerve trunks, 2–3 cm in length, were post-fixed in Dalton's fluid, dehydrated, and impregnated with fluid Epon. From these, single fibres were teased with sharpened forceps, examined under the light microscope and photographed. The fibres were then embedded strictly in one plane and the Epon hardened. Ultrathin longitudinal sections were made from selected parts of each fibre and were then stained and examined under the electron microscope. A detailed description of the technique is given by Ochoa (1972).

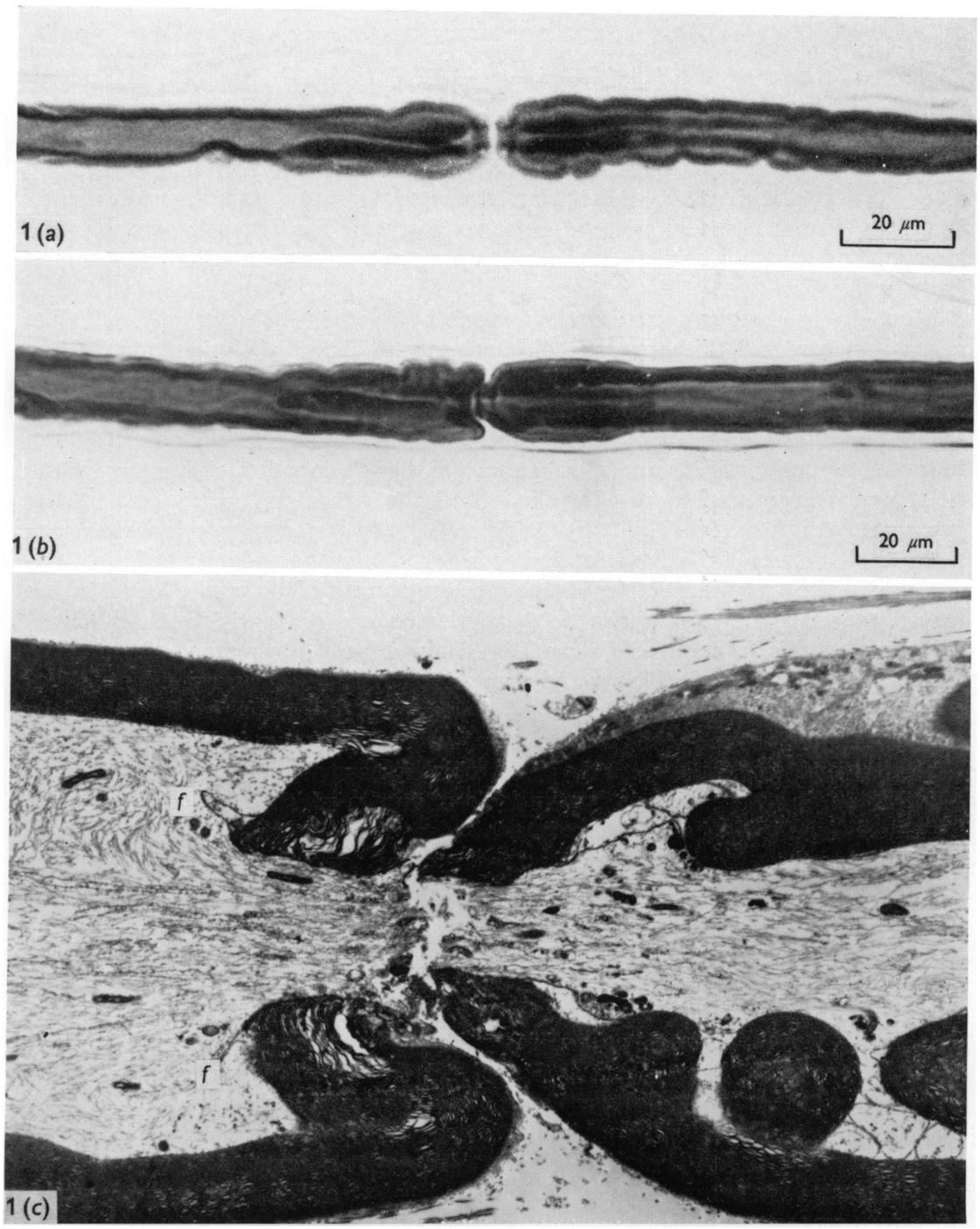

Fig. 1 (*a*). Normal node of Ranvier showing a nodal gap 1·2 μm wide.

(*b*) Abnormal node of Ranvier, 4 days after compression. There is minimal invagination of the paranode on the left by the one on the right, with obliteration of the nodal gap.

(*c*) Low power electron micrograph of node shown in 1 *b*. The axolemma of the invaginated paranode shows redundant folds (*f*). The discontinuity of nodal axoplasm is due to artefact. × 4900.

RESULTS

Displacement of the nodes of Ranvier

When single teased fibres were examined during the first week after compression, a characteristic abnormality of the nodes of Ranvier was seen in the large myelinated fibres. In its mildest form this consisted of a slight invagination of one paranode by an adjacent one, with partial obliteration of the nodal gap. An example can be seen in Fig. 1, in which a normal node is also shown (Fig. 1*a*). The light micrograph of the abnormal node is shown in Fig. 1*b* and a low power electron micrograph of the same node in Fig. 1*c*.

More severe invagination of one paranode by another is shown in Fig. 2. The general appearances of the nodal region are shown in the light micrograph above (Fig. 2*a*) and the detailed changes in the electron micrograph of the same region below (Fig. 2*b*). It can be seen that the paranode on the left has been invaginated by the one on the right to a depth of approximately 35 μm. The myelin sheath of the latter lies partially inside that of the former, and there is complete obliteration of the nodal gap. The terminal loops of myelin of both the ensheathed and the ensheathing paranodes can be seen in Fig. 2*b* (*t.l.*). These show their normal relationship to the nodal axolemma in both cases, thus indicating the site of the node. Part of Fig. 2*b* is shown at higher magnification in Fig. 2*c*. The attachment of the myelin loops (in this case of the ensheathing paranode) to the axolemma can be clearly seen. Additional evidence that this is the site of the node is obtained from the presence of transverse bands between the terminal loops and the axolemma. In Fig. 2*c* a redundant fold of axolemma (*f*) can be seen to the left of the terminal loops. Similar folding of the axolemma can be seen in the same position in this fibre shown in Fig. 1*c*.

The narrowing of the axon at the node, which is normally present in large myelinated fibres, is exaggerated under the folds of myelin which overlie the region in abnormal fibres (Figs. 1*c*, 2*b*). Axoplasmic organelles and particles may accumulate in relation to these local strictures. Past the stricture, towards the invaginated paranode, the neurofilaments appear distorted and may form curly patterns towards the surface of the axon (Fig. 1*c*).

In Figs. 2*a* and 2*b* there is a constriction of the fibre to the right of the node. This constriction underlies the junction between the two Schwann cells and is labelled *j*. Such junctions can be identified by the discontinuity of the Schwann cell cytoplasm (here containing abundant mitochondria) and by the presence of microvilli. Fig. 3*a* is taken from another fibre to illustrate this point. It shows the basement membrane, the cytoplasm of the adjacent Schwann cells, their microvilli, and the indented myelin underlying them. By conventional light microscopy such an indentation could easily be mistaken for a node of Ranvier, but closer inspection shows that there is no nodal gap; electron micrographs make it clear there has in fact been displacement of the node with respect to the Schwann cell junction.

Fibres showing varying degrees of invagination are illustrated in Fig. 4. In each case the new position of the node of Ranvier (*n*) and its original position under the Schwann cell junction (*j*) are shown. In these fibres the positions were checked by electron microscopy but it was possible to identify their site by light microscopy alone, the constriction indicating the Schwann cell junction being clearly visible, and

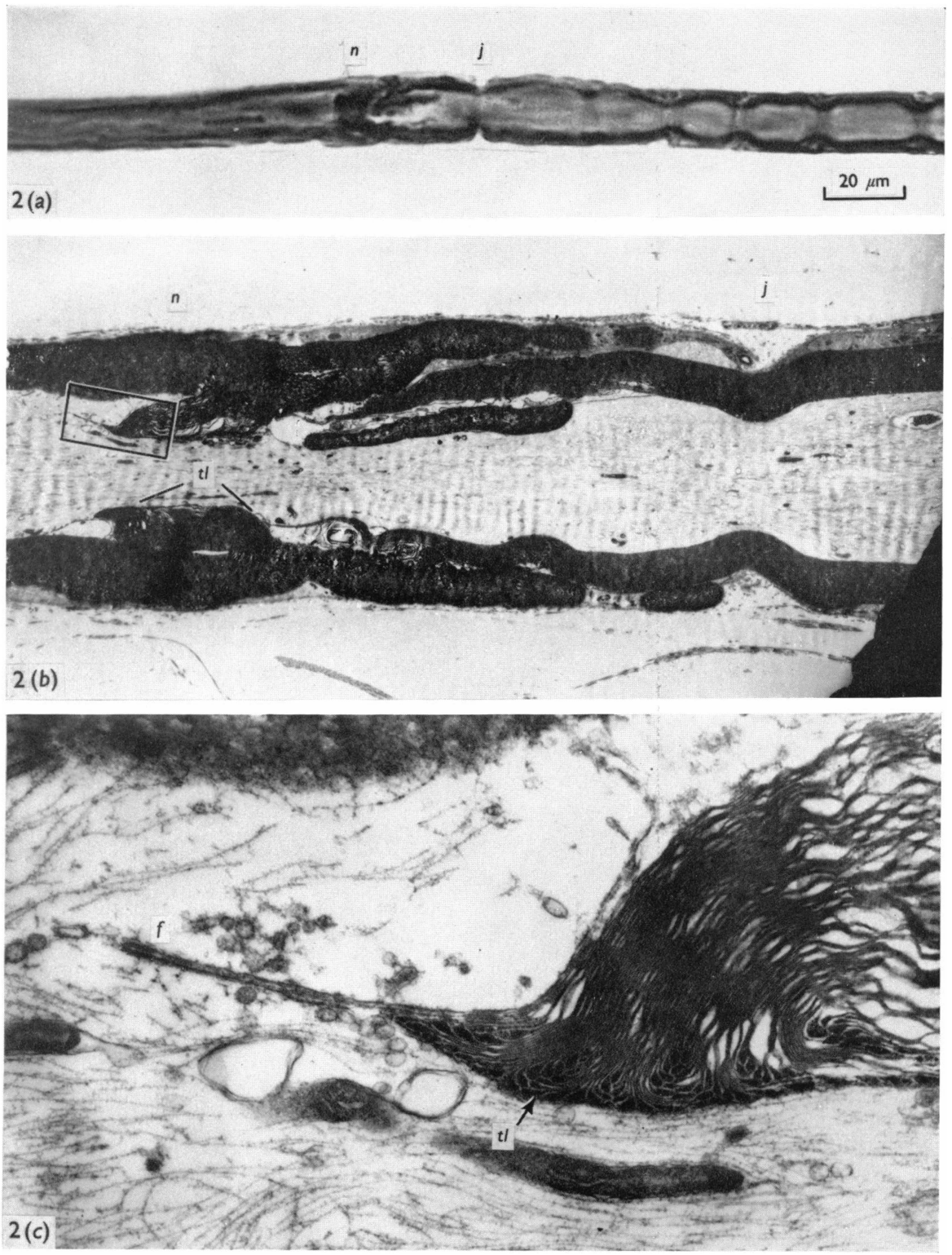

Fig. 2(*a*). Abnormal node of Ranvier, 4 days after compression. At the expected site of the nodal gap there is indented myelin (*j*). To the left there is a dark area (*n*) marking the new position of the node. Note Schmidt–Lanterman clefts opened on the right.

(*b*) Low power electron micrograph of the nodal region shown in (*a*). *j*, Schwann cell junction; *n*, node of Ranvier covered by infolded myelin; *t.l.*, terminal loops of myelin lamellae. ×2850.

(*c*) Enlargement of area contained in rectangle in 2*b*, to show typical arrangement of terminal loops of myelin lamallae (*t.l.*) in relation to axolemma. Folded axolemma (*f*) is also shown. ×26000.

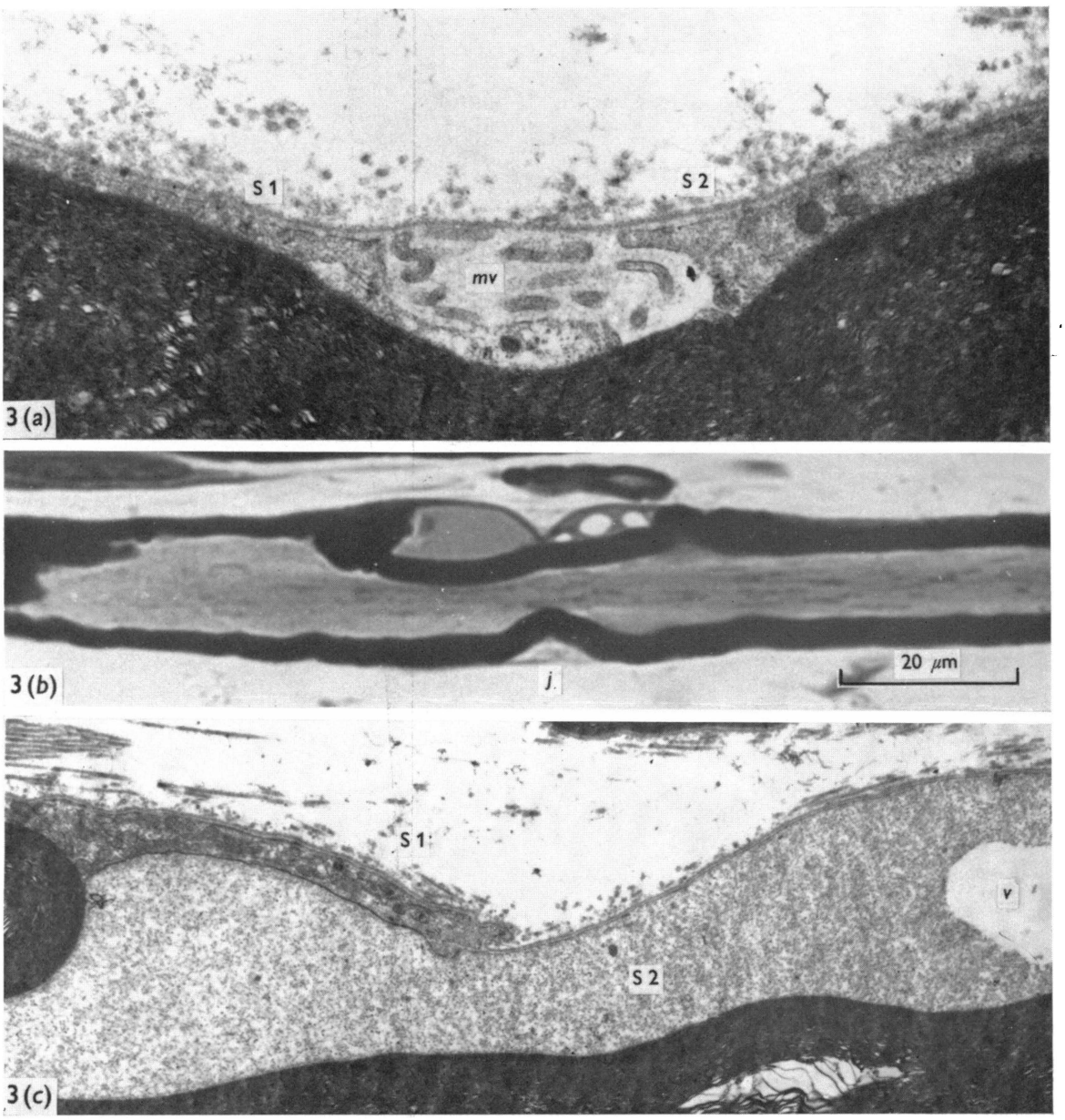

Fig. 3 (*a*). Schwann cell junction, 18 hours after compression, overlies myelin instead of node of Ranvier. Microvilli (*mv*) from the two Schwann cells S 1 and S 2, are seen within the basement membrane. × 15800.

(*b*) Longitudinal section of fibre 4 days after compression. It shows indented myelin at the Schwann cell junction (*j*) and swollen Schwann cell cytoplasm containing vacuoles. Epon-toluidine blue.

(*c*) Electron micrograph showing detail of the fibre in 3*b*. The thin tongue of paranodal Schwann cell cytoplasm on the left (S 1) has been dissected from the myelin by a swollen cell process intruding from the Schwann cell on the right (S 2). In the latter, cytoplasmic differentiation is lost and there is a vacuole (*v*). × 8700.

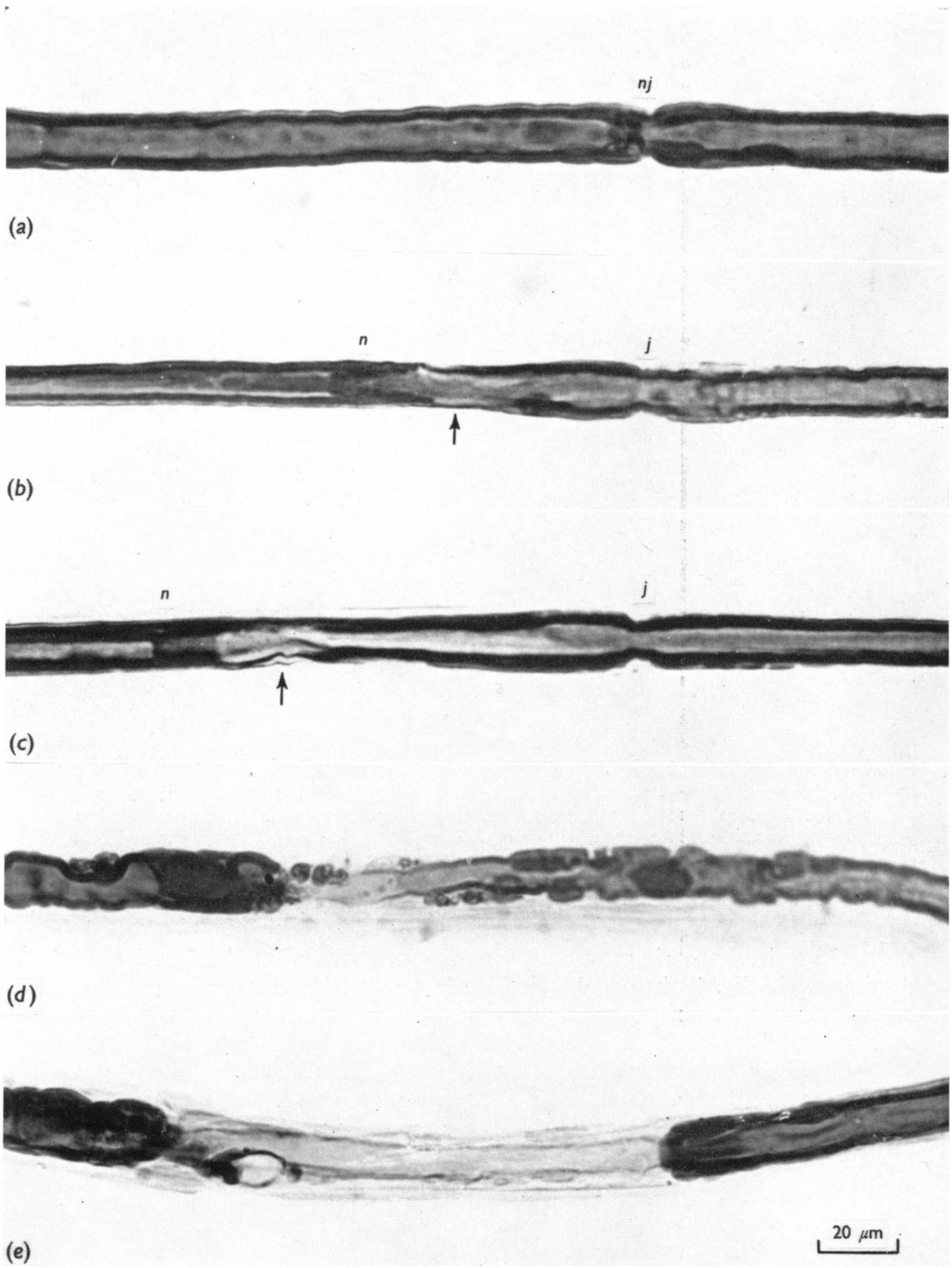

Fig. 4(*a–c*). Abnormal fibres, 4 days after compression, showing different degrees of nodal displacement (reaching 120 μm in *c*). *j*, Schwann cell junction; *n*, new position of node. Note thinning of myelin at arrows.

(*d*) A fibre, 15 days after compression, undergoing demyelination of the paranodal region. There is tapering of the myelin of the paranode on the right.

(*e*) A thinly myelinated intercalated segment, 61 days after compression.

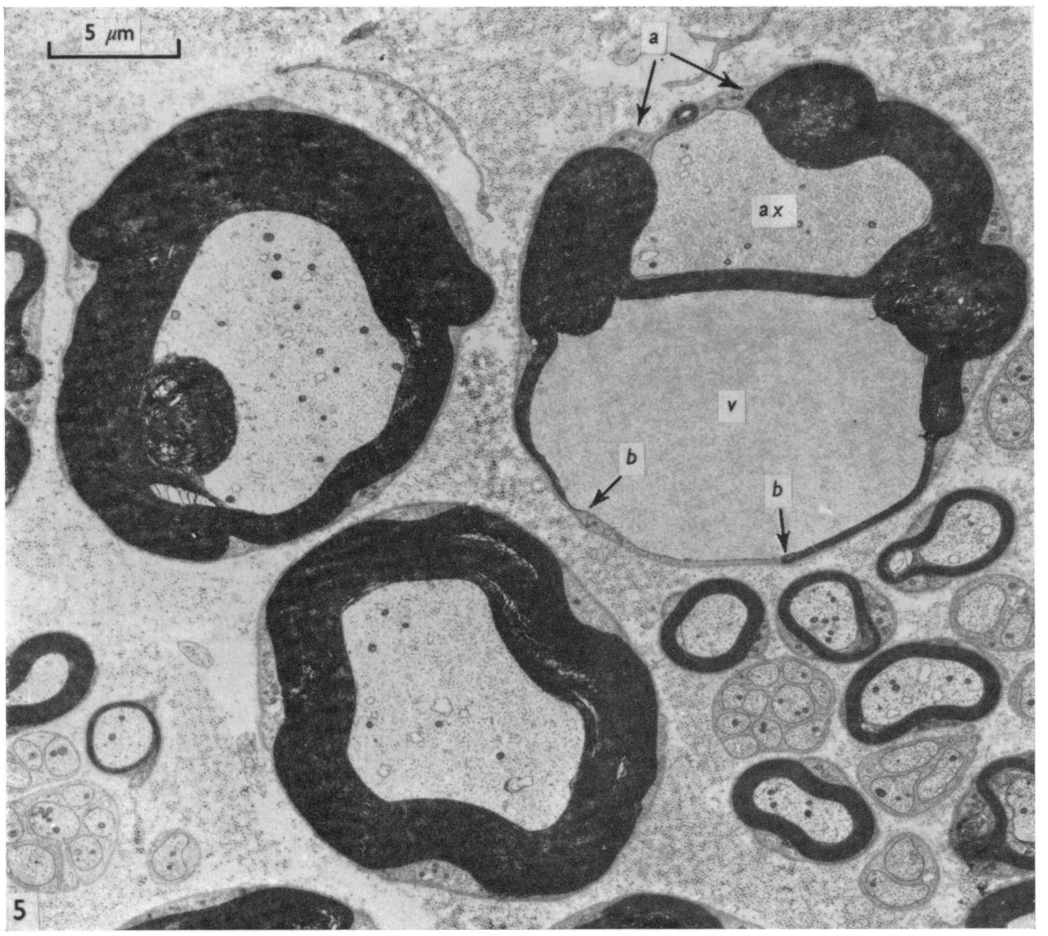

Fig. 5. Transverse section from a nerve, 18 hours after compression, to show myelin rupture and oedema. The fibre on the left shows partial rupture of myelin lamellae. The fibre on the right shows rupture of the whole thickness of the myelin sheath at *a*, the axon (*ax*) being separated from the basement membrane by a thin Schwann cell process. A collection of homogeneous material (*v*) has split the myelin sheath with rupture of the outer lamellae at *b*. Small myelinated and unmyelinated fibres appear normal.

the nodal region appearing as a dark zone within the fibre (see also Fig. 2*a*). In the fibre shown in Fig. 4*c* the nodal region is 120 μm from the constriction marking the site of the Schwann cell junction. The maximal separation of the node from the Schwann cell junction in our material has been approximately 300 μm. In the fibres shown in Fig. 4*b* and 4*c* partial rupture of the myelin has occurred (arrows). This was a common finding when the distance between the node and the Schwann cell junction was greater than 50 μm. It will be discussed in more detail below.

Early changes in Schwann cells and myelin

There were early changes in the cytoplasm of the Schwann cells. The normal cytoplasmic differentiation was sometimes lost and the contents were replaced by homogeneous granular material, this change being accompanied by swelling. An example is

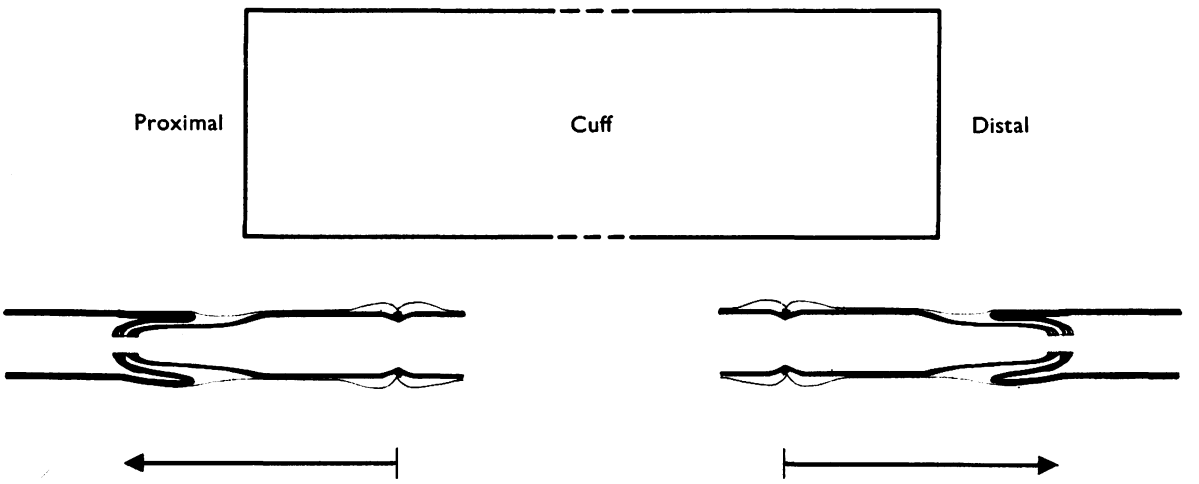

Fig. 6. Diagram to show the direction of displacement of the nodes of Ranvier in relation to the cuff.

shown in Fig. 3*b* and 3*c*. The site of the Schwann cell junction can be identified by the indentation marked *j* in Fig. 3*b*; above it there is swollen Schwann cell cytoplasm containing vacuoles. In the electron micrograph of the same region (Fig. 3*c*) it can be seen that the cytoplasm of Schwann cell S1 has an abnormal homogeneous appearance; it is swollen and lies between a tongue of normal cytoplasm (S2) and the underlying myelin. One vacuole (*v*) is present in the plane of section. In other sections the Schwann cell cytoplasm contained swollen mitochondria, and it seems possible that vacuoles such as those seen in Fig. 3, either membrane-bound or without a membrane (as in Fig. 3*c*), are the result of mitochondrial disintegration.

The cytoplasmic and mitochondrial changes described above were seen in nerves examined during the first week after compression but had disappeared after 2 weeks. A more persistent change occurred in the paranodal myelin itself. Transverse sections of nerves taken within 24 hours of compression showed not only rupture of myelin lamellae but also their separation by homogeneous or finely particulate material, presumably fluid. These changes might then persist for many weeks. Examples are shown in Fig. 5. The fibre on the left shows partial rupture of the myelin with coiling back of the free ends. In the fibre on the right the whole thickness of the myelin is ruptured at the points marked (*a*) and the axolemma is in direct contact with Schwann cell plasma membrane. This fibre also shows a large intra-myelin vacuole (*v*) which is distended with homogeneous material; the outer lamellae appear to have been ruptured at (*b*) by the distension. Such appearances, suggesting intra-myelin oedemain addition to rupture of myelin lamellae, were common in the first few weeks after compression, and were seen to a diminishing extent in later specimens.

Fibre size and susceptibility to damage

A consistent finding in all the nerves examined was the sparing of small myelinated and non-myelinated fibres. In Fig. 5 it can be seen that none of the small myelinated fibres is abnormal. In our teased preparations as well as in transverse sections, the characteristic early lesion, consisting of invagination of one paranode by another,

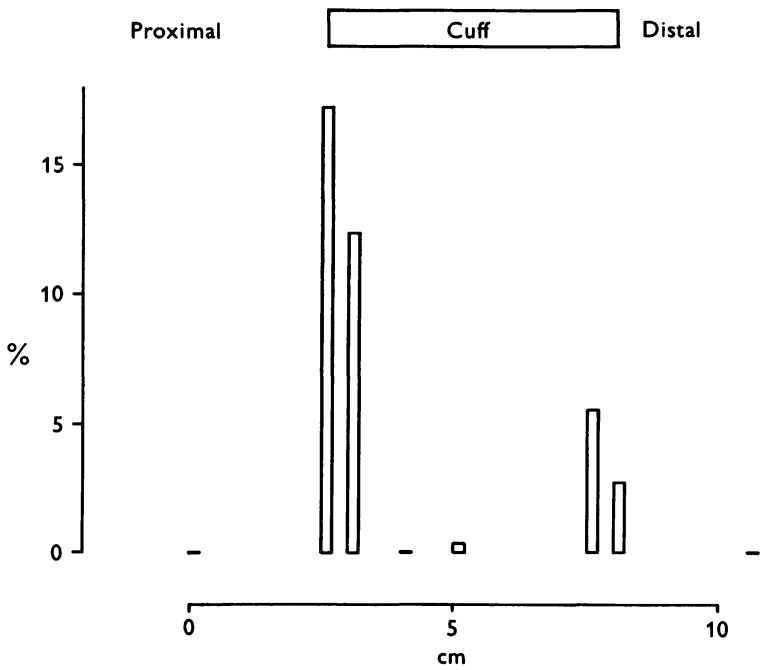

Fig. 7. Medial popliteal nerve, 4 days after compression at 1000 mm Hg for 90 minutes. The histogram shows the proportion of abnormal fibres in transverse sections at different levels under the cuff, the abnormal fibres being expressed as a percentage of the large myelinated fibre population at each level. For further details see text.

was largely restricted to fibres with an axon diameter greater than 5 μm. The only pathological change to be found in small myelinated fibres was Wallerian degeneration, which was sometimes seen in severely affected nerves, in which it also affected a proportion of the large myelinated fibres. In the non-myelinated fibres some early cytoplasmic and mitochondrial changes were seen in the Schwann cells, but actual degeneration of axons was rare.

These results are of interest in relation to the previous observation of Fowler *et al.* (1972) that pain sensation had always preserved in the affected limbs of these animals, even when compression had been sufficiently severe to produce a complete conduction block in the high velocity efferent and afferent fibres.

Distribution of lesions under the cuff

Displacement of the nodes of Ranvier was maximal under the edges of the cuff, with relative or complete sparing under its centre. This distribution was found both in teased fibres and in transverse sections. The teased fibres showed an additional feature; the nodes of Ranvier were displaced in the same direction in all the fibres at any one level under the cuff, the direction in each case being towards uncompressed tissue. Thus the displacement was in one direction under the proximal edge of the cuff and in the opposite direction under its distal edge. This is shown diagrammatically in Fig. 6.

While it was difficult to tease apart long enough lengths to show the complete distribution of lesions in a single fibre, a picture could be built up by dividing the

nerve into 2 cm portions which were teased separately, their orientation being carefully preserved. From these it appeared that successive nodes over a distance of 2–3 cm might be damaged under either edge of the cuff, these regions being separated by a central portion, 1·5–3·0 cm in length, which was largely or completely spared. In each of the affected regions, the depth of invagination of individual nodes gradually increased towards the centre of the damaged zone and then decreased again. There were thus, as judged from the depth of invagination of individual nodes, two points of maximal nerve damage, which were under the two edges of the cuff and separated by approximately 5 cm.

An additional feature was revealed when transverse sections of the whole nerve were cut at different levels under the cuff. Areas containing not less than 800 large myelinated fibres (axon diameter 5 μm or over) were selected at each level for quantitative study. Within these areas the abnormal fibres (showing changes similar to those shown in Fig. 5) were counted and their number expressed as a percentage of the total number of large myelinated fibres in the sample. A histogram based on such an analysis is shown in Fig. 7.

From this it can be seen that the proportion of abnormal fibres was greater under the proximal than under the distal edge of the cuff. At the proximal level approximately 15 % of the fibres in the transverse section were abnormal. It must be remembered, of course, that in each fibre the abnormality would not occupy the whole of the internode but only the part adjacent to the node. If only 15 % of each internode were occupied by the lesion, the result shown in Fig. 7 would indicate that all the large myelinated fibres were affected in the proximal part of the lesion. When histograms showing the proportion of remyelinating fibres at different levels were subsequently prepared from recovering nerves, a similar result was obtained (Ochoa *et al.* 1971; Fowler, 1973). These findings confirm the impression gained from teasing that all the nodes on the large myelinated fibres were abnormal in the most severely affected parts of compressed nerves.

Demyelination

In nerves examined between 7 and 14 days after the application of a tourniquet, some fibres still showed the changes described in the previous sections. In others, the damaged paranodal myelin was clearly undergoing degeneration, droplets and debris being present within the Schwann cell cytoplasm (Fig. 4*d*). Later, the remnants were removed by macrophages which had invaded the region. This process usually affected the myelin of both the ensheathed and the ensheathing paranodes.

After 15 days, no invagination was identified, the most prominent change at this stage being the appearance of paranodal demyelination. An example is shown in Fig. 8*a*. Immediately to the left of the demyelinated zone there is osmiophilic myelin debris. On the right, the myelin appears to taper gradually from its normal thickness as the demyelinated zone is approached. An electron micrograph of the same region (Fig. 8*b*) shows that this tapering occurs in a step-wise fashion, abrupt decreases in myelin thickness occurring at the points marked by arrows, the intervals between them being 10 and 15 μm. These points may correspond to the original sites of Schmidt–Lanterman incisures. One of them is shown at higher magnification in Fig. 8*c*, and it can be seen that the torn lamellae have formed loops with dark

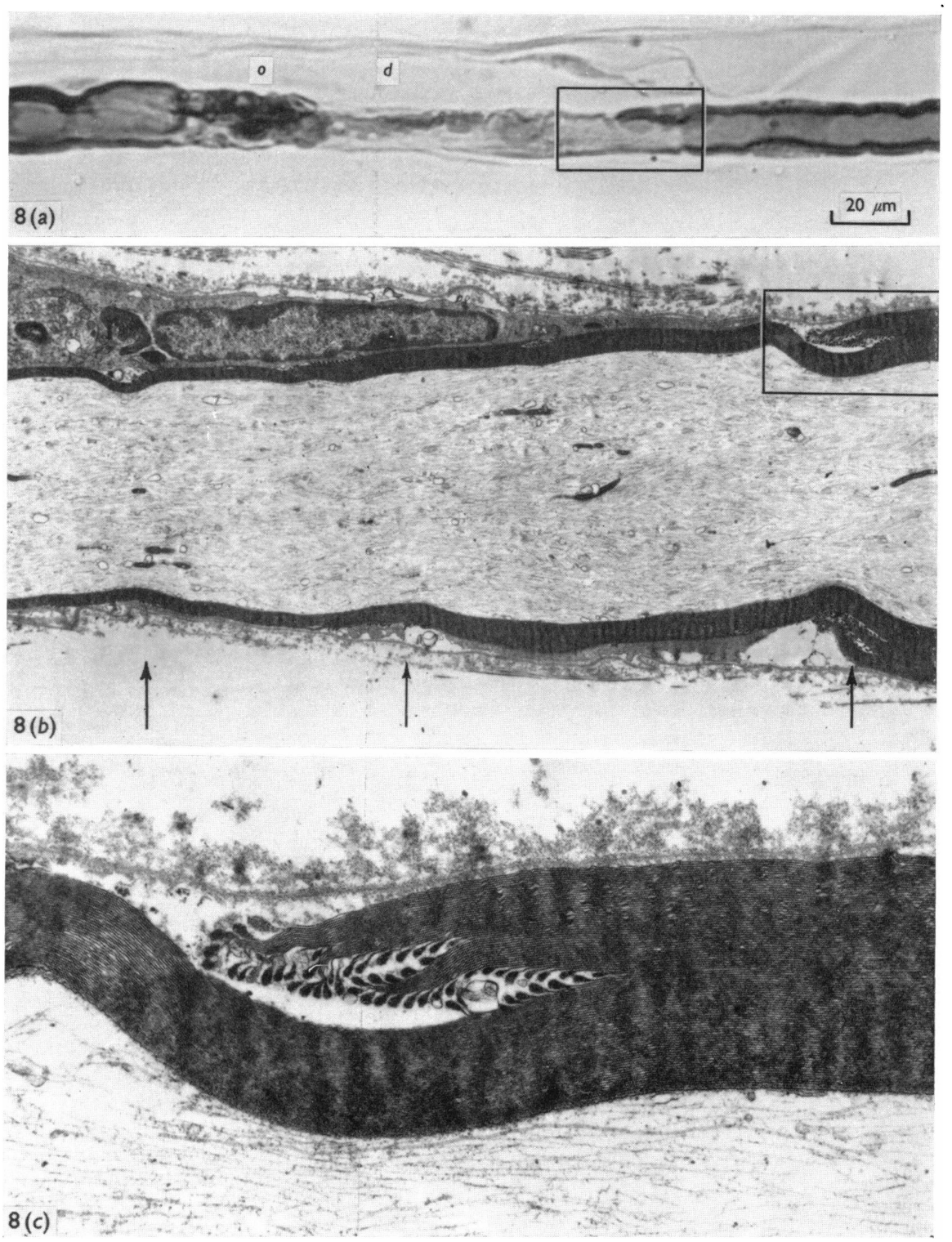

Fig. 8(*a*). Abnormal nodal region, 43 days after compression. A demyelinated stretch of axon (*d*) is limited on the left by osmiophilic debris (*o*) and by tapering myelin on the right.

(*b*) Low power electron micrograph shows detail of area enclosed in rectangle in 8*a*. Tapering results from stepwise interruption of several adjacent myelin lamellae: their free ends occur in clusters at points arrowed. Note mononuclear cell between myelin and basement membrane. ×4000.

(*c*) Enlargement of area enclosed in rectangle in 8*b* to show club-like ends of amputated lamellae. ×19200.

homogeneous contents. Amputation of the myelin lamellae at the Schmidt–Lanterman clefts might cause the appearance shown in Fig. 8*c*, but an alternative explanation would be that these are terminal loops of myelin stripped from the juxta-nodal axolemma.

In any one fibre, does the length which is demyelinated match the distance separating the node of Ranvier and the Schwann cell junction after nodal displacement? This is difficult to answer, as one cannot examine the same fibre at different stages of the same process. We have seen under the electron microscope a Schwann cell junction overlying myelin which gradually tapered towards the edge of a completely demyelinated zone. This suggests that myelin at the edge of an invaginating lesion can survive, so that the length of completely demyelinated axon would be less than the distance by which the node had been displaced. In other fibres, myelin debris was present beyond the zone of invagination, suggesting that the length of axon finally demyelinated would be slightly greater than the distance of nodal displacement. In general, however, the maximal displacement of the node in early lesions (approximately 300 μm) was comparable to the maximal length of axon subsequently demyelinated. Throughout our material demyelination of more than 300 μm has been rare. In contrast to Denny-Brown & Brenner's findings in the cat, we saw very few completely demyelinated internodal segments. When these were found, they usually occurred in severely affected nerves which had been subjected to the maximum compression used.

Severity of the lesion in relation to cuff pressure and duration

The changes described in the preceding sections resulted from compression at 1000 mm Hg. When a pressure of 500 mm Hg was used, the pathological changes were similar but milder in degree. Thus, the depth of invagination and displacement of individual nodes was less, and few fibres were seen in which the myelin was torn. In addition, the length of the affected zones under the edges of the cuff was less. This difference is of some interest in relation to our previous physiological findings, since compressions at 500 mm Hg resulted in slowing of impulse conduction without complete block (Fowler *et al.* 1972).

In the group of nerves compressed at 1000 mm Hg physiological studies showed a significant correlation between the duration of compression and the severity and duration of the subsequent conduction block. One might therefore expect that nerves compressed for 180 minutes would show more severe histological changes than those compressed for 60 or 75 minutes. However, a difference in the extent of displacement of individual nodes of Ranvier was difficult to demonstrate. In one animal, cuffs at 1000 mm Hg were inflated round both knees, one cuff being released after 1 hour and the other after 3 hours. The animal was then killed and the nerves examined. Nodal

---

Fig. 9(*a*). Low power electron micrograph of nerve 14 weeks after compression. *d*, demyelinated axon; *r*, remyelinating axon; *f*, fibroblast; *l*, lymphocytes. × 3300.

(*b*) Light micrograph of area adjacent to that shown in 9*a*. There are two swollen fibres with distended myelin and shrunken axons. Epon-toluidine blue.

(*c*) Longitudinal section of another nerve, 6 weeks after compression, to show paranodal situation of swellings. Epon-toluidine blue.

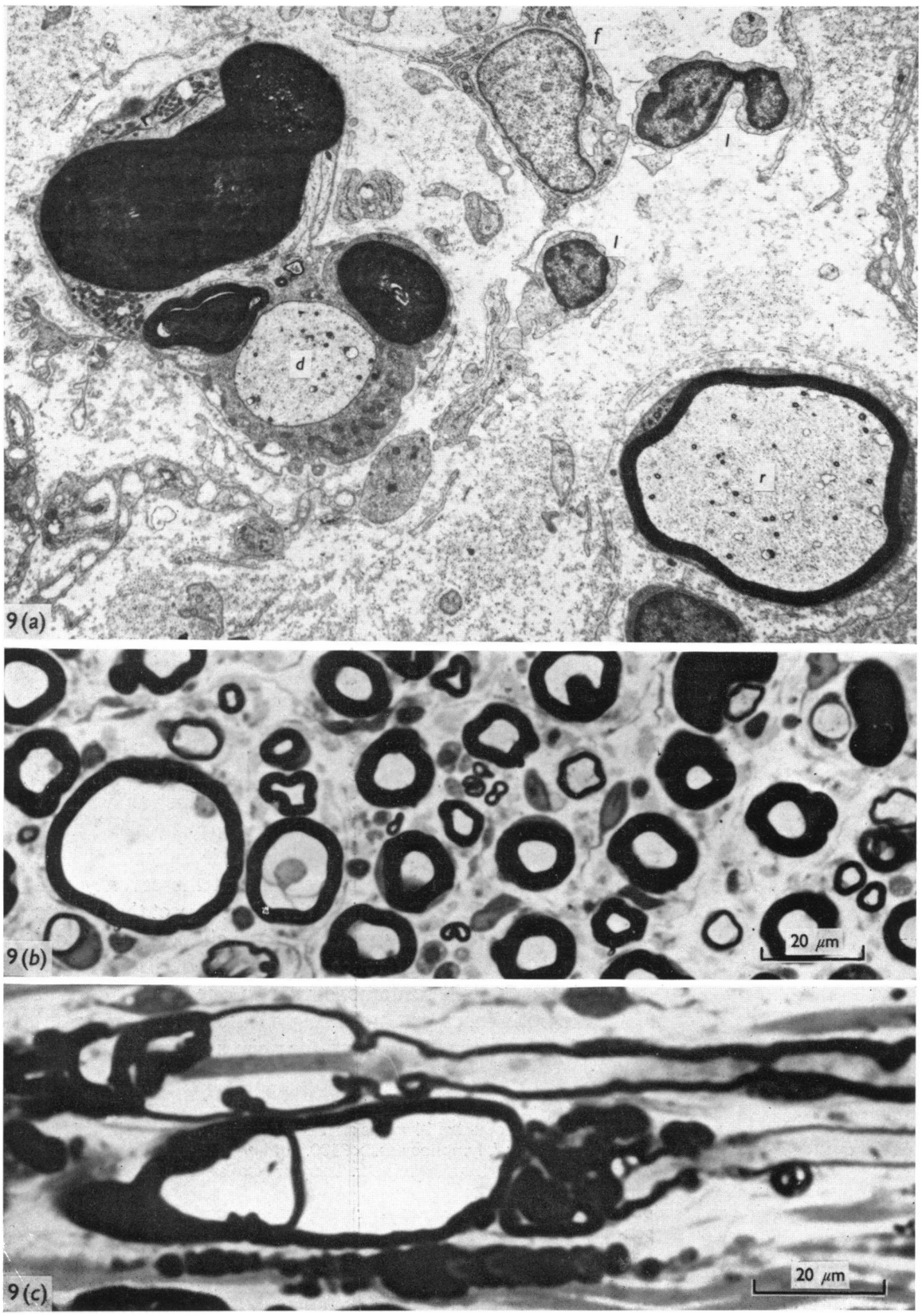
f
l
l
d
r
9 (a)
20 μm
9 (b)
20 μm
9 (c)

displacements of up to 300 μm were seen on both sides but the total number of affected nodes was less after 1 hour of compression than after 3 hours.

There were additional features in nerves subjected to the longer periods of compression. One of these was demyelination of complete internodal segments, which was not seen after compression for 60 to 75 minutes. Even after compression for 180 minutes this was an uncommon finding. When segmental demyelination did occur, its distribution was similar to that of the paranodal demyelination, that is, under the edges of the cuff but not under its centre.

A second feature which distinguished the longer periods of compression was Wallerian degeneration. This was more conspicuous in nerves compressed for 150 or 180 minutes than in those compressed for 90–120 minutes. It was not seen in nerves compressed for only 60 or 75 minutes at 1000 mm Hg or in any of the nerves compressed at 500 mm Hg. No quantitative studies of the amount of Wallerian degeneration in individual nerves were carried out, but an estimate could be made from the electrophysiological findings. In eleven nerves subjected to repeated nerve conduction studies before and after compression, it was estimated by Fowler *et al.* that the proportion of alpha motor fibres undergoing degeneration varied from zero to 30 % with a mean for the whole group of 11 %.

Although repeatedly looked for, no examples were seen of either paranodal or segmental demyelination in nerve fibres in the distal part of the limb. Even in nerves which had been subjected to compression for 180 minutes, and which showed Wallerian changes in a proportion of the fibres at the ankle, demyelination was absent.

Remyelination

The final stage of the pathological process in nerves affected by compression was usually the intercalation of Schwann cells with the production of short, thinly remyelinated segments (Fig. 4*e*). These were generally similar to the intercalated segments originally described by Renaut (1881) and Lubińska (1958), and subsequently identified in many different forms of peripheral neuropathy (Thomas & Lascelles, 1965; Fullerton, 1966; Hopkins, 1970). At some nodes the appearances during recovery were rather different, no intercalated segment being present, but the paranodal myelin being thin, and tapering gradually towards the node. We were uncertain whether this indicated remyelination by lateral extension of myelin from an intact region as proposed by Allt (1969), or whether the thin tapered myelin was due to the persistence of partial demyelination similar to that shown in Fig. 8.

There was considerable variation in the time-course of remyelination in different fibres of the same nerve. An example is shown in Fig. 9*a*, which was taken from a nerve 14 weeks after compression. On the left there is a demyelinated axon 6 μm in diameter, ensheathed by Schwann cell processes containing myelin remnants. To its right there is a remyelinated axon, 9·5 μm in diameter, which already shows a well-formed sheath of compact myelin.

Why should some fibres still be demyelinated more than 3 months after injury? This may be related to a phenomenon seen to some extent in all recovering animals, namely the presence of swollen fibres showing evidence of intra-myelin and periaxonal oedema. Fig. 9*b* is from the same nerve as in Fig. 9*a*, and shows a mixture of normal, demyelinated and thinly remyelinated fibres. In addition there are two

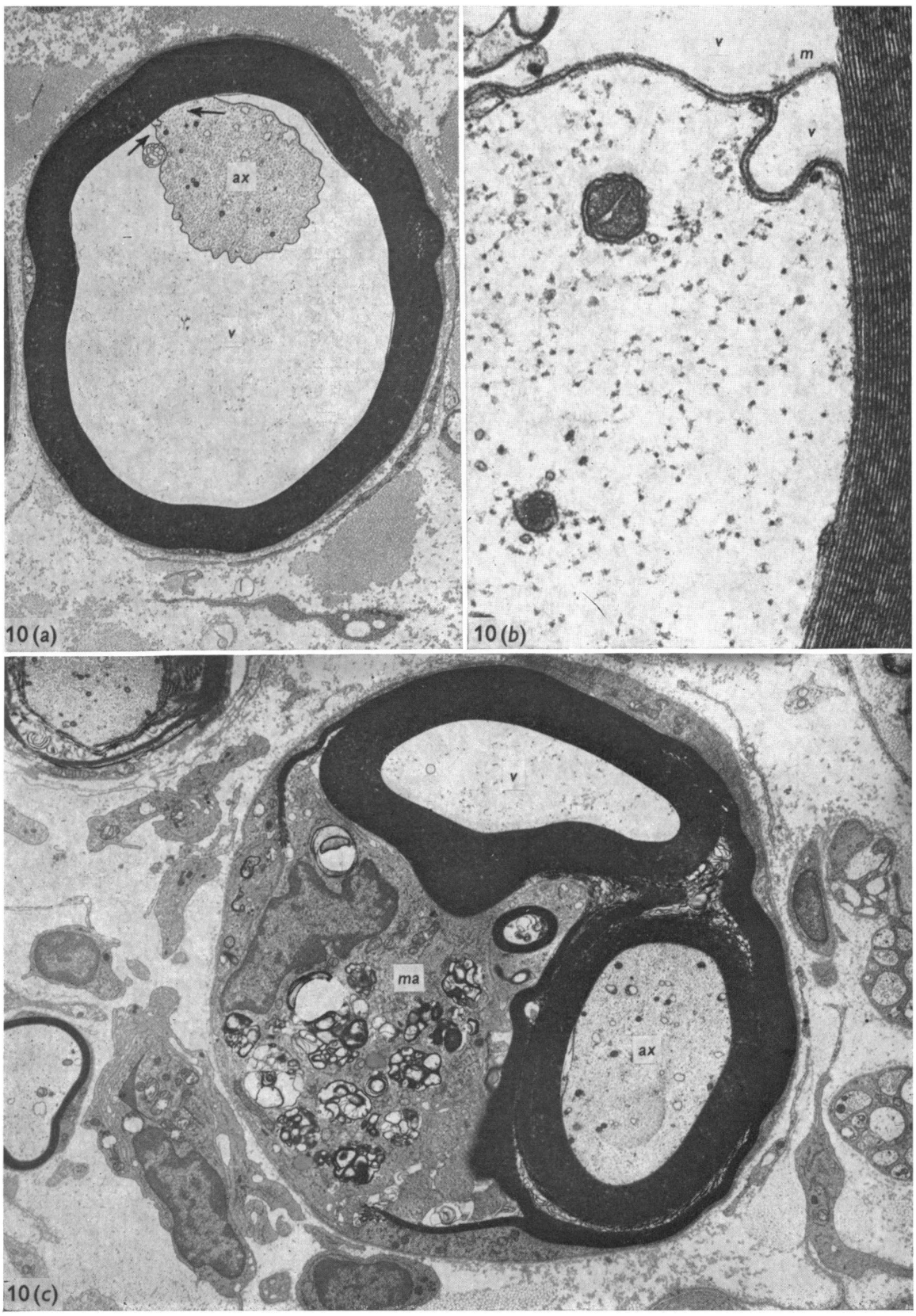
ax
v
10 (a)
v
m
v
10 (b)
v
ma
ax
10 (c)

grossly swollen fibres, each showing a distended myelin sheath separated from a small shrunken axon. Two further examples from a longitudinal section of a nerve 6 weeks after compression are shown in Fig. 9*c*. In one of these the plane of section was such that the axon is not shown and the swelling appears empty. In the other, a shrunken central axon can be seen.

From these and other sections it was clear that these were localized swellings up to 120 μm in length and up to 30 μm in diameter, situated in the paranodal region adjacent to a demyelinated or remyelinated portion of the axon. An electron micrograph of a paranodal swelling is shown in Fig. 10*a*. The axon is shrunken and its fibrous contents are densely packed. It is suspended in a finely granular matrix, suggestive of oedema fluid, which almost completely separates it from the myelin sheath, to which it is still linked by its mesaxon. In this case the fluid accumulated in the inner cytoplasmic tongue of the Schwann cell (Fig. 10*b*). In other fibres the fluid split the compact myelin, leaving several layers covering a shrunken axon. In these fibres also, the fluid was assumed to be intracellular since it split the major dense line.

What is the fate of the paranodal swellings? It appears that they are eventually invaded by macrophages which remove the distended myelin, as in the example shown in Fig. 10*c*. Such delayed demyelination could explain the demyelinated axons and the myelin debris occasionally seen in nerves many months after compression (for example see Fig. 9*a*).

In considering the functional significance of the swellings, two points should be emphasized. In the first place many were present in nerves which had been compressed for long periods at 1000 mm Hg but relatively few were seen after shorter periods at the same pressure; they were rare after compression at 500 mm Hg. Furthermore, the swellings were numerous at a relatively early stage of recovery and had mostly disappeared by the time recovery was complete.

The relationship of these changes to the prolonged conduction blocks seen in our physiological experiments is dealt with in the discussion.

DISCUSSION

The characteristic lesion we have described involves displacement of the node of Ranvier from its normal site; this implies stretching of the paranodal myelin on one side of the node and invagination of the paranodal myelin on the other. Since there is no similar displacement of the Schwann cell junction, the result is lateral movement of the axon and paranodal myelin relative to the Schwann cells on either side of the node; this must cause local rupture of the Schwann cell membrane (mesaxon). The invaginated paranodal myelin remains enclosed within its Schwann cell but is

---

Fig. 10(*a*). Low power electron micrograph of a swelling 6 weeks after compression. The swollen inner tongue of Schwann cell cytoplasm (*v*) separates most of the surface of the axon (*ax*) from the myelin sheath. A sector remains attached to the sheath. × 3000.

(*b*) Enlargement of area arrowed in 10*a*. The mesaxon (*m*) is seen with swollen Schwann cell cytoplasm (*v*) on either side of it. × 44000.

(*c*) A myelinated fibre from the same nerve as above, showing axon (*ax*) and a pocket of oedema (*v*). A macrophage (*ma*) has penetrated the basement membrane and broken into the myelin sheath. × 4600.

effectively separated from it, and the invaginating paranodal myelin is extracellular with respect to its own Schwann cell. In both cases degeneration of the myelin follows. Although the Schwann cells show some reactive changes, they retain their viability and it is rare for demyelination to involve complete internodal segments.

Why should nodal displacement occur during compression? We suggest that the primary event is displacement of axoplasm from under the cuff and that the axoplasmic movement meets resistance at the nodes of Ranvier where two factors may operate. In the first place there may be an increase in the viscosity of the axoplasm at the node, this region acting as a plug which is then forced in the direction of axoplasmic movement. Alternatively, the normal narrowing of the axon which occurs at the node (Hess & Young, 1952; Berthold, 1968) could form an obstacle to the free movement of axoplasm. In both cases the result would be displacement of the nodal axolemma and of the myelin attached to it.

The normal narrowing of the axon at the node would provide a possible explanation for the selective effect of compression on the large myelinated fibres, with sparing of small myelinated fibres. In the latter, the axons are not narrowed at the nodes, so that movement of axoplasm along the fibre could occur without nodal displacement. In suggesting this we have assumed that movement of axoplasm along small fibres does occur with the cuff pressures we have used. There is, however, no proof that this is so. Since the force required to displace fluid within a tube is inversely related to the diameter, it is possible that the pressures we used were sufficient to produce axoplasmic movement in large fibres but not in small ones. Direct measurement of axoplasmic movement in small fibres would be necessary to answer this question.

Why are the lesions concentrated under the edges of the cuff? This could be explained by the pressure gradient in the tissues between the parts under the cuff and those beyond its edge. With the relatively wide cuff we have used, the gradient would be maximal under the edges of the cuff and least under its centre. Without such a gradient one would not expect axoplasmic movement or displacement of the nodes of Ranvier to occur, even if the absolute pressure in the tissues were high. As an example of the ability of a peripheral nerve to withstand high pressures provided that there is no gradient between one part and another, one may cite the experiments of Grundfest (1936), who showed that when an isolated portion of frog nerve was wholly enclosed in an oxygenated pressure chamber, pressures of the order of 1000 atmospheres were necessary to abolish conduction. It is interesting that both Edwards & Cattell (1928) and Bentley & Schlapp (1943) considered that the effect of pressure on peripheral nerves was to produce distortion which was maximal at the edges of the compressed part. The latter authors found that when exposed cat sciatic nerve was compressed between two pneumatic cushions, most of the fibres appeared to be blocked at one or other edge of the compressed zone rather than at the centre.

In our own experiments we do not know whether the conduction block which follows a tourniquet is due to obliteration of the nodal gap itself, or whether changes in membrane permeability and impedance elsewhere along the internode might be responsible. From the physiological studies of Fowler *et al.* (1972) it seems that mild compression produces slowing of conduction, whereas more severe compression results in conduction block. Using diphtheria toxin in the rat, Rasminsky & Sears

(1972) have studied the effect of demyelination on conduction in single fibres. Their conclusion, which may be relevant to the present results, was that myelin damage first resulted in a reduced current flow at the node and a delay in the activation of adjacent nodes. There was thus an overall fall in conduction velocity before the myelin damage was sufficient to block conduction completely. Further studies of velocity changes in single fibres and in different regions under the cuff in our tourniquet lesion are clearly required to investigate this question further.

It was shown by Fowler *et al.* (1972) that the conduction block which follows compression at 1000 mm Hg might last for many weeks or months, and that there was a significant correlation between the duration of compression and that of the subsequent block. In these experiments conduction was studied in the nerve fibres supplying a small foot muscle, the motor fibres being stimulated above and below the cuff and the muscle response being recorded from abductor hallucis. Using needle electrodes inserted through the skin, this procedure could be carried out repeatedly under anaesthesia without damage to the nerve or muscle. It should be emphasized that these physiological experiments were concerned with conduction in a selected group of motor fibres passing under the cuff, whereas the anatomical studies were carried out on the whole medial popliteal nerve trunk at that level. For this reason an exact correlation cannot be made between the degree of physiological block and the pathological appearances of the particular fibres responsible for it.

It is, however, possible to make some general comments concerning the long delay which often occurred before conduction in damaged fibres was resumed. In this context we attach considerable importance to the paranodal swellings described above. These swellings are apparently due to the distension of the myelin sheath by oedema fluid; the axon itself is shrunken and perhaps compressed. Such swellings may be found in decreasing numbers in nerves for several months after compression and it seems reasonable to suggest that they are responsible for the conduction block which persists in some fibres for a similar period. Their late breakdown would account for the occasional demyelinated axon seen during the later stages of recovery (Fig. 9*a*), and it seems unnecessary to postulate an additional defect of remyelination to explain the presence of such axons.

In addition to the variation in the rate of recovery we have shown to exist between one fibre and another, it must be remembered that there may be a similar variation between different nodal lesions on the same fibre. If as many as 30 nodes of Ranvier on a single fibre were damaged initially, one must envisage a series of separate conduction blocks along the fibre, each one of which must recover before conduction could be resumed through the whole region. In such a situation the physiological deficit would be more severe than the histological appearances might suggest.

The origin of the paranodal swellings requires special comment. In some ways their appearance is reminiscent of the distended fibres seen in cerebral oedema due to tri-ethyl tin (Aleu, Katzman & Terry, 1963; Hirano, Zimmerman & Levine, 1968). Similar appearances were described by Spencer & Thomas (1970) in peripheral nerve fibres proximal to nerve section. In both cases, however, there were differences. For example, the swelling seen after tri-ethyl tin appeared to be generalized rather than localized to the paranodal regions. In the case of nerve section the swellings were localized but occurred in thinly myelinated fibres which were thought to be

remyelinating. In contrast to this, the swellings seen in the present study always occurred in the terminal portions of the original internodes, although they were adjacent to those parts of the axon which were demyelinated or thinly remyelinated (that is, the sites of previous invagination). In some cases the distended myelin was of normal thickness, indicating that partial myelin rupture of the type shown in Fig. 5 was not a pre-requisite for the formation of swellings. There was also a difference in the distribution of the oedema fluid seen in the first few days after compression and that seen at a much later stage. In the former it was never limited to the inner tongue of Schwann cell cytoplasm surrounding the axon. In the late paranodal swellings, however, oedema fluid in this situation was a common finding. In spite of these differences, it seems reasonable to conclude that the late swellings are the result of the intra-myelin oedema which is first seen within a few hours of compression, and which can, apparently, persist and alter its distribution with the passage of time. In contrast to this, oedema of the Schwann cell cytoplasm external to the myelin sheath was only seen during the first few days, after which it disappeared.

There has in the past been considerable discussion as to the role of ischaemia in relation to the local demyelination which results from compression. It was argued by Denny-Brown & Brenner (1944*a*) that the pressure was itself insufficient to produce direct mechanical damage, and that it acted by producing secondary ischaemia of the compressed region. This was similar to the mechanism postulated by Lewis, Pickering & Rothschild (1931) for the reversible physiological block which is produced in man by a sphygmomanometer cuff inflated to a pressure slightly greater than that of the systolic blood pressure. While we accept that ischaemia may be responsible for the reversible physiological block described by Lewis *et al.*, it is clear that the anatomical changes which we have described must be a direct result of the applied pressure. It could not be argued that a lesion such as this one, involving as it does the displacement of anatomical structures, could be caused by ischaemia alone.

It may be added that ischaemia alone did not produce demyelination in our experiments. Distal to a cuff at 1000 mm Hg conduction in motor fibres failed within 40–50 minutes, but continuation of the procedure for 2–3 hour periods did not result in demyelination distal to the site of compression. Ischaemia combined with minimal compression was no more effective in producing demyelination. This was tested by using a cuff pressure of 250 mm Hg (Ochoa, Rudge & Gilliatt, unpublished observations). The systolic blood pressure in an anaesthetized baboon is approximately 120 mm Hg, and our standard cuff at 250 mm Hg produced complete circulatory arrest, the reversible physiological block in fibres distal to the cuff having the same time-course as that produced by a cuff pressure of 1000 mm Hg. However, when the cuff at 250 mm Hg was maintained for 2 hours, there was no persistent conduction block or conduction delay, and subsequent anatomical examination of the compressed nerve revealed no demyelination.

Although ischaemia alone or in combination with compression at 250 mm Hg did not produce demyelination in our experiments, it is possible that in combination with compression at 500 or 1000 mm Hg it could contribute to the severity of the result. We know that compression at 1000 mm Hg for 3 hours produces a longer-lasting conduction block than a similar pressure applied for 1 hour. The results

described in the present paper suggest that this may be related to the greater number of paranodal swellings seen after prolonged compression. Could these latter changes be the result of compression combined with prolonged ischaemia? In the case of the rapidly reversible cytoplasmic and mitochondrial changes we have seen in the Schwann cells external to the myelin, the appearances are in some ways similar to those described by Webster & Ames (1965) and McGee-Russell, Brown & Brierly (1970) after anoxia or hypoglycaemia. While we are not aware of any published reports of intra-myelin oedema resulting from ischaemia, its appearance after cyanide administration in mice (S. Hall, personal communication) suggests that it can occur. The possible contribution of ischaemia to the intra-myelin oedema and thus to the paranodal swellings seen in the present study clearly requires further investigation.

Finally, one may ask whether displacement of the nodes of Ranvier occurs in pressure lesions other than those caused by tourniquet. While it seems probable that a similar basic lesion is present in a variety of human pressure palsies of the type described by Seddon as due to 'neurapraxia' (Seddon, 1943), there is at the present time no direct evidence that this is so, and further experiments are in progress to establish this point.

There are, however, three other situations which require mention. The first of these is the nerve crush in which, as Lubińska has shown, there is paranodal demyelination involving two or three nodes proximal to the level of the crush (Lubińska, 1959, 1961). It seems possible that the paranodal demyelination might be the result of axonal movement caused by the crush and, indeed, appearances suggesting invagination of myelin are shown in Figs. 18 and 19 of Lubińska (1959). The other situation in which this lesion may occur is in the much older experiment originally described by Ranvier in 1878. In this, an isolated segment of frog nerve was compressed with a spring clip *in vitro*; Ranvier's drawings and his description of the resulting changes strongly suggest that paranodal invagination had occurred, although the nerve had already been placed in fixative at the time of compression.

These latter experiments are cited by Hess & Young (1952), who studied single teased nerve fibres which had been placed in silver nitrate and nitric acid for several hours (to stain the cross of Ranvier at the nodes) and then washed and mounted in glycerin. They found that slight pressure on the coverslip of these preparations caused the axon to 'move within the sheath leaving stained neurilemma at the node'. In this way they produced displacement of the nodal axoplasm; from their illustrations it is clear that the cementing disk remained in its original position, but it cannot be seen whether invagination of the paranodal myelin occurred.

SUMMARY

A pneumatic cuff inflated to 1000 mm Hg round the knee for 1–3 hours has been used to produce pressure neuropathy in the baboon. A previous study has shown that after this procedure a conduction block in the medial popliteal nerve may persist for several weeks or months.

An electron microscope study of single teased fibres has shown that the primary lesion caused by compression of the large myelinated fibres is a displacement of the node of Ranvier from its usual position under the Schwann cell junction. This is

accompanied by stretching of the paranodal myelin on one side of the node and invagination of the paranodal myelin on the other.The nodal axolemma can sometimes be identified as far as 300 μm from its original position under the Schwann cell junction. In such cases there is partial or complete rupture of the stretched paranodal myelin.

The nodal displacement is maximal under the edges of the cuff, with relative or complete sparing under its centre, the direction of displacement always being away from the cuff towards uncompressed tissue. These findings suggest that the pressure gradient within the nerve between its compressed and its uncompressed parts is the factor responsible for the movement.

This nodal lesion is followed by breakdown of the paranodal myelin. Remyelination subsequently occurs with the formation of short intercalated segments. Repair may be delayed by intramyelin and periaxonal oedema, which results in localized swellings in which a shrunken axon is separated by oedema fluid from a distended myelin sheath. Such local swellings can be found in diminishing numbers for several months after compression. It is suggested that their persistence could be responsible for the delay in functional recovery.

We wish to thank Miss Carol Aldridge and Mr H. Long for technical assistance. We are also grateful to Dr W. I. McDonald and Dr D. N. Landon for helpful criticism and discussion. The work was supported by the Medical Research Council and the Muscular Dystrophy Group of Great Britain.

REFERENCES

ALEU, F. P., KATZMAN, R. & TERRY, R. D. (1963). Fine structure and electrolyte analysis of cerebral edema induced by alkyl tin intoxication. *Journal of Neuropathology and Experimental Neurology* **22**, 402–413.

ALLT, G. (1969). Repair of segmental demyelination in peripheral nerves: an electron microscope study. *Brain* **92**, 639–646.

BENTLEY, F. H. & SCHLAPP, W. (1943). The effect of pressure on conduction in peripheral nerve. *Journal of Physiology (London)* **102**, 72–82.

BERTHOLD, C. H. (1968). Ultrastructure of the node-paranode region of mature feline ventral lumbar spinal-root fibres. *Acta Societatis medicorum upsaliensis* **73**, *Supplementum* **9**, 36–70.

DÉJÉRINE, J. J. & BERNHEIM. H. (1899). Sur un cas de paralysie radiale par compression, suivi d'autopsie. *Revue Neurologique* **7**, 785–788.

DENNY-BROWN, D. & BRENNER, C. (1944*a*). Paralysis of nerve induced by direct pressure and by tourniquet. *Archives of Neurology and Psychiatry (Chicago)* **51**, 1–26.

DENNY-BROWN, D. & BRENNER, C. (1944*b*). Lesion in peripheral nerve resulting from compression by spring clip. *Archives of Neurology and Psychiatry (Chicago)* **52**, 1–19.

DYCK, P. J. & LAIS, A. C. (1970). Electron microscopy of teased nerve fibres: method permitting examination of repeating structures of the same fibre. *Brain Research* **23**, 418–424.

EDWARDS, D. J. & CATTELL, McK. (1928). Further observations on decrement in nerve conduction. *American Journal of Physiology* **87**, 359–367.

ERB, W. (1876). Diseases of the peripheral cerebro-spinal nerves. Vol. XI of *Cyclopaedia of the Practice of Medicine* (Ed. Ziemssen, H. von). London: Samson Low, Marston, Searle & Rivington.

FOWLER, T. J., DANTA, G. & GILLIATT, R. W. (1972). Recovery of nerve conduction after a pneumatic tourniquet: observations on the hind-limb of the baboon. *Journal of Neurology, Neurosurgery and Psychiatry* **35**, 638–647.

FOWLER, T. J. (1973). Tourniquet Paralysis in the Baboon. D.M. Thesis, University of Oxford. In preparation.

FULLERTON, PAMELA M. (1966). Chronic peripheral neuropathy produced by lead poisoning in guinea-pigs. *Journal of Neuropathology and Experimental Neurology* **25**, 214–236.

GRUNDFEST, H. (1936). Effects of hydrostatic pressures upon the excitability, the recovery, and the potential sequence of frog nerve. *Cold Spring Harbor Symposia on Quantitative Biology* **4**, 179–187.

HESS, A. & YOUNG, J. Z. (1952). The nodes of Ranvier. *Proceedings of the Royal Society, Series B*, **140**, 301–320.

HIRANO, A., ZIMMERMAN, H. M. & LEVINE, S. (1968). Intramyelinic and extracellular spaces in triethyltin intoxication. *Journal of Neuropathology and Experimental Neurology* **27**, 571–580.

HOPKINS, A. P. (1970). The effect of acrylamide on the peripheral nervous system of the baboon. *Journal of Neurology, Neurosurgery and Psychiatry* **33**, 805–816.

LEWIS, T., PICKERING, G. W. & ROTHSCHILD, P. (1931). Centripetal paralysis arising out of arrested blood flow to the limb, including notes on a form of tingling. *Heart* **16**, 1–32.

LUBIŃSKA, L. (1958). 'Intercalated' internodes in nerve fibres. *Nature, London* **181**, 957–958.

LUBIŃSKA, L. (1959). Region of transition between preserved and regenerating parts of myelinated nerve fibres. *Journal of Comparative Neurology* **113**, 315–335.

LUBIŃSKA, L. (1961). Demyelination and remyelination in the proximal parts of regenerating nerve fibres. *Journal of Comparative Neurology* **117**, 275–289.

MCGEE-RUSSELL, S. M., BROWN, A. W. & BRIERLEY, J. B. (1970). A combined light and electron microscope study of early anoxic-ischaemic cell change in rat brain. *Brain Research* **20**, 193–200.

OCHOA, J., DANTA, G., FOWLER, T. J. & GILLIATT, R. W. (1971). Nature of the nerve lesion caused by a pneumatic tourniquet. *Nature, London* **233**, 265–266.

OCHOA, J. (1972). Ultrathin longitudinal sections of single myelinated fibres for electron microscopy. *Journal of Neurological Sciences* **17**, 103–106.

RANVIER, M. L. (1878). *Leçons sur l'Histologie du Système Nerveux*. Paris: F. Savy.

RASMINSKY, M. & SEARS, T. A. (1972). Internodal conduction in undissected demyelinated nerve fibres. *Journal of Physiology, London* **227**, 323–350.

RENAUT, M. J. (1881). Recherches sur quelques points particuliers de l'histologie des nerfs. 1. La gaine lamelleuse et le système hyalin intravaginal. *Archives de physiologie, 2nd Series (Paris)* **8**, 161–190.

SEDDON, H. J. (1943). Three types of nerve injury. *Brain* **66**, 237–288.

SPENCER, P. S. & THOMAS, P. K. (1970). The examination of isolated nerve fibres by light and electron microscopy, with observations on demyelination proximal to neuromas. *Acta neuropathologica (Berlin)* **16**, 177–186.

THOMAS, P. K. & LASCELLES, R. G. (1965). Schwann-cell abnormalities in diabetic neuropathy. *Lancet* **i**, 1355–1357.

WEBSTER, H. DE F. & AMES, A. (1965). Reversible and irreversible changes in the fine structure of nervous tissue during oxygen and glucose deprivation. *Journal of Cell Biology* **26**, 885–909.

HemaClear®
Sterile & Bloodless Surgical Field

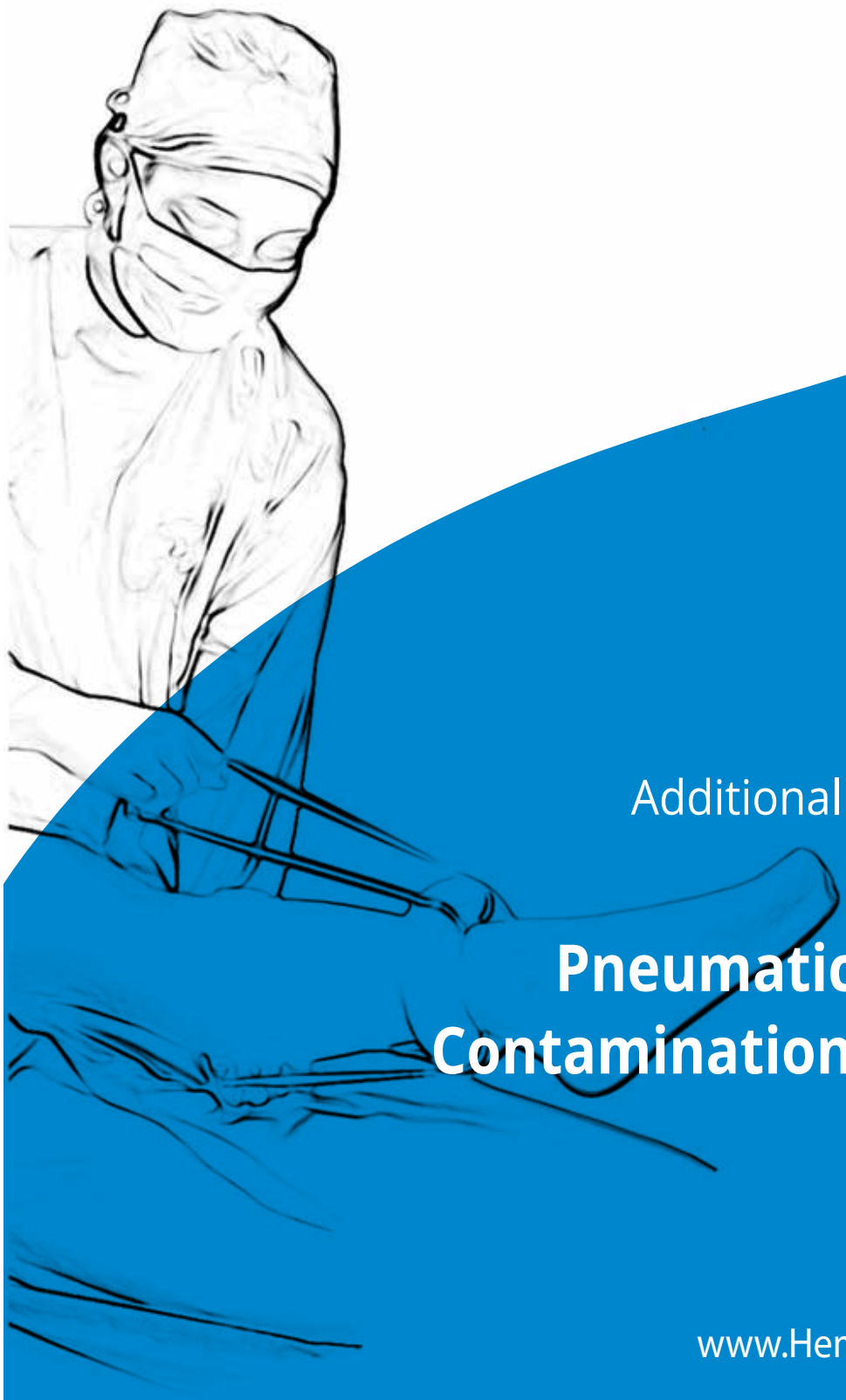

Additional Manuscripts

Pneumatic Tourniquet Contamination and Side Effects

www.HemaClear.com

Position Paper

On

The Use of Non-Sterile Pneumatic Tourniquets in Limb Operations

Submitted by

Noam Gavriely MD, DSc and Larry Murdock, RRT

OHK Medical Devices Ltd.

Synopsis

Despite multiple peer-reviewed clinical studies showing 100% of non-sterile reusable pneumatic tourniquet cuffs being contaminated with the same pathogens that cause surgical site infection (SSI), many hospitals and surgical centers continue to use them. The purpose of this position paper is to review the literature and set the stage for a mid-term change in the AORN Standards of Care recommendation on the use of tourniquets to mandate that all tourniquets used on patients for limb surgery be sterile.

Conflicts of Interest:

Both authors are employees and stakeholders of OHK Medical Devices, the manufacturer of HemaClear Exsanguination Tourniquet (www.hemaclear.com).

Background

Devices to exsanguinate a limb and block the re-entry of blood into it have been in routine use for >140 years. Initially it was the Esmarch bandage, originally described by Friedrich von Esmarch in 1873, used alone to both exsanguinate the limb and for arterial blocking. The pneumatic tourniquet followed shortly thereafter with its invention by Harvey Cushing in 1908. Both devices are still in broad use in the operating theatre. Since 2003 the sterile elastic exsanguination tourniquet (HemaClear®) is being used in hospitals in the US and around the world.

Data

Starting in 2006 a series of papers appeared in the peer-reviewed literature where bacterial colonization of non-sterile pneumatic tourniquets had been analyzed. Table 1 shows the main findings of each of these studies.

Title	Authors	Journal	Date and page	Main findings	Authors Comment
Microbial colonization of tourniquets used in orthopedic surgery.	Walsh EF[1], Ben-David D, Ritter M, Mechrefe A, Mermel LA, DiGiovanni C.	Orthopedics.	2006 Aug; 29(8):709-13.	coagulase-negative staphylococci, Bacillus, and Staphylococcus aureus were present in 100%, of non-sterile OR tourniquets,	Tourniquet contamination may be a risk factor for the development of surgical site infection in orthopedic surgery.
A study of microbial colonisation of orthopaedic tourniquets.	Ahmed SM[1], Ahmad R, Case R, Spencer RF.	Ann R Coll Surg Engl.	2009 Mar;91(2): 131-4	All sampled (n=20) tourniquets were contaminated with colony counts varying from 9 to > 385. Coagulase-negative Staphylococcus spp. were the most commonly grown organisms from the tourniquets (96%). Some tourniquets had growths of important pathogens including methicillin-resistant Staphylococcus aureus (MRSA), Pseudomonas spp., and S. aureus.	In addition to the manufacturers' guidelines, we recommend the cleaning of tourniquets with a disinfectant wipe before every case.

Tourniquets and exsanguinators: a potential source of infection in the orthopedic operating theater?	Brennan SA[1], Walls RJ, Smyth E, Al Mulla T, O'Byrne JM.	Acta Orthop.	2009 Apr; 80(2):251-5.	Bacteria commonly implicated in surgical site infections such as coagulase-negative staphylococci, Staphylococcus aureus and Proteus spp. were prevalent. We also found a resistant strain of Acinetobacter and Candida.	Infectious organisms reside on the tourniquets and exsanguinators presently used in the orthopedic theater. These fomites may possibly be a source of surgical site infection.
The effect of sterile versus non-sterile tourniquets on microbiological colonisation in lower limb surgery.	SM Thompson, M Middleton, M Farook, A Cameron-Smith, S Bone, and A Hassan	Ann R Coll Surg Engl.	2011 Nov; 93(8): 589–590.	Thirty-four (34) non-sterile tourniquets were sampled prior to surgical application, twenty-three of which were contaminated with several different organisms including coagulase-negative *Staphylococcus* spp, *Staphylococcus aureus*, *Sphingomonas pau-cimobilis*, *Bacillus* spp, and coliforms. Thirty-six sterile tourniquets were used, with no associated contamination.	There was significant contamination of 68% of orthopaedic surgical tourniquets. These are used regularly in procedures involving the placement of prosthesis and metalwork, and can act as a potential source of infection. We recommend the use of sterile single-use disposable tourniquets where possible. The availability of an alternative should now set the new standard of care and we recommend adopting this as a current NICE guideline for control of surgical site infection.

Microbial colonisation of orthopaedic tourniquets: A potential risk for surgical site infection.	SK Sahu[1], B Tudu[2], PK Mall[2]	Indian J Med Microbiol	2015: 33: 115-118	It was observed that the tourniquets were colonised with coagulase-negative staphylococci, *Staphylococcus aureus, Bacillus,* diphtheroids, *Pseudomonas, Acinetobacter,* enterococci, enterobacteria, and *Candida*	All the tourniquets were colonised with microorganisms. Colony counts from different spots of the untreated tourniquets ranged from 15 to 68 colonies per spot. The inner surfaces of the tourniquets were more contaminated than the outer surfaces (1459 against 1030 colony counts). Proximal aspects were more contaminated than the distal aspects (1382 against 1107 colony counts).

It is clear from the above literature review that nearly all non-sterile tourniquets are contaminated with pathogens.

Methods that are currently used to mitigate the risk of contaminating the surgical site

The most commonly used method is to place the pneumatic tourniquet as far away as possible from the incision site. For example, the tourniquet is placed on the thigh for a foot case or on the upper arm for a hand case. The tourniquet is wrapped or covered by a sterile drape which creates a bacterial barrier when intact. The recommendation to clean the tourniquet between cases with a bacteriocydic solution is seldom adhered to in most ORs.

Methods to avoid transmission of pathogens from one patient to another

Reusable pneumatic cuffs are padded with an absorptive soft material (e.g. Web Roll) and/or cuff covers. No data are available on the effectiveness of such pads in blocking the spread of pathogens from one patient to another.

Methods to protect the OR staff against contamination by tourniquets.

Given the fact that almost all non-sterile pneumatic tourniquets are contaminated and typically stored in an open basket (photo), it is advisable that the OR personnel handling them and place them on the patient will do so with sufficient protection. Unfortunately, this is not always the case.

Critique and Discussion

The incidence of Surgical Site Infection continues to be high, ranging from 0.72% to 1.4% in 3 recent clinical-epidemiological studies of SSI in TKA ( ). This translates to between 7 and 14 deep SSI cases per thousand TKA patients. Unfortunately there are no studies that looked at the incidence of SSI post TKA with sterile vs. non-sterile tourniquets. There is one study in bilateral TKA (Demirkale et Al, J. Arthroplasty, 2014 Volume 29, Issue 5, Pages 993–997) that showed a drop from 1.3% to 0.4% in post TKA Deep SSI (p=0.11) when non-sterile pneumatic tourniquet was replaced by a sterile elastic exsanguination tourniquet. Clearly, additional studies are needed in order to determine if using non-sterile pneumatic tourniquets are safe to use.

SSI is debilitating and very expensive with the cost coming to be $50,000 - $70,000 per patient. If the incidence of SSI is reduced by only one case per 1000, it is easy to see that the saving can be $50 - $70 per case which is roughly the cost of each sterile single-patient use tourniquet.

Conclusion

Based on the literature published in the last few years reusable pneumatic tourniquets are contaminated with pathogens which may cause surgical site infection. These publications are not cited in the current AORN Guidelines on safe tourniquet use and should be considered new evidence that justify a mid-term evaluation of the subject matter. We recommend that the committee will act to consider these new evidence-based data and move to amend its guidelines to include a requirement that tourniquets used in the OR for limb surgical procedures will always be **sterile**.

Bibliography

Incidence of Surgical Site Infection

1. Levent T[1], Vandevelde D, Delobelle JM, Labourdette P, Létendard J, Lesage P, Lecocq P, Dufour M. Infection risk prevention following total knee arthroplasty. Orthop Traumatol Surg Res. 2010 Feb;96(1):49-56.

   The incidence of infection was 1.4%...

2. Sewick A[1], Makani A, Wu C, O'Donnell J, Baldwin KD, Lee GC. Does dual antibiotic prophylaxis better prevent surgical site infections in total joint arthroplasty? Clin Orthop Relat Res. 2012 Oct; 470(10):2702-7.

   During this period, there were 22 SSIs (1.2%)…

3. Robert S. Namba, MD, Maria C.S. Inacio, MS, and Elizabeth W. Paxton, MA Investigation performed at the Department of Surgical Outcomes and Analysis, Kaiser Permanente, San Diego, California. Risk Factors Associated with Deep Surgical Site Infections After Primary Total Knee Arthroplasty An Analysis of 56,216 Knees. J Bone Joint Surg Am. 2013;95:775-82

   Incidence of deep surgical site infection was 0.72% (404/56,216).

Tourniquet guidelines

4. http://www.guideline.gov/content.aspx?id=47825&search=tourniquet+single+use+cleaning+2014

Tourniquet colonization studies

1. Walsh EF[1], Ben-David D, Ritter M, Mechrefe A, Mermel LA, DiGiovanni C. Microbial colonization of tourniquets used in orthopedic surgery. Orthopedics. 2006 Aug; 29(8):709-13.

   "Tourniquet contamination may be a risk factor for the development of surgical site infection in orthopedic surgery."

2. Ahmed SM[1], Ahmad R, Case R, Spencer RF. A study of microbial colonisation of orthopaedic tourniquets. Ann R Coll Surg Engl. 2009 Mar;91(2):131-4

   "All sampled tourniquets were contaminated with colony counts varying from 9 to > 385. Coagulase-negative Staphylococcus spp. were the most commonly grown organisms from the tourniquets (96%). Some tourniquets had growths of important pathogens including methicillin-resistant Staphylococcus aureus (MRSA), Pseudomonas spp., and S. aureus."

3. Brennan SA[1], Walls RJ, Smyth E, Al Mulla T, O'Byrne JM. Tourniquets and exsanguinators: a potential source of infection in the orthopedic operating theater? Acta Orthop. 2009 Apr; 80(2):251-5.

   "Bacteria commonly implicated in surgical site infections such as coagulase-negative staphylococci, Staphylococcus aureus and Proteus spp. were prevalent. We also found a resistant strain of Acinetobacter and Candida."

4. SM Thompson, M Middleton, M Farook, A Cameron-Smith, S Bone, and A Hassan The effect of sterile versus non-sterile tourniquets on microbiological colonisation in lower limb surgery. Ann R Coll Surg Engl. 2011 Nov; 93(8): 589–590.

   "Thirty-four non-sterile tourniquets were sampled prior to surgical application, twenty-three of which were contaminated with several different organisms including coagulase-negative *Staphylococcus* spp, *Staphylococcus aureus*, *Sphingomonas pau-cimobilis*, *Bacillus* spp, and coliforms. Thirty-six sterile tourniquets were used, with no associated contamination."

5. SK Sahu[1], B Tudu[2], PK Mall[2] Microbial colonisation of orthopaedic tourniquets: A potential risk for surgical site infection. Indian J Med Microbiol 2015: 33: 115-118

   "It was observed that the tourniquets were colonised with coagulase-negative staphylococci, *Staphylococcus aureus, Bacillus,* diphtheroids, *Pseudomonas, Acinetobacter,* enterococci, enterobacteria, and *Candida*."

Exsanguinating tourniquet assessed

Consultant orthopaedic surgeon **MATTHEW S HENDERSON** FRCS (Trauma and Orthopaedics), MBChB, describes how the The S-MART™ sterile exsanguinating tourniquet from Summit Medical shows significant potential for improving efficiency in ankle surgery at Gloucester Royal Hospital.

The use of tourniquets for both upper and lower limb surgery has been common practice in amputations for many centuries.

However, although methods of exsanguination used today (such as limb elevation and the Esmarch bandage) appear to date back to the early 19th Century, it was not until around 1860 that the use of bloodless surgery was first applied, by Joseph Lister, in procedures other than amputations.

Exsanguinating the limb prior to surgery holds numerous advantages including establishing a clear operating field, reducing overall blood loss and reducing the risk of micro-emboli on tourniquet release.

The limb is usually exsanguinated through elevation, Esmarch bandage or Rhys-Davis techniques. The tourniquet is then applied to the limb to prevent the blood from returning to the exsanguinated limb during surgery. The tourniquet is usually a pneumatic cuff, which is placed on the upper arm or thigh and is inflated by a machine to a pre-determined pressure.

This pressure is typically 200-250 mmHg for upper limbs and 300-350 mmHg for lower limbs, although this may vary with limb size and the systolic pressure of the patient. The idea is to provide a clear bloodless field throughout the duration of surgery.

TOURNIQUET TECHNIQUES

Using the current methods employed at Gloucester Royal Hospital, the patients undergoing foot and ankle surgery receive a regional block at the knee with a pressure tourniquet placed on the upper thigh, at 350 mmHg, after exsanguination by elevation.

'Exsanguinating the limb prior to surgery holds numerous advantages.'

Applying S-MART.

The thigh is chosen as a placement site in order to keep the non-sterile pressure tourniquet well away from the surgical site, therefore reducing the risk of cross-infection. So while the patient feels no pain at the surgical site, he or she routinely requires further anaesthesia due to the discomfort experienced from the pressure tourniquet.

NEW APPROACH

We have recently employed the use of a new type of tourniquet called the S-MART™. This is a single use and sterile tourniquet that exsanguinates on application and occludes arterial flow at its placement site.

By using the sterile S-MART, a more distal placement site is possible (15 cm proximally to the lateral malleolus) without increasing the risk of infection. Not only does this reduce the volume of ischemic tissue but the tourniquet pressure is applied within the anaesthetised area. The theory is that the use of this method reduces the need for the subsequent general anaesthetic often required to alleviate pain created by the pressure tourniquet on the thigh.

The evaluation of S-MART was performed in order to assess the feasibility of a more detailed and statistically significant study aimed at assessing its use as an alternative method to the current utilisation of pressure tourniquets. The key variables identified for assessment from further evaluation are: patient wellbeing and recovery, use of appropriate anaesthesia and occurrences of complications. The information in this text summarises the evaluations that have taken place so far at Gloucester Royal Hospital and the conclusion as to the feasibility of a further and more detailed study.

EVALUATIONS

The initial evaluation of S-MART was carried out in March 2006 during a carpel tunnel release performed on a 43 year old woman under local anaesthetic. The new tourniquet was placed mid-forearm following the preparation of the limb, and knife to skin was within 20 seconds of it being applied. The ability to site the device after preparation is due to the device sterility. The resulting shorter than normal duration between placement and incision means we were able to achieve a reduction in the overall tourniquet time. In this case, the tourniquet time was only seven minutes.

There were two further cases on the day. Case 1 (34 year old man) was a ganglion removal from the wrist and case 2 (32 year old man) a knee arthroscopy and debridement. Both procedures were performed under general anaesthetic. As with the carpel tunnel release, an excellent bloodless field was established using the new tourniquet and, in all cases, a satisfactory clinical outcome was achieved.

S-MART effectiveness demonstrated in ankle ligament surgery.

Due to the initial successes, we considered further procedures where the device could demonstrate clinical benefits. It was at this stage that the methods we currently employ for ankle surgery were highlighted and the potential use of the new tourniquet was centred around the possibility of reducing the need for additional anaesthetic by applying the device over the area covered by our regional anaesthesia.

So far to date we have completed two foot and ankle cases using the new tourniquet. Both local anaesthetic and regional block were employed and this allowed us to asses tolerance of the tourniquet and the ability of the device to reduce the need for GA.

The first case was the removal of a cyst from the toe of a 44 year old man under local anaesthetic. The S-MART was sited approximately 40 cm from the toes and by using the correct system delivered a pressure of 228 mmHg. This is considerably lower than the 350 mmHg routinely applied using a pneumatic tourniquet on the thigh.

The patient was prepped and draped and the new tourniquet was applied in the final moments before knife to skin, again allowing us to reduce tourniquet time. On this occasion the patient tolerated the tourniquet over a non-anaesthetised area for over 13 minutes and until the procedure was completed.

Family of S-MART devices.

The second case was an ankle arthroscopy and debridement on a 42 year old man. A clear bloodless field was achieved and, importantly, there was no requirement for additional anaesthetic during the surgery. The tourniquet time in this instance was 49 minutes, which was well tolerated as the device could be placed close to the surgical site over an anaesthetised area. This result would not have been achievable with a pressure cuff as the infection risk would have meant placing the pressure cuff on the thigh. The 49 minute duration with the cuff at 350 mmHg would certainly have resulted in severe patient discomfort and the subsequent need for general anaesthetic.

HOW THE DEVICE WORKS

The new tourniquet uses a simple yet innovative approach to limb exsanguination and arterial occlusion. The basis of the idea stems from the original Esmarch device invented by Johann T. Friederich von Esmarch in the 19th Century. The name Esmarch is today widely associated with the elasticated bandages used for limb exsanguination but the original Esmarch device was an altogether more innovative approach.

The Esmarch device was a rubber tube that was wound tightly around the limb and then moved proximally using a wooden roller. This process provided consistent pressure leading to good exsanguination but the device then also served as a tourniquet at the appropriate placement site. The new tourniquet uses a similar idea in order to encapsulate the exsanguination and tourniquet properties in a single device.

In the case of S-MART, the rubber tube is replaced by a silicone ring, the tensile properties of which vary by device type, depending on the force required to generate the appropriate internal pressures. The type of device chosen will therefore be dictated partly by the patient's systolic pressure. The device's pull straps facilitate placement and a stockinette unravels during application in order to provide a sterile barrier.

The dimensions of patients' limbs vary as does their systolic pressure. An understanding of both is required to ensure that the correct S-MART is chosen for surgery. So, the device is available in different sizes for upper and lower limbs. There are also two other sizes that may be appropriate for extreme limb dimensions – one is for small or paediatric limbs and the other is for oversized limbs.

So, before selecting the device, the limb circumference at the desired placement site must be measured along with the patient's systolic pressure. Using charts supplied by the manufacturer, the most appropriate device can be identified (Fig. 1). The device should be offered into the sterile field using a normal aseptic technique. There is a plastic card inside the device. This card is

also sterile and must be retained as it is used to protect the patient's skin on removal of the device post-operatively.

The sterile device is opened using normal aseptic technique. The patient's fingers or toes are placed into the device aperture and the straps pulled proximally along the limb. Exsanguination takes place during proximal movement of the device as does the application of the stockinette. The device must be stopped at the pre-identified placement site to ensure that the selected system is still operating within its dimensional capabilities. From here, the stockinette can be cut away, or a window opened through it at the surgical site. Pressure charts provided by the manufacturer allow the skin pressure to be recorded.

Device selection in our practice was largely dictated by the limb size and was usually independent of the patient's systolic pressure. The reason for this was because the tibialis posterior artery "hides" between the medial malleolus and the Achilles tendon. In order to ensure the most effective exsanguination and occlusion, the manufacturer recommends that the highest pressure system is always used under these circumstances (for us, this was usually the yellow system) and that it should be placed 15 cm above the lateral malleolus.

In order to remove S-MART, the retained card should be placed proximally, the device rolled over the corner of the card, and the ring cut gently with a scalpel.

Limb circumference	Patient blood pressure		
	<130 mmHg	<160 mmHg	<190 mmHg
S-MART SM pediatric arm and leg 14-28 cm	●		
S-MART 40 arm and ankle 24-40 cm	●	●	●
S-MART 60 leg 30-60 cm	●	●	●
S-MART XL leg 50-90 cm		◐	

Figure 1: Device selection chart.

CONCLUSIONS

In conclusion, my team at Gloucestershire Royal Hospital are currently investigating use of the S-MART in patients having foot and ankle surgery. We found the device to be better tolerated by patients undergoing shorter duration surgeries under local anaesthetic, and that the routine use of general anaesthetic, due to pressure cuff discomfort during ankle surgery, was avoidable.

The evaluations that have taken place so far lead us to believe that the device can provide clinical benefits to our patients, improve our processes in preparing the patients for surgery and reduce the cost of surgery by removing the routine use of general anaesthetic.

Further evaluations will take place in an attempt to quantify results and to demonstrate compliance to these hypotheses.

As such, the aims of further evaluations, in foot and ankle surgery, are likely to be as follows:

- To assess improvement to patient wellbeing.
- To reduce intra-operative tourniquet pain and reduce the need for additional general anaesthesia.
- To reduce average recovery time by reducing use of general anaesthesia.

We are confident that such aims are achievable by continuing to apply our new methods.

Carpal Tunnel Syndrome: Background Information for HemaClear® Product Specialists

Edith R. Gavriely

Abstract

Carpal Tunnel Syndrome (CTS) is the most frequent nerve compression affecting 0.3% of the population of whom 1/3rd (0.1%) requiring surgical release – Carpal Tunnel Release (CTR) each year. It is caused by crowding the median nerve in its passageway into the hand at the base of the palm. The symptoms are numbness, pain of the thumb and the middle fingers and weakness of the muscle at the base of the thumb. While non-surgical treatment is often tried, about a third of the patients require surgery, which is most often performed as an outpatient procedure under bleeding-free conditions and local anesthesia. The sterile Forearm HemaClear® is a safe and effective device for achieving optimal bleeding-free surgical field.

Etiology

The carpal tunnel is a narrow passageway which encloses nine flexor tendons to the fingers and thumb and the median nerve, on the palm side of the wrist (5 Mayo p.1). The median nerve provides sensation to the first 3 ½ fingers (not the pinky) and motor function to hand muscles (thenar). There is minimal space to contain the median nerve and nine tendons (8 Solomon p.119) as they pass from the forearm into the hand (3 ASSH p.1). The specific cause of Carpal Tunnel Syndrome (CTS) is usually unknown (3 ASSH p.1).

Pathogenesis

Compression of the median nerve results in CTS. “In general, anything that crowds, irritates or compresses the median nerve in the carpal tunnel space can lead to carpal tunnel syndrome” (5 Mayo p. 2). As such CTS develops when pressure is placed on the median nerve. In laymen’s terminology – it is a pinched nerve in the wrist (5 Mayo p.1). Pressure is created in several ways: swelling of the lining of the flexor tendons (tenosynovitis), joint dislocations, fracture and arthritis, having a bent wrist for extended periods, fluid retention during pregnancy, thyroid conditions, rheumatoid arthritis, and diabetes. It may also result as a combination of causes (3 ASSH p.1). The anatomy of the wrist can also be a contributing factor; a smaller carpal tunnel has less room to accommodate any swelling (5 Mayo p. 2).

Risk Factors

Small anatomy may provide a predisposition to CTS, as there is little room to accommodate any swelling that may develop. Industrial – assembly line work - and cleaning employment with repeated movement of hand and/or vibration may cause trauma leading to CTS (2 Canale p.4285). It was believed that office workers were prone to CTS but this is “controversial and unresolved” (2 Canale p.4285). “In fact CTS is three times more common among

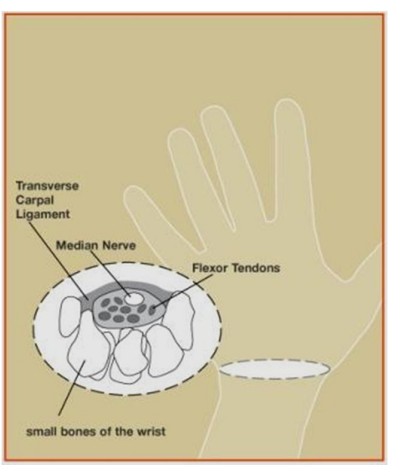

Figure 1. *The carpal tunnel is found at the base of the palm. It is formed by the bones of the wrist and the transverse carpal ligament. Increased*

©2012 OHK Medical Devices – HemaClear®

assemblers than among data-entry personnel. A 2001 study by the Mayo Clinic found heavy computer use (up to 7 hours a day) did not increase a person's risk of developing carpal tunnel syndrome" (6 NINDS p. 2).

Epidemiology

CTS patients are usually between 30 – 60 years old and the syndrome is two to three times more prevalent in women than men (2 Canale p.4285). It may affect 1%-10% of the US population. (2 Canale p.4285). CTS is the most common peripheral neuropathy (4 SYMP p. 202).

Clinical Symptoms

CTS can be mild to very painful and usually presents every night, disturbing ability to sleep. The most frequent symptoms include pain and paresthesia - burning, numbness, tingling or a combination of the three in the median nerve distribution. Patients try to relieve the symptoms by shaking the arm or hanging it over the side of the bed (8 Solomon p.119). Pain usually does not keep the patient from falling asleep, but typically awakens him/her. Symptoms can also appear during the day and can effect ability to grip a cup or hold a telephone or newspaper, with a tendency to drop things (3 ASSH p. 1). Holding the wrist in a flexed position for an extended period of time can expedite the pain (7 Skinner p.560). The pain can radiate from the hand up the arm, to the shoulder or neck. If not treated, sensation and use of muscles at base of thumb can be permanently damaged (3 ASSH p1).

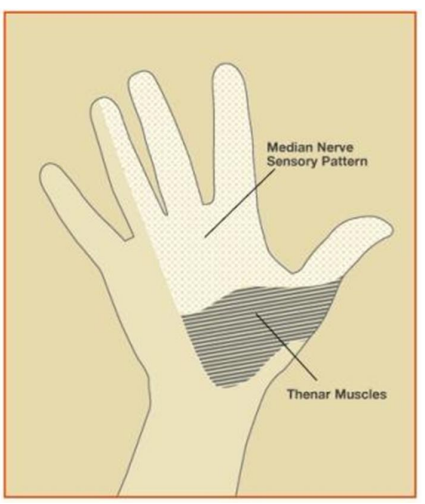

***Figure 2**. Aspects of median nerve function. (3)*

Diagnostics

Early diagnosis of CTS is vital to prevent permanent damage to the median nerve. The diagnosis is based on clinical and physical symptoms. The physical exam includes examination of hands, arms, shoulders and neck. "The wrist is examined for tenderness, swelling, warmth, and discoloration. Each finger should be tested for sensation, and muscles at the base of the hand should be examined for strength and signs of atrophy. Routine laboratory tests and X-rays can reveal diabetes, arthritis and fractures." X-rays can ascertain if there are other causes for the symptoms (6 NINDS p.2). Differential diagnosis is of utmost importance so as to eliminate other causes of similar symptoms. Diagnostics include provocation tests which try to reproduce the symptoms:

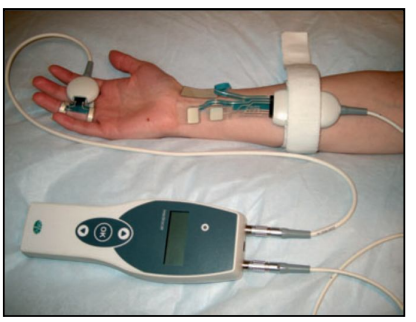

***Figure 3:** The handheld nerve conduction measuring device in use. (9)*

1 – Tinel nerve percussion over the median nerve;

2 – Phalen test – acute flexion of the wrist for sixty seconds;

3 – wrist compression test – pressure over the median nerve proximal to the wrist, to provoke symptoms within thirty seconds (2 Canale p. 4286);

4 – electrodiagnostic studies – NCV - nerve conduction velocity and EMG electromyogram;

©2012 OHK Medical Devices – HemaClear®

5 – novel handheld nerve conduction measuring device – a new diagnostic device to accurately and objectively determine severity of CTS by measuring nerve conduction velocity. The results obtained in this manner also facilitate differential diagnosis (9 Tolonen p.390).

In cases with late diagnosis there is atrophy to median innervated thenar muscles, weakness of thumb abduction and sensory dulling in median nerve (8 Solomon p119) which may not be reversible.

Treatment

Treatment should begin as early as possible. Underlying causes should be treated, eg., diabetes and hypothyroidism. The affected wrist should be given at least two weeks of rest. Light splints may be worn to prevent wrist flexion, particularly for people who sleep with bent wrists. (8 Solomon p.119). Applying cold packs and rest breaks at work may reduce swelling and bring relief (5 Mayo p.4).

Nonsurgical Therapy

Drugs – Nonsteroidal anti-inflammatory drugs (NSAIDs) may help reduce swelling temporarily (2 Canale p. 4287). They may be effective short term but it has not been shown that they actually improve the carpal tunnel syndrome itself (5 Mayo p.5). Corticosteroids can be injected directly into the wrist to provide temporary relief. They reduce inflammation and swelling which in turn relieve pressure on the median nerve. Oral corticosteroids are not as effective as injection. Diuretics may also reduce swelling (5 Mayo p.5).

Exercise – Physical and occupational hand therapy with stretching and strengthening exercise, as well as changing pattern of hand use , may bring relief (3 ASSH p.1). High-intensity ultra sound may also provide relief by raising body temperature and promoting healing (5 Mayo p.6).

Alternative treatments – Acupuncture and chiropractic may be helpful but as yet their efficacy has not been proven. Additionally, “Yoga postures designed for strengthening, stretching and balancing each joint in the upper body, as well as the upper body itself, may help reduce the pain and improve the grip strength of people with CTS” (5Mayo p.6).

Surgery

CTS surgery is a very common procedure in the US. It is a very effective treatment for CTS (9 SYMP p. 201). If symptoms do not respond to non-surgical treatment, surgery is indicated (6 NINDS p.3). It is an ambulatory procedure under local anesthesia. The time at which to recommend surgery is still under debate. The Mayo Clinic staff claims that conservative treatment – non-surgical – may be effective if there are mild to moderate symptoms for less than ten months (5 Mayo p.4). According to the Symposium on the Wrist and Hand, surgery should be considered if conservative treatment of mild and moderate CTS do not bring relief within three months (4 SYMP p.202). The National Institute of Neurological Disorders recommends surgery if symptoms last for more than six months (6 NINDS p.3). Persons with severe symptoms should be referred to surgery immediately (4 SYMP p. 202).

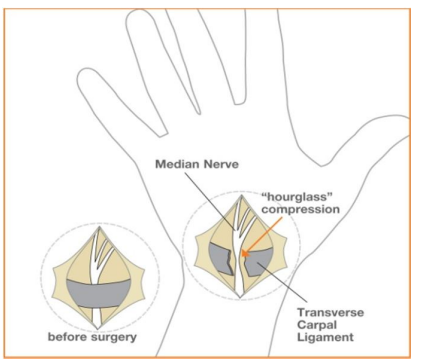

Figure 4: *The goal of surgery is to free the ligament to allow more room for the median nerve in the carpal tunnel. (3)*

Pressure on the median nerve is reduced by cutting the ligament that forms the roof of the tunnel on the palm side of the hand (3 ASSH

©2012 OHK Medical Devices – HemaClear®

p.3). One option is standard open release surgery to divide the transverse carpal ligament at the wrist. A skin incision of up to two inches is made in order to identify and cut the carpal ligament and enlarge the carpal tunnel (6 NINDS p.3). It is done "under direct vision ensuring a safe and complete release. It is the oldest and most commonly used technique…and normally takes less than fifteen minutes." (4 SYMP p.201). Mini-open release surgery was developed to decrease problems of sensitivity following standard open release surgery (4 SYMP p.201). Endoscopic surgery is an alternative option. In this procedure the surgeon makes two incisions (about ½ inch each) in the wrist and palm, inserts a camera attached to a tube, observes the tissue on a screen and cuts the carpal ligament" (6 NINDS p.3). Post-operative recovery rehabilitation from the latter is quicker, but the surgery sometimes misses cutting the entire ligament due to poor visibility (4 SYMP p.201). Nearly all CTS release operations are performed with a tourniquet placed on the upper arm or on the forearm to prevent bleeding and improve visibility. The traditional pneumatic tourniquet is being replaced now by a new elastic exsanguination tourniquet (1 Boiko p.185) Hemaclear®, OHK Medical Devices, Ltd., Haifa, Israel, which is sterile and provides better visibility. Anesthesia is usually by local infiltration of Lydocaine or similar local anesthetics.

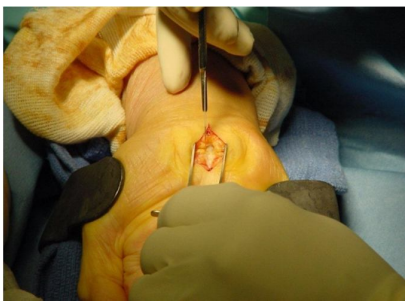

Figure 5. *Carpal Tunnel Release incision in an elderly woman. With permission OHK Medical Devices, Ltd.*

Figure 6. HemaClear® exsanguination tourniquet in use during CTR. With permission OHK Medical Devices, Ltd.

Prognosis

CTS symptoms are relieved after surgery, however full recovery can take months. Complications that may occur following CTS surgery include infection, nerve damage, stiffness, and pain at the scar. Occasionally the wrist loses strength. Recurrence is rare (6 NINDS p.3). Most patients (85%) benefit from surgery with lasting relief of CTS. However, patients over 70 years of age may not attain total relief (2 Canale p.4289).

Summary

In conclusion, CTS is a common neuropathy that affects women three times more than men. It can present with mild, medium or severe symptoms. The former may respond to conservative treatment; the latter necessitates surgical intervention. Not treating severe CTS may lead to irreversible thenar muscle atrophy.

Acknowledgement*: Prepared in partial fulfillment of requirements – Reidman Academy, Dr. Amit Hadari, supervisor.*

©2012 OHK Medical Devices – HemaClear®

Bibliography

1. Boiko. M and Roffman, M, "Evaluation of a Novel Tourniquet Device for Bloodless Surgery of the Hand," Journal of Hand Surgery (British and European Volume, 2004) 29B: pp. 185-187.
2. Canale, Terry S, MD, and Beaty, James H., MD, "Carpal Tunnel Syndrome," Campbell's Operative Orthopaedics, Eleventh Edition, Vol. IV, 2008, pp. 4285– 4298.
3. "Carpal Tunnel Syndrome," American Society for Surgery of the Hand, www.assh.org, 2011, pp. 1-3.
4. "Carpal Tunnel Syndrome: Symposium on the Wrist and Hand, British Journal of Hospital Medicine, April 2012, Vol. 73, No. 4, pp. 199-202.
5. "Carpal Tunnel Syndrome," MayoClinic.com, Feb.22,2011, pp. 1-8.
6. "Carpal Tunnel Syndrome Fact Sheet," National Institute of Neurological Disorders and Stroke, www.ninds.nih.gov/disorders/carpal_tunnel/detail_carpal_tunnel.htm, Feb. 13,2012, pp. 1-5.
7. Skinner, Harry B, MD, PhD, ed., "Median Neuropathy," Current Diagnosis & Treatment in Orthopedics, 2006, pp. 560-563.
8. Solomon, Louis MB, ChB, MD,FRCS and Warwick, David, MD, BM, FRCS and Nayagam, Selvadurai, BSc, MCh,FRCS, "Carpal Tunnel Syndrome." Apley's Concise System of Orthopaedics and Fractures, Third Edition, 2005, pp. 118-120.
9. Tolonen,U, Kallio,M, Ryhanen,J, Raatikainen,T,Honkala,V, Lesonen,V, and The Study Group, "A handheld nerve conduction measuring device in carpal tunnel syndrome," Acta Neurologica Scandinavia, 2007, vol. 115: pp. 390-397.

©2012 OHK Medical Devices – HemaClear®

Forearm Sterile Elastic Tourniquet – A Preferred Method For Carpal Tunnel Release (CTR)

Noam Gavriely, MD, DSc.

Chief Medical Officer, OHK Medical Devices - HemaClear®, Haifa, Israel

Abstract

Carpal Tunnel Release (CTR) is one of the most common surgical procedures performed in the US. A key to a successful outcome of the procedure is good visibility. This is achieved by assuring a bloodless surgical field by applying an arterial tourniquet, or infiltrating the incision site with local anesthetics mixed with adrenalin. This paper describes the use of a sterile forearm elastic exsanguination tourniquet (FA-SET) as an alternative to the upper arm pneumatic cuff. The FA-SET is the superior choice in our view. It provides a sterile field, superior exsanguination and effective arterial blocking. The use of FA-SET should be the standard of care in small hand procedures and in particular when carpal tunnel release is performed.

Background

Carpal Tunnel Release (CTR) is one of the most common surgical procedures performed in the US. The incidence in 2000-2005 was 109 operations per 100,000 people each year (Gelfman, Neurology 2009), which translates to about 350,000 surgical procedures per year in the US. The direct cost of CTR was estimated in 2009 to be $3068 ± $983 or about $1.1 Billion per year (Pomerance, J Hand Surg 2009). CTR is a safe procedure with minimal complications (Patterson and Simmons, Hand Clinics, 2002) and surgical site infection is relatively uncommon, estimated as <0.5% irrespective of perioperative use antibiotics (Harnes et al, J Hand Surg., 2010).

The CTR procedure is quick, taking 10-12 minutes or less. It requires a very simple set of instruments and minimal draping and is most often performed in an outpatient day-surgery setting. However, a key to successful outcome of the procedure is good visibility. This is achieved by assuring a bloodless surgical field by applying an arterial tourniquet, or infiltrating the incision site with local anesthetics mixed with adrenalin (Ralte et al, The Open Orthopaedics Journal, 2010). This paper describes the use of a sterile forearm elastic exsanguination tourniquet as an alternative to the upper arm pneumatic cuff.

Structure and Function of the Forearm Sterile Exsanguination Tourniquet (FA-SET)

The Forearm Sterile Exsanguination Tourniquet (HemaClear, OHK Medical Devices Ltd. Haifa Israel) consists of an elastic silicone ring wrapped around by tubular stockinet and four straps terminated by two handles (App. Figure 1a). The FA-SET is placed on a conical application cup that helps in its placement on the fingers and the initiation of its rolling up the hand. The FA-SET is sterile (Ethylene Oxide treatment) and comes double wrapped in individual packs. When the straps are pulled proximally along the axis of the arm, the ring rolls over the hand, wrist and forearm and the stockinet is released to cover the skin (App. Figure 1b). The final position of the FA-SET is 10-12 cm above the root of the palm (App. Figure 1c). The rolling applies uniform circumferential force on the tissues, translated into radial pressure that effectively squeezes the blood out (exsanguination) and blocks the arterial flow into the hand. The application of the FA-SET is quick and smooth, taking 3-5 seconds to apply.

Prepping and Draping

©2012 OHK Medical Devices – HemaClear®

Disinfection is done in the usual manner up to, or beyond, the elbow. Draping for a CTR is done so that the edge of the drape is wrapped around the forearm about 5-8 cm above the root of the palm. As such, the FA-SET is rolled on top of the edge of the drape so that a continuity of draping is assured between the sterile stockinet of the device and the proximal drape. Exposure of the incision site can be done by cutting a window in the stockinet, or by folding the stockinet proximally thereby exposing the entire hand (App. Figures 1d, 1e).

At the end of the procedure the elastic ring is cut with a scalpel (scissors will not cut the silicone), after protecting the skin beneath the ring with the plastic card provided with the product (App. Figure 1f). It is important to also cut off the remnants of the stockinet to avoid venous occlusion and engorgement of the blood vessels. The cutting of the ring ("tourniquet down") can be done either prior to final hemostasis and suturing or after suturing and dressing of the incision site (see Discussion).

Experience with the FA-SET

We performed ___ CTR procedures with the FA-SET with no complications or side effects. The application of the device is quick and easy, and the exsanguination level is excellent. We usually cut the straps off, leaving about 10 cm of two of the straps to help pull and lift the ring for the placement of the protection card when cutting the ring. An important element in the process was the explanation to the patient of the importance of the use of the FA-SET to provide a bloodless field and optimal visibility. We described the constricting pressure of the tight ring and the discomfort to be expected. This was typically done while infiltrating the incision site with local anesthetics. In __% of the procedures the patient consented to the use of the device without forearm anesthesia. The device discomfort was tolerated well by the patients with a few words of encouragement from the team.

The Table below provides an item-by-item comparison between the pneumatic tourniquet and the FA-SET:

	Pneumatic Tourniquet	Forearm Sterile Exsanguination Tourniquet
OR Preparations	• Tourniquet cuff (select correct size) • Padding • Esmarch (if used) • Stockinet drape • Check pneumatic controller and tubing	• FA-SET (one size)
Preparation and application time	5-15 minutes	1-2 minutes
Capital equipment	Pneumatic controller	None
Pressure on tissue	As set by the user	225±25 mm Hg, factory set
Application by	OR Nurse/ technician	Surgeon
Sterility	Non-sterile or sterile	Sterile - single use
Tourniquet placement site	Upper arm if not sterile; upper arm or forearm if sterile	Forearm
Anesthesia	Local infiltration	Same
Procedure	Dissection of tunnel and cutting of transverse ligament	Same
Removal	Deflation of cuff	Cutting of ring

©2012 OHK Medical Devices – HemaClear®

Discussion

The FA-SET is a sterile, single use item. As such, it can safely be used on the forearm about 10 cm (4") from the incision. The forearm positioning of a tourniquet has previously been shown to be tolerated much better by the patients when compared to the upper arm position (Hutchinson, J Hand Surg Am., 1993; Glynn, Ir Med J, 2005; Maury, J Hand Surg Br., 2002; Edwards, J Hand Surg Br, 2002; Yousif, J Hand Surg Br., 1993). These studies, performed with pneumatic tourniquets, were done in volunteers and in actual patients. The outcome of these studies clearly shows that a forearm tourniquet placement is safe, effective, and uniformly better tolerated by the patient.

When the SET (forearm or upper arm) was compared to the pneumatic tourniquet, "the silicone ring tourniquet (SET) was associated with a significantly lower pain score than the pneumatic tourniquet. The incidence of parasthesia was also lower with the silicone ring tourniquet. When applied to the forearm, there was no statitstically significant difference in pain scores between the two types of tourniquets. However, the incidence of parasthesia was lower with the silicone ring tourniquet" (Mohan, J Hand Surg Eur, 2011). However, when the upper arm pain and parasthesia scores at the 10 minutes mark are compared to the corresponding forearm scores, the differences are very large with the pain score of the silicone ring (SET) being 1.9±1.2 on the forearm vs. 3.7±2.3 on the upper arm, and 5.7±2.5 with the pneumatic tourniquet on the upper arm.

Mohan et al. 217

Table 1. Pain scores and presence of paraesthesia, values are given as mean (SD)

	1 minute	5 minutes	10 minutes	*p*-value (10 mins)
Pain scores at upper arm				
Pneumatic tourniquet	4.0 (1.5)	4.3 (1.6)	5.7 (2.5)	<0.01
Silicone ring tourniquet	4.7 (1.6)	3.1 (1.6)	3.7 (2.3)	
Paraesthesia at upper arm				
Pneumatic tourniquet	0.3 (0.5)	1.2 (0.5)	3.2 (0.5)	<0.01
Silicone ring tourniquet	0.1 (0.22)	0.3 (0.2)	0.8 (0.4)	
Pain scores at forearm				
Pneumatic tourniquet	4.1 (1.6)	4.3 (1.7)	2.3 (1.7)	0.09
Silicone ring tourniquet	5.5 (1.1)	3.5 (1.5)	1.9 (1.2)	
Paraesthesia at forearm				
Pneumatic tourniquet	0.5 (0.5)	0.7 (0.5)	0.8 (0.4)	<0.01
Silicone ring tourniquet	0.1 (0.2)	0.2 (0.4)	0.2 (0.4)	

In another study, the tolerance duration of the SET and pneumatic tourniquet, both placed on the upper arm, were compared (Drosos, Arch Orthop Traum Surg, 2011). There were no differences in duration tolerance between the wide pneumatic tourniquet and the narrow SET ring.

Another aspect that is readily observed when the FA-SET is used is its superior exsanguination. The surgical incision is completely bloodless. This is evident in the obviation of blood-stained "four-by-four" sponges. In fact, the use of the bipolar diathermia is almost eliminated when the FA-SET is used. The improved visibility of the dissected soft tissues of the palm seems to have a positive effect on the accuracy of the median nerve release and speeds up the process. It is not possible to perform a blinded study of the surgical duration, but our opinion is that the FA-SET facilitates shorter tourniquet time, skin incision-closure time and overall OR time.

©2012 OHK Medical Devices – HemaClear®

The pertinent question is therefore why upper arm tourniquet is still in use? It is conceivable that in many hospitals, the tourniquets are not sterile and as such carry a heavy bacterial load with multiple pathogens). The negligible cost differential between a sterile and non-sterile tourniquet (i.e. not more than 1% of the overall cost of the procedure) seems to be the driving force. We feel that the presumed added cost is readily offset by the reduced perioperative logistics, increased OR throughput and the improved overall patient experience, particularly when the FA-SET is used.

Summary and Conclusions

The literature, as well as our own experience, clearly shows that forearm tourniquet position is the preferred site for short hand procedures done under local anesthesia. In order to do so without risk of contamination, the tourniquet must be sterile. The FA-SET is the superior choice in our view. It provides a sterile field, superior exsanguination and effective arterial blocking. It is tolerated well by most patients and is quick to apply. It is cost-effective compared to the sterile pneumatic tourniquet, particularly when the cost of the additional items needed when the pneumatic tourniquet is used is taken into account. The elimination of the capital cost and calibration requirements of the pneumatic controller are added benefits. The use of FA-SET should be the standard of care in small hand procedures and in particular when carpal tunnel release is performed.

Bibliography

1) Drosos GI, et al. Silicone ring versus pneumatic cuff tourniquet: A comparative quantitative study in healthy individuals. Arch Orthop Traum Surg. 2011;131(4):447-454.
2) Edwards SA, et al. Efficacy of forearm versus upper arm tourniquet for local anaesthetic surgery of the hand. J Hand Surg Br. 2000;25(6):573-4.
3) Gelfman R, et al. Long-term trends in carpal tunnel syndrome. Neurology. 2009;72(1):33-41.
4) Glynn A, et al. Carpal tunnel release using local anaesthetic and a forearm tourniquet. Ir Med J. 2005;98(5):144-5.
5) Harnes NG, et al. Rate of infection after carpal tunnel release surgery and effect of antibiotic prophylaxis. J Hand Surg. 2010;35(2):189-96.
6) HemaClear® [homepage on the internet]. Haifa: OHK Medical Devices; c2010.
7) [cited 2012 Aug 11]. Available from: http://www.hemaclear.com/
8) Hutchinson DT, McClinton MA. Upper extremity tourniquet tolerance. J Hand Surg Am. 1993;18(2):206-10.
9) Maury AC, Roy WS. A prospective, randomized, controlled trial of forearm versus upper arm tourniquet tolerance. J Hand Surg Br. 2002;27(4):359-60.
10) Mohan A, et al. Pain and paraesthesia produced by silicone ring and pneumatic tourniquets. J Hand Surg Eur. 2011;36(3):215-8.
11) Patterson J, Simmons BP. Outcomes assessment of carpal tunnel syndrome. Hand Clin 2002;18:359 –363.
12) Pomerance J, et al. The cost-effectiveness of nonsurgical versus surgical treatment for carpal tunnel syndrome. J Hand Surg Am. 2009;34(7):1193-200.
13) Ralte P, et al. Haemostasis in open carpal tunnel release: Tourniquet vs local anaesthetic and adrenaline. The Open Orthopaedics Journal. 2010;4:234-236.
14) Yousif NJ, et al. A comparison of upper arm and forearm tourniquet tolerance. J Hand Surg Br. 1993;18(5):639-41.

©2012 OHK Medical Devices – HemaClear®

Appendix - Images

Figure 1a

Figure 1b

Figure 1c

Figure 1d

Figure 1e

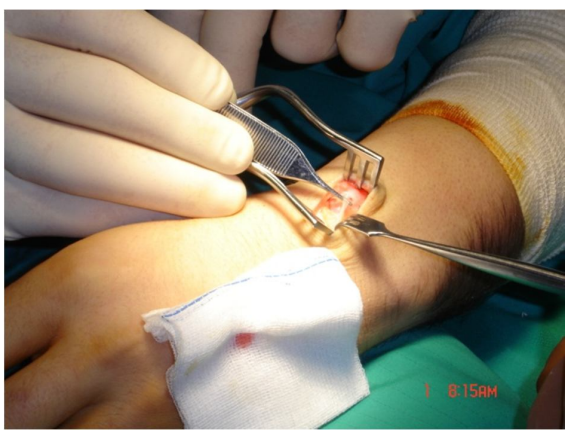

Figure 1f

©2012 OHK Medical Devices – HemaClear®

Tourniquet and the Obese Patient

White Paper

Prepared for OHK Medical Devices

By

Prof. Noam Gavriely
Scott Freer
Navit Suchard
Oren Gavriely

Abstract

More than a third of patients undergoing TKA have a BMI greater than 30 (obese) with many of these patients having a BMI that is greater than 40 (morbidly obese). Operating on these patients present the surgeon and the OR team with special problems all around, not the least of which is achieving and maintaining a blood-free surgical field. The problems include the need for larger and wider specialty (curved) cuffs thereby dangerously decreasing the distance from the distal edge of the tourniquet to the incision; tourniquets tend to slide distally when inflated due to the taper of the thigh; occlusion of arterial flow in the obese patient requires higher pressures, thereby causing more tissue compression (crush injury) and skin damage (1). Additionally, the obese patient is more vulnerable to infection if non-sterile tourniquets are used; the ability to expel the blood from the operated limb prior to tourniquet inflation is difficult in the obese patient, time consuming and tedious and often suboptimal, leaving substantial volume of blood in the vessels. This blood clots over the course of the tourniquet "up" period and when the tourniquet is deflated these clots travel to the pulmonary circulation (PE). The blood left behind also obstruct the surgical field visibility and the imperfect field requires additional OR time for hemostasis (2). Nevertheless, tourniquets are used in obese patients and the overall long term outcome of TKA in obese patients is as positive as in the normal BMI patients.

The HemaClear is a novel exsanguination tourniquet consisting of a rolling ring with an elastic stockinet and handles which can be applied quickly to the obese limb (picture). The HC90 is suitable for up to 90 cm of circumference which is suitable for most (but not all) obese patients. The HC provides a superior exsanguination, is a sterile, single patient use device and remains stable on the thigh (3). It applies safe levels of pressure to the limb and in more than 80,000 cases (all, not only obese) it has been used, proved to have an impeccable safety track record (no paralysis/paresis, no skin damage). The HC90 is a valuable addition to the tools designed to give the obese patient the same standard of care as the lean TKA recipient.

OHK Medical Devices Inc. / PO Box 269 / Belle Mead, NJ 08502-0269 / T: +1.888.824.2369 / info@hemaclear.com

Adverse Effects of Pneumatic Tourniquet in Obese Patients.

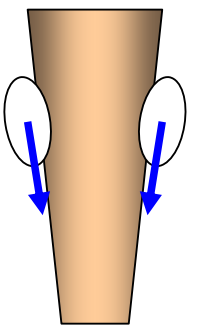

Achieving blood-free surgical field in the obese patient undergoing TKA is a challenge. It requires experience and skill and some special tools, such as extra padding and special size and shape tourniquet. The obese thigh is typically very wide, acutely tapered, and relatively soft. The skin is loose and the distance to the groin is small relative to the circumference. These geometrical become obvious when Figure 1 is considered. The forces applied by the tourniquet on the tapered limb have, in addition to the desired radial component, an axial vector (arrow) that tends to slide the tourniquet distally towards the surgical incision site. The loose skin makes this sliding even easier with a tendency to pull some skin folds along (4).

In addition to the geometrical mechanics, the wider thigh requires a wider cuff thereby leaving less "real estate" for the surgical incision. The migration of the tourniquet occasionally brings it to an undesired proximity to the sterile field (5). The use of sterile tourniquets is therefore recommended in all obese patients. The rheology of the obese tissues is another factor that must be considered, namely the compressibility of the adipose tissue is such that higher pressures are needed in order to transmit the pressure from the skin surface beneath the tourniquet to the vicinity of the blood vessel. The higher pressures, particularly with a flat profile cuff, create higher shear forces at the proximal and distal edges of the tourniquet thereby increasing the risk of neural or vascular damage.

The obese patient often has delicate skin and poor peripheral circulation. It is essential to minimize tourniquet time and to apply tourniquets in a very even way. Attempts to squeeze skin folds and fat beneath a tourniquet that is not long enough can be detrimental. Case reports on pneumatic-tourniquet intduced rabdomyolysis in obese patients are indicative of this higher vulnerability (6).

In addition to the challenges of tourniquet placement and maintenance of arterial occlusion, it is known that effectively expelling the blood from the limb (exsanguination) is quite difficult in the obese. Limb elevation is ineffective (7-Blond et al) and Esmarch bandage placement is tedious in the obese patient. The blood left behind inside the blood vessels tends to clot during the course of the procedure. Once the tourniquet is released, many of these clots travel with the blood flow to the lungs (Micro Pulmonary Emboli) while those who stay behind can form seeds for further thrombus formation and post op DVT.

OHK Medical Devices Inc. / PO Box 269 / Belle Mead, NJ 08502-0269 / T: +1.888.824.2369 / info@hemaclear.com

The HemaClear Solution

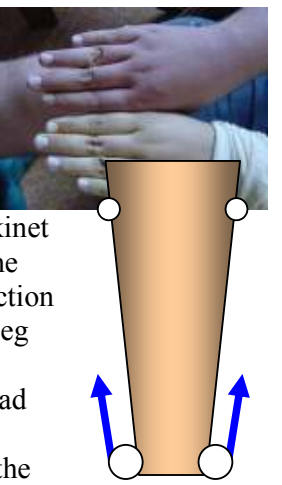

Recently, OHK Medical Devices (Haifa, Israel) brought to the orthopedic market a novel exsanguination tourniquet for limb blood-free surgery. The largest size of the series is the HC90, which was specifically designed for use on the obese patient. The HC technology consists of a highly calibrated elastic silicone ring with a latex-free stockinet wrapped around it. The HC90 also has 4 straps that when pulled along the axis of the limb cause the rolling of the ring along the limb. The construction of the HC90 is such that when it is placed on the distal-most part of the leg the annulus is thick and the hole in its middle is small to fit the narrower aspect of the leg. As the ring rolls up, the thick stockinet material is spread behind so that the annulus becomes narrower while the middle hole gets wider. The result is a uniformly applied pressure along the limb despite the widely changing circumference. The device is secured in place by wrapping the straps just distally to the ring so that it cannot roll back down despite motion of the knee and the underlying thigh tissues. At the end of surgery the HC ring is cut away by cutting the elastic ring. If there is a desire to minimize the drop of blood pressure after the release of the occlusion (due to the opening of the empty vascular bed in the leg) it is possible to leave the stockinet for a few additional minutes before cutting it away with scissors.

The HemaClear is applied quickly and easily on the prepped leg. It is applied immediately prior to the beginning of surgery thereby minimizing tourniquet time. The level of exsanguination is outstanding with a very dry field, despite the obesity (pictures).

The HC90 is sterile single-patient device and as such is suitable for use in the obese patient with its higher vulnerability to infection. The high exsanguination level also prevents leaving blood behind in the blood vessels, thereby reducing the likelihood of clotting and PE formation. The effect of the ring on the skin and the underlying tissues is

OHK Medical Devices Inc. / PO Box 269 / Belle Mead, NJ 08502-0269 / T: +1.888.824.2369 / info@hemaclear.com

gentle (arrow in pictures) and no undesired effects (tourniquet paralysis, tourniquet "burn", tourniquet pain) have been reported in its frequent use in Europe and other countries.

Conclusions

The problems with pneumatic tourniquets in the obese patients drove some researchers to the conclusion that it is better to operate on these patients under non blood-free conditions. However, the majority of major joint surgeons continue to use exsanguination and tourniquet technique while struggling with the difficulties.

The data from large scale studies compiled by the CDC indicate that the overall satisfaction of obese patients with the outcome of TKA is as high as in non-obese patients(8). As such, it seems logical to conclude that they deserve the same level of quality care, including the details of the intra-operative process. The HC90, which was specifically designed to meet the needs of the very obese patient, is a useful addition to the care of these patients.

References:

1. Gower SN, Beaumont AC .A burst sphygmomanometer cuff during intravenous regional anaesthesia. Anaesthesia. 1989 Dec; 44(12):1016-7.

2. Guss D, Bhattacharyya T. Perioperative Management of the Obese Orthopaedic Patient. J Am Acad Orthop Surg 2006 July; 14(7): 425-432.

3. Boiko M, Roffman M. Evaluation of a novel tourniquet device for bloodless surgery of the hand. Journal of Hand Surgery Br 2004 April; 29(2):185-187.

4. Krackow KA. A maneuver for improved positioning of a tourniquet in the obese patient. Clinical Orthopedics and related research 1982; 158:80-82.

5. Booth RE Jr. Total knee arthroplasty in the obese patient: tips and quips. J Arthroplasty 2002 Jun; 17(4 Suppl 1):69-70.

6. Karcher C, Dieterich HJ, Schroeder TH .Rhabdomyolysis in an obese patient after total knee arthroplasty. J Anaesth Br 2006 the thigh and the surgeon reported excellent exsanguination.

OHK Medical Devices Inc. / PO Box 269 / Belle Mead, NJ 08502-0269 / T: +1.888.824.2369 / info@hemaclear.com

7. Blond L., J.L. Madsen. Exsanguination of the upper limb in healthy young volunteers. The Journal of Bone and Joint Surgery Br 2002; 84:489–491.

8. Krushell RJ, Fingeroth RJ .Primary Total Knee Arthroplasty in Morbidly Obese Patients: a 5- to 14-year follow-up study. J Arthroplasty 2007 Sep; 22(6 Suppl 2):77-80.

OHK Medical Devices Inc. / PO Box 269 / Belle Mead, NJ 08502-0269 / T: +1.888.824.2369 / info@hemaclear.com

Moving to a new type of sterile and single use tourniquet for orthopaedic surgery

Author: Mr G P de Kiewiet, MBchB, FRCS, RCPS, FRCSEd, FRCSEd(Orth)

Introduction

Tourniquets are widely used in orthopaedic limb surgery in order to provide the surgeon with optimised visual capacity by creating a bloodless field followed by arterial occlusion proximal to the surgical site. We identified a number of potential patient risks in using the current methods, so, in order to reduce these risks, we felt the need to improve on our current bloodless surgery techniques. To help establish a mechanism for improving on our current methods, we evaluated a new type of sterile exsanguinating tourniquet called the S-MART, and found this, amongst other things, to reduce the preparation and tourniquet time, reduce cross infection risk and provide a first rate bloodless field in elective paediatric surgery.

In order to show the benefits of using this new device we need to consider the current methods of achieving exsanguination (removal of blood from a limb) and arterial occlusion, and the problems that can often arise with these methods.

How the current tourniquet method works

Historically tourniquets have been used routinely at Sunderland Royal Hospital in the Paediatric theatres. Development and implementation of tourniquet technology in limb surgery was established due to the need for a clear and bloodless field during the procedure. This is particularly relevant and important in paediatric cases as the type of surgery to which the tourniquet is applied, which is often intricate enough in adult cases, can increase in intricacy due to the smaller size of the patients' limbs. Further more the need to reduce blood loss is always important.

Traditionally, our method of achieving arterial occlusion was to apply a special, smaller, paediatric pressure cuff to the exsanguinated limb as a tourniquet. Exsanguination itself can be accomplished through various methods; limb elevation, Reece-Davis, Esmarch being the most popular techniques. At Sunderland Royal Infirmary, the preparation of the patient's limb generally takes place in the anaesthetic room prior to transfer into theatre.

This helps reduce the theatre time of the procedure but also leaves us with some more significant logistical problems that we felt could be avoided through the use of a different technique.

Disadvantages of the current method

In the paediatric cases, we usually start the patient's preparation by administering the anaesthetic. After the anaesthetic has been applied and the first preparatory stage of exsanguination has been performed, the pressure cuff must be inflated in order to occlude arterial flow and prevent blood from flowing back into the limb before surgery. We usually use tube or Reece Davis in order to achieve limb exsanguination and while this is being carried out, the pressure cuff is being prepared with its necessary padding and drapes, in order to provide as comfortable and aseptic field as possible. In most cases the patients are asleep on application and it is vital that all the necessary steps are taken to avoid the chances of skin burns from the fabric of the pressure cuff and contamination with the surgical prep fluids. Once the patient is padded and the surgical site protected from the chances of cross infection, inflation of the cuff concludes the initial preparation. After these activities, the limb is disinfected in the normal way prior to the first incision being made

In this instance, the patient is under anaesthesia for the duration of the preparation. The same surgical and logistical result can be achieved by preparing the cuff before anaesthetic, in order to reduce the anaesthetic time. However, this results in an increase in the tourniquet time and means that the patient would feel the discomfort of the tourniquet for a short time while the anaesthetic was being administered and may also increase the risk of damage to internal structures. This is something we wanted to try and avoid, particularly in paediatrics. Application prior to anaesthesia will also increase the anxiety levels in this group of patients.

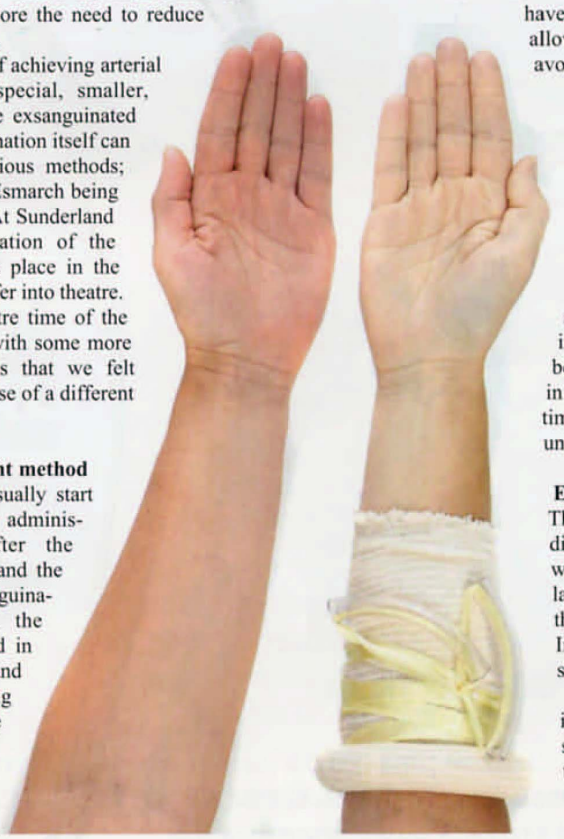

Avoiding increased anaesthetic and tourniquet time

Unfortunately, by using these methods, either the anaesthetic, or tourniquet time are extended, neither of which is particularly desirable but is, unfortunately, unavoidable when using a pressure cuff as a tourniquet.

However, with the S-MART™ exsanguinating tourniquet we have found an innovative yet simple solution that allows the tourniquet time to be reduced whilst avoiding an extension to the anaesthetic time.

In short, the traditional, separate methods of exsanguination, arterial occlusion and application of a sterile stockinette to the limb are encapsulated in the one device, which means that all of the required preparatory steps are achieved in one simple movement. However, adding to this is the fact that the device is sterile so it can be applied immediately after the disinfecting process. What this means is that the siting of the S-MART™ can be the last step before incision. It is by using this principle that we have been able to reduce the need for additional resource in the anaesthetic room and to reduce the tourniquet time whilst leaving the duration of anaesthesia unaffected.

Effective exsanguination and arterial occlusion

This device is relatively new in the UK and was discovered by members of our theatre nursing team whilst attending the AfPP Congress is Harrogate last year. The information with regards to the use of the device was brought back to Sunderland Royal Infirmary and we felt that this could be exactly the solution that we had been looking for.

Part of the initial attraction of the S-MART™ is its simple but innovative approach in finding a solution to the problems we face when using traditional tourniquet methods.

The device itself is comprised of a tensile silicone ring – the elasticity of which varies by

device type depending on what range of systolic pressures you wish to occlude - over which is rolled a long fabric stockinette. Into the stockinette is also rolled a set of straps with pull handles attached to the end. The idea is that fingers or toes of the patient are placed into the central hole of the device and, when in position, the straps are pulled, and the S-MART™ is rolled up the limb to the desired location. This process stretches the silicone ring, applying increasing pressure during lateral movement along the limb taper as the circumference of the limb increases. Blood is therefore squeezed from the limb to the point where the S-MART™ is sited. When the placement site is reached, the movement stops, resulting in a constant pressure, which ensures arterial occlusion.

As well as being sterile, the S-MART™ is much narrower than normal pressure cuffs which means that it can be placed closer to the surgical site without increasing the risk of cross infection. This is particularly useful when performing surgery on the elbow as the amount of room between the elbow and shoulder for pressure cuff placement is limited. It also means that there is less ischemic tissue as a lower volume of internal limb structure is under pressure with a narrower cuff.

Evaluation of new technique

Having considered the viability of this device for our paediatric cases, we first used the S-MART™ in November 2005. The decision was taken to evaluate in order to address some of the concerns that we had with pressure cuffs including the potential for abrasive skin burns and poor bloodless fields, although other benefits soon became apparent.

On the day that it was first evaluated, we had three paediatric cases. First, there was a 7 year-old boy who required a wrist tendon transfer, followed by an 11 year-old girl having a diagnostic knee arthroscopy and, finally, a 3 year-old boy for a flexor tenotomy of the foot.

There was, of course, quite a variation in limb size over the three cases but the manufacturers of the S-MART™ have developed a method of ensuring that there is an appropriate device available to cover all but the most extreme limb sizes. Traditionally, the same pressure cuff would be used on all limb sizes but with the S-MART™ you can choose the most appropriate device by measuring the circumference of the limb where the device is to be sited and then reading off supplied tables.

Which size of device you choose depends on the limb circumference and there are 4 sizes to choose from that range from S-MART Small (14-28cm circumference) to the S-MART™ XL (50-90cm circumference). In between there is the S-MART™ 40 (20-40cm circumference) and the S-MART™ 60 (30-60cm circumference). They also come in a range of colours which signify the range of systolic pressures that the S-MART will occlude so it is important to understand the systolic pressure of the patient before choosing the device. The necessary charts were supplied to us by the manufacturer and plenty of advice provided in order to ensure that the correct system was identified before use.

Appropriate device selection

As well as the device selection charts, we were also provided with tables which allowed us to understand the pressure at the limb surface for any given device. This figure is equivalent to the readout provided by the pressure cuff machine.

So, the circumference of the limb at the desired tourniquet site and the patient's systolic pressure are measured so that the right system can be identified. The device arrives sterile and is double wrapped for theatre, the packaging clearly showing the size and pressure capability of each individual system. The S-MART™ is handled using the normal theatre handling techniques to ensure aseptic delivery into the surgical field. Inside the pack there is a plastic "cutting card". This is required at the end of the surgery to aid the removal the S-MART™ and so needs to be retained.

Because the S-MART™ is sterile, the anaesthetic can be applied and the disinfecting preparations carried out before device placement. When preparations are complete and the first incision awaits, the S-MART™ should be applied.

In order to place the S-MART™, we cut off the closed end of the stockinette for the hand and foot procedures. For the arthroscopy case, access was gained through the stockinette at the surgical site. To remove the S-MART™, the plastic cutting card was placed proximal to the device and the device was rolled over the leading edge of the card. The S-MART™ ring was then cut with a scalpel and the device removed, allowing blood to flow back into the limb.

Excellent bloodless field

All three of the cases for which we evaluated the device were remarkably successful. After the S-

MART™ was rolled on to the limb of the first case and the first incision was made it was immediately apparent that the S-MART™ was going to provide us with exactly what we needed. Simply a visual examination of the skin surface was enough to show that exsanguination had been effective and, if that wasn't enough, the absence of any bleeding after the first incision confirmed it. Using the device was easy and placement was last minute, reducing tourniquet time but, most importantly of all, the surgical field was completely bloodless throughout, leaving a clear view which is ultimately important in delicate cases such as these.

Other areas of benefit

There was a lot of curiosity in the product when it arrived in theatre from all theatre personnel. It is an intriguing device at first sight, partly due to the various colours that represent the pressure range. We used two S-MART™ Small devices (pink), aimed specifically at paediatrics, on the tendon transfer and flexor tenotomy. These are applicable with systolic pressures up to 130mmHg. The arthroscopy case utilised the red device. This was an S-MART™ 40 applicable to medium systolic pressure ranges. The anaesthetists were particularly interested to find out how the S-MART™ coped with variations in systolic pressure as, at first glance, the devices seem to be quite similar. They were happy with the solution and the advice provided in choosing the appropriate system. We even had an ODP begin preparations in theatre for the placement of a sterile stockinette for the diagnostic arthroscopy. He was particularly surprised and pleased to hear that this would not be necessary as the S-MART™ applies a stockinette automatically during placement. He was subsequently able to turn his attention to other tasks which further demonstrated how the S-MART™ can also improve current use of theatre resources.

In all, the experience for the staff and the patients has been very positive and after such a resounding success in the initial evaluation phase we chose to continue the use of the product. To date, we have performed 20 operations ranging from flexor tenotomy to osteotomies and tendon transfers on patients with an age range of 14 years (Max 16, Min 2) and in all cases a clear and bloodless field has enabled us to perform the surgery with the accuracy and confidence required to ensure a positive clinical outcome.

Limitation of use

The one disadvantage of this technique is that if you remove the cuff to achieve haemostasis through the operation, you are unable then to re-inflate the cuff should this be desirable with certain procedures. Furthermore use of the cuff over fractured bones or open wounds would be undesirable and its main use therefore lies within the elective paediatric surgical field.

The future of S-MART™

With S-MART™, we now feel that we have found a suitable alternative to the pressure cuffs in paediatric and young adult cases and, as such, will no longer be commissioning the use of the pressure cuff tourniquets in these procedures. The S-MART™ is a very simple device which has provided us with a more effective tourniquet solution with regards to all aspects including ease of use, flexibility, time, resource and, of course, infection control and quality of the bloodless field, which needs to be second to none. Our intention is continue the use of the device and there may be future opportunities to expand the benefits of the device into other areas in the hospital such as day care.

Enquiry No 53

Enquiry No 29

Understanding and Mitigating Tourniquet Risks

(Tourniquet Pain, Skin Injury and Neuropraxia can be Mitigated by Using Sterile Silicone Exsanguination Tourniquet (SET))

March 2018

Address for Correspondence:

Noam Gavriely MD, DSc

4 Etgar St. Tirat Carmel, 3903215 Israel

Noam@hemaclear.com

+972-544-661337

Key words

Pneumatic Tourniquet, Esmarch bandage, exsanguination tourniquet, tourniquet-pain, tourniquet-burn, tourniquet-neuropraxia

Conflicts

The authors are executives and stakeholders in Oneg HaKarmel Ltd., manufacturer and distributor of HemaClear® (www.hemaclear.com).

Abstract

The majority of limb operations are performed with a bloodless surgical field, obtained by removing the blood from the limb (exsanguination) and blocking its re-entry (tourniquet). During the past 100+ years this has been achieved by using an elastic band (Esmarch bandage) and a wide cuff Pneumatic Tourniquet. This practice is associated with frequent and sometimes severe adverse effects. A recent JBJS (Am) study in 164 patients undergoing TKA using a Pneumatic Tourniquet (Zimmer, AST 4000) in Karolinska Institute (Stockholm, Sweden (6)), 20.7% of the patients had skin injuries at the tourniquet site on the thigh, 39.6% reported thigh pain on day 4 postop and 1 patient had tourniquet paralysis. Multiple other studies report similar results.

This review article analyzes the biomechanical processes leading to these adverse effects. In particular, (a) the effects of friction and pinching of skin folds by the inflating Pneumatic Cuff, leading to skin injuries and blisters; (b) the deformations and shear forces applied by a wide cuff on the muscles and specifically on the deep fascia where the pain slow C-fibers are located; and (c) the effect of nerve elongation and telescoping at the Nodes of Ranvier, leading to axonal disruption at the distal and/or proximal edges of the wide Pneumatic Tourniquet, causing nerve damage.

The article also discusses reasons why using the narrow elastic ring exsanguination tourniquet to achieve a bloodless field has not been associated with skin or nerve damage (0 cases in >1,100,000 uses) and significantly less post-op tourniquet pain. The narrow footprint, symmetric circumferential stretching when rolled up the limb, optimized subcutaneous pressure distribution and ability to place it at sites where there is less muscle and fascia, all contribute to its vastly improved safety track record.

When patient safety is of concern, it is apparent that using the sterile elastic exsanguination tourniquet is far safer than using the wide-cuff Pneumatic Tourniquet.

Introduction

The benefits of using a tourniquet during limb surgery are often offset by their adverse effects, namely tourniquet pain, tourniquet "burn" and less frequently tourniquet neuropraxia (2). Nevertheless, the majority of orthopedic surgeons use tourniquets during limb surgery to reduce intra-operative blood loss and in order to improve operative visibility, which lead to more accurate and shorter procedures. Studies and meta-analyses on the benefits and side effects of the use of tourniquets (1) show that their use reduces intra-operative blood loss, but overall hemoglobin levels drop and transfusion rate is not different, while post-operative tourniquet pain and skin damage are not seen when a tourniquet is not used. This essay explores the available data on the mechanisms of wide Pneumatic Tourniquet adverse effects and on the enhanced safety of using a Sterile Silicone Exsanguination Tourniquet – SET (HemaClear®, Oneg HaKarmel Ltd., Tirat Carmel, Israel) in upper and lower extremities surgery.

Tourniquet Pain – (TP)

There are two kinds of tourniquet pain (TP): intra-operative and post-operative. The intra-operative TP is described as an anesthesia challenge characterized by gradually increasing arterial blood pressure and heart rate that are poorly responsive to standard analgesics and anesthesia (2, 3, 4, 5). This kind of TP typically subsides upon release of tourniquet pressure. Speculations concerning the cause of intra-operative TP implicate nerve compression and ischemia that stimulate unmyelinated C-fibers. Their action potentials are perceived as pain. It is believed that slow conduction C-fibers, which are typically less responsive to local anesthetic blockade are the source of the pain. The pain increases over the first 45-60 minutes of tourniquet inflation so that regional blocks that are normally sufficient for surgical anesthesia for the surgical incision itself are not enough to block the tourniquet pain. Additional analgesia or even general anesthesia become necessary and even with those, sympathetic responses of blood pressure and heart rate may become excessive and require premature tourniquet pressure release.

Postoperative TP

Postoperative TP is pain experienced by the patient following the operation at the site where the tourniquet was placed. When Pneumatic Tourniquet is used this pain is in the quad muscles in the leg and on the biceps in the upper arm. The following paragraph was copied from a patients group blog (8) as is (including photograph). It best depicts the symptoms in a most authentic way:

"Tourniquet pain is a consequence of lower limb surgery that is not much talked about. It's a pain that occurs in the upper thigh because of the tourniquet the surgeon uses to both restrict blood loss and make the surgical field bloodless so he can carry out the procedure with greater accuracy and speed.

The tourniquet is usually pumped up to around [three] times the patient's blood pressure - 350mg/Hg for an adult leg. If this is maintained for a couple of hours, the patient may experience a burning pain for some hours or even days after the surgery. It can range from a slightly bruised feeling to an intense burning pain which restricts movement and makes it difficult to do straight leg raises and walking."

Figure 1 Pneumatic Tourniquet placed on a patient's thigh (8)

Several studies that looked into the incidence of postoperative tourniquet pain (6, 7, 9, 10, 11) have been published in recent years. The most focused one is the study by Olivecrona et Al from Karolinska Institute in Sweden, published in JBJS in 2012 (6). This study's primary outcome was the effect of tourniquet inflation pressure on postoperative tourniquet pain. Curved thigh Pneumatic Tourniquet (Zimmer) was applied on 161 patients who were divided into two groups, based on the method of pressure selection (Limb Occlusion Pressure method (LOP) and surgeon-determined pressure). The pain was assessed using a standardized questionnaire (WOMAC) on day 4 postoperatively. On that day, 20.7% of patients had developed blisters or other pressure-related injuries underneath the tourniquet cuff and 39.6% of patients reported they had pain in the quadriceps muscle beneath the tourniquet cuff. There were no differences between the two groups, ($p = 0.400$). All patients also received infiltration of local analgesic into the incision site at the end of the surgery by injecting it into the fascia, muscles, and subcutaneous tissue, regardless of whether they had spinal or general anesthesia. In 147 of the patients, a catheter was also inserted into the knee joint for post-op pain treatment with a local anesthetic. It was used during the day following the surgery and was then withdrawn.

This study clearly shows the discrepancy between the well-controlled incisional pain by the infiltration of long-acting local anesthetics vs. the extent of thigh muscle tourniquet pain. Other studies (7, 10, 11) also found that postoperative thigh pain was prevalent after TKA and often required parenteral narcotics (e.g. morphine).

Factors that Influence Pneumatic Tourniquet Pain and Other Adverse Effects

When compressive mechanical load is applied to a limb to block blood flow, the tissues beneath it are deformed macroscopically and microscopically. First off, the load has to be sufficient to collapse the arteries in order to stop

the circulation. This means that the pressure just outside of the artery must be greater than the highest intravascular pressure, namely the systolic blood pressure. The artery must be collapsed over a length of no more than a few millimeters in order to block it. The actual complete collapsing transmural pressure on the artery is a complex function of the systolic pressure and the arterial wall thickness and flexibility (http://www.academia.edu/13977055/General_Tube_Law_for_Collapsible_Thin_and_Thick-Wall_Tubes (Kozlovsky, P., et al., General tube law for collapsible thin and thick-wall tubes. Journal of Biomechanics (2014)). The applied external pressure must overcome the systolic blood pressure, as well as the mechanical resistance to complete folding of the arterial wall at the two edges of the buckled artery (Figure 2)

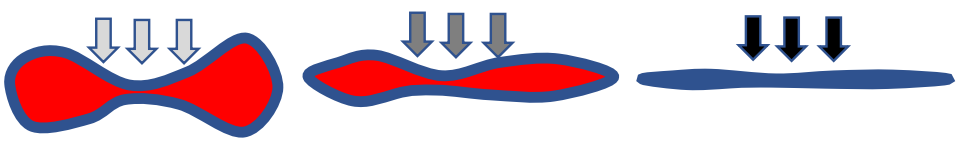

Figure 2 Left, low sub critical pressure causes partial collapse with significant side-lobes; Middle, higher pressure compresses the side-lobes, but closure is still incomplete; Right, the pressure needed to completely collapse the artery and block blood flow is somewhat higher than the systolic pressure. The extra pressure needed to completely fold the artery is small relative to the systolic blood pressure except in patients with arterial calcification and sclerosis.

To achieve the needed pressure just outside of the arterial wall the pressure applied by a tourniquet to the patient's skin should be at least as high. When a wide Pneumatic Cuff is used, such as when measuring blood pressure by the Riva Rocci sphygmomanometer the skin pressure and the internal pressure are identical. This is true also when applying a wide surgical Pneumatic Tourniquet to a limb. However, when the tourniquet is narrow relative to the limb diameter such as when a too narrow cuff is used to measure blood pressure or when the Silicone Exsanguination Tourniquet – SET (HemaClear®, Oneg HaKarmel Ltd., Tirat Carmel, Israel) is used to provide a bloodless surgical field, the tissue pressure outside the arterial wall is significantly less than the skin pressure.

When a wide Pneumatic Tourniquet cuff is applied to a limb, e.g. the thigh over the quadriceps or the upper arm over the biceps/triceps, in addition to the compression of the arteries, a large volume of soft tissue comes under stress and deformed. MRI images taken during tourniquet application (figure, 6 from Dr. Estebe Personal communication) show the deformed tissues and the extent of the deformation. Clearly the skin, subdermal tissues, the muscles and the deep fascia are deformed and displaced. The nerve(s) running along the limb are compressed and deformed as well.

The factors that play a role in this process are as follows:

1. Tourniquet skin pressure
2. The pressure field and distribution of pressure in the tissues
3. Tourniquet width which determine the volume of tissue and skin surface area beneath the tourniquet
4. Limb diameter and thickness of adipose layer

5. Duration of tourniquet application and patient-related factors (e.g. preoperative tissue oxygen storage, arterial stiffness, tissue vascularization etc.)
6. Location of tourniquet placement

The following chapters analyze the contribution of each factor to the risk of developing postoperative tourniquet pain.

Tourniquet Skin Pressure

There are many empiric clinical protocols to determine the skin pressure that will be sufficient to block the blood flow into a limb. The use of 200-250 mm Hg on the upper arm and 300-350 mm Hg for the thigh is common among surgeons and seem to work for the vast majority of patients, but may actually be excessive. Some researchers who felt that these pressure levels are too high and may be the cause of adverse effects sought to find a formula for "dialing in" tourniquet pressures that are tailored to the individual patient. They proposed using the patient's pre-operative systolic blood pressure and add a fixed value to it (e.g. 50 mm Hg for the arm and 100 mm Hg for the thigh). Another method is to determine the patient's pre-operative Limb Occlusion Pressure – LOP, which is the tourniquet pressure where pulsations in the toe/finger cease as determined by a photocell or a pulse oximeter. This value which is circa the systolic blood pressure is then used as basis for adding a fixed value. In both cases the reason for setting the tourniquet pressure higher than the pre-op systolic pressure/LOP is because blood pressure can rise during the operation. Most common reasons for this rise are (i) the shifting of blood from the limb (leg in particular) to the core during the pre-inflation limb exsanguination and (ii) surgical or tourniquet pain that is not countered sufficiently by analgesics. In a recent study (6) Olivecrona et Al suggested using 225 mm Hg as the highest tourniquet pressure in patients undergoing TKA who have a BMI not greater than 35. In a post-hoc analysis of their data they found a significantly lower rate of complications when tourniquet pressure was less than 225 mm Hg.

Pressure Distribution Inside a Limb

The origin of the Pneumatic Tourniquet is from the Riva-Rocci method of blood pressure measurement (Figure 3a) (http://en.wikipedia.org/wiki/Scipione_Riva-Rocci), or sphygmomanometer. The force applied to the soft tissues by a circumferential Pneumatic Cuff or tourniquet pressurizes and deforms the tissue. However, although the soft tissues of limbs (muscle, skin, fat) are elastic and flexible, they are not compressible. As a result, the applied forces cause elements of the tissue to move (displacement). Already in 1977, Alexander et Al calculated the pressure field within a limb model beneath a cuff and determined that in order for the pressure inside the limb at the middle of the width of a cuff to be equal to the cuff pressure throughout from the skin level to the center of the limb the cuff width must be 1.2 times larger than the diameter of the limb at the cuff site (Figure 3b). This is very important in order for blood pressure determination by the Riva-Rocci method to be accurate (red arrow). However, if the tourniquet is narrow (e.g. its width is only 0.5 (50%) of the limb diameter (green arrow), the tissue pressure at the midpoint of the tourniquet may be as low as 0.75 (75%) of the surface pressure (green arrow).

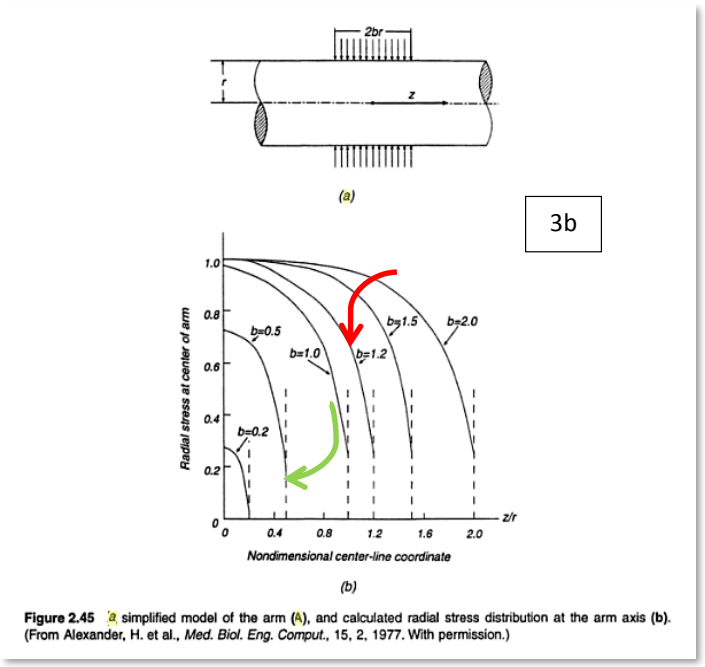

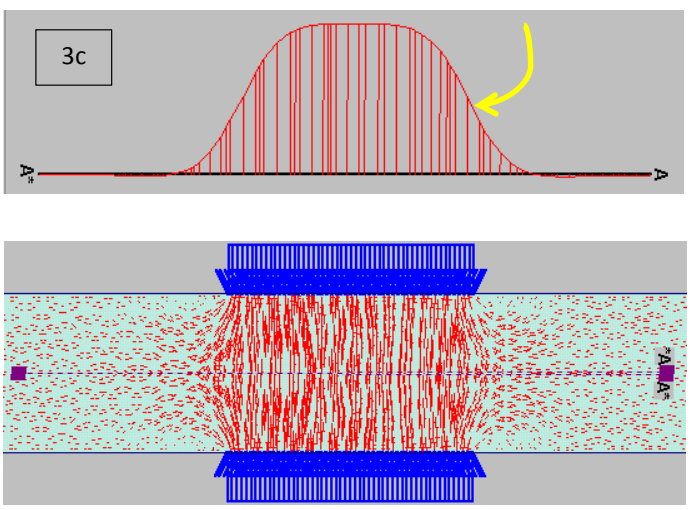

Figure 3a-c

3a. Top left: blood pressure measuring device (sphygmomanometer)

3b. Top right: Calculated radial stresses in a limb at its midline from Alexander et al, Med. Biol. Eng. Comput 1977. See text for explanation.

3c. Left: Distribution of principal stresses (pressure, lower panel) and a plot of the radial stresses at the axis of symmetry (upper panel) when a wide tourniquet (width = 1.5 X limb diameter) is applied [from Levenberg E. OHK Archives 2002].

Note the rather steep gradient of pressure drop along the axis of the limb at the edges of the tourniquet (yellow arrow).

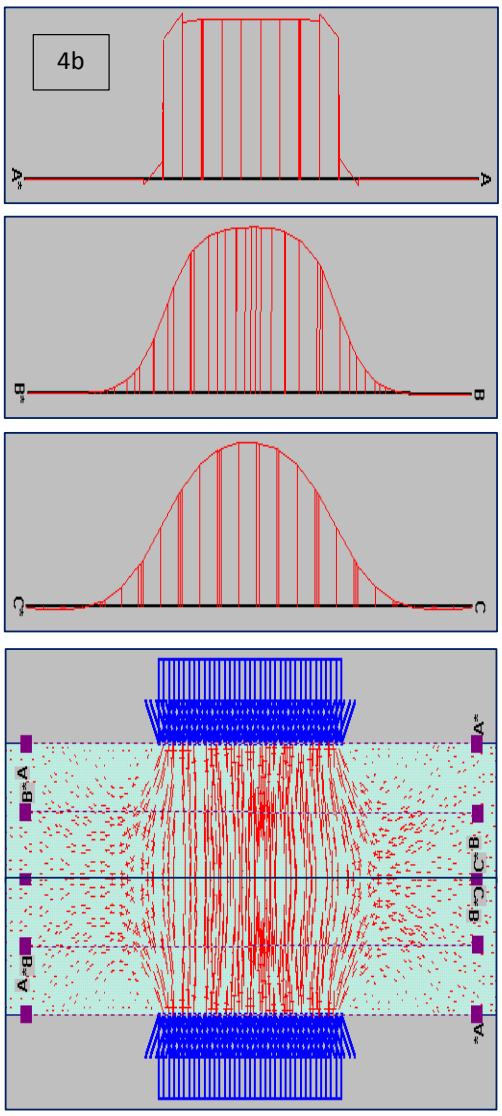

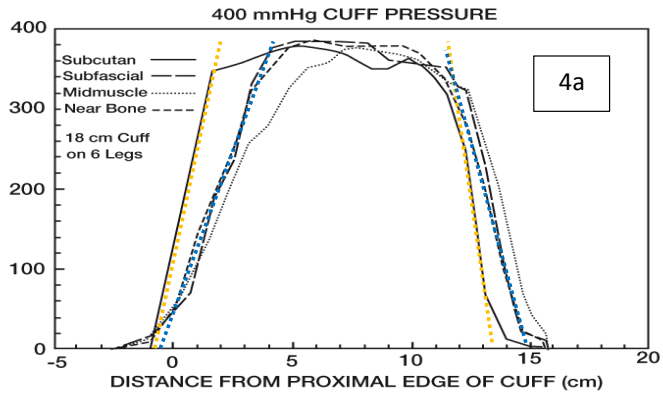

Figure 4a-b

4a. Top: Data from Crenshaw AG, Hargens AR, Gershuni DH, Rydevik B. Acta Orthop Scand 1988; 59(4): 447-451. **showing the pressures measured inside a cadaver limb beneath a cuff of a Pneumatic Tourniquet. The pressure profiles at four levels beneath the skin are shown. While the peak pressures in all the profiles are the same, it is possible to see that the subcutaneous profile is wider, nearly as wide as the cuff width, and the gradients at its two ends are very steep (orange dashed lines). The profiles deeper into the limb and near the bone are narrower and the gradients are less steep (blue dashed lines).**

4b. Left: Computational finite elements analysis of the same situation showing the limb model with the tourniquet (here the tourniquet width is the same as the limb diameter). Panel A is right under the cuff, panel B is half way to the midline and panel C is at the midline. Note that here also the peak pressure is nearly the same as the tourniquet pressure and that deeper into the limb the pressure gradients at the two ends become less sharp.

The similarity between the computational model results and the experimental data indicates a positive validation of the model.

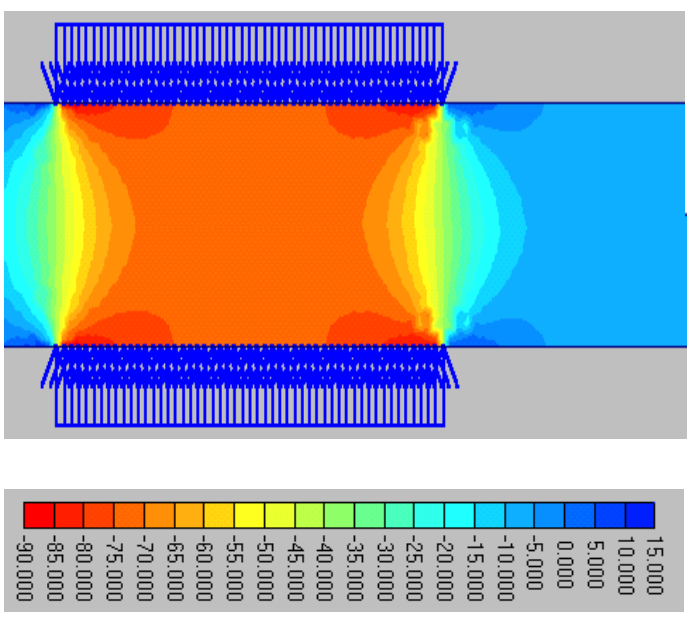

Figure 5

The pressure field inside the limb can also be shown as colored isobars (left). Isobars are areas where the pressure is about the same and are shown in percent of the skin pressure according to the color scale below. In this computational model of the pressures, it is possible to see that with a wide tourniquet (in this case the tourniquet width is X1.5 the limb diameter) the tissue pressure is uniform across the limb cross-section almost under the entire width of the tourniquet and is approximately equal to the tourniquet skin pressure. The gradient at the two ends of the tourniquets is steep, full scale over less than 0.5 limb diameter.

Soft Tissue Deformation Beneath a Cuff.

When a Pressure Cuff (tourniquet or sphygmomanometer) is pressurized around a limb, the soft tissues (skin, fat, muscle etc.) change their shape (deform). [Calling this deformation "compression" is incorrect since tissues, like solids and liquids are essentially incompressible materials. This is different from gases which can change their volume when pressurized and are therefore called "compressible"]. The MRI image on the right (Figure 6a) (courtesy of Prof. Estebe, Rennes, France, who had taken an MR image of his own thigh while a Pneumatic Tourniquet was inflated for 20 minutes) shows the deformation of the tissues. The cuff base is shown as two rectangles and the indentation of the skin (yellow arrows) is where the inflated bladder pushed and deformed the thigh. It is also possible to see that the muscle (gray) and the fascia (red arrow) are displaced, deformed and stretched.

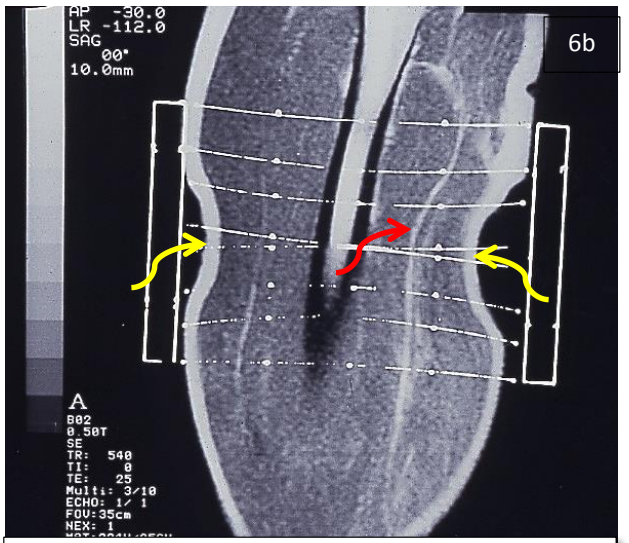

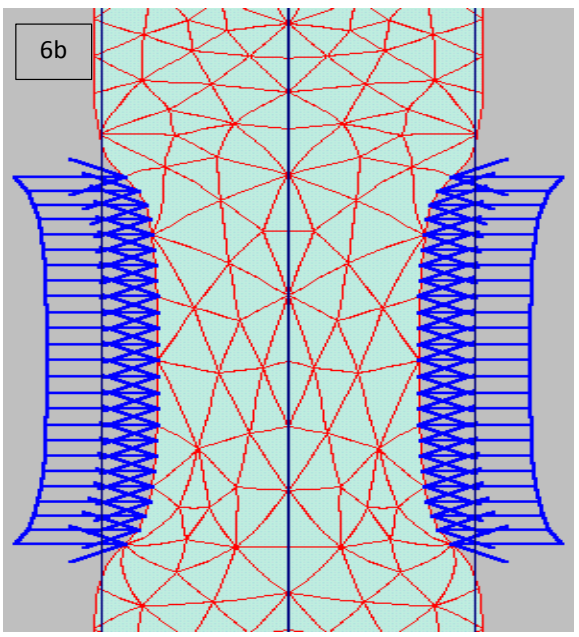

Figure 6a-b

6a. Top: MRI of the thigh under a pressurized Pneumatic Tourniquet (Estebe, personal communication, Rennes, France).

6b. Left: Computational finite elements analysis (red strings) showing the deformation (strain) of a limb under circumferential pressure by a Pneumatic Cuff. From Levenberg E. OHK Archives 2002.

Note the similarities between the model results and the MR image of the limb above.

It is important to understand that the changes observed in the shape of the tissues are all related to motion or dispacement of tissue elements squeezed from the pressurized area beneath the cuff distally and proximally towards the un-pressurized areas. The only actual volume reduction is due to the closing shut of the blood vessels.

Consequences of Soft Tissue Deformation by a Tourniquet

Clearly, when circumferential force is applied to a limb, the resulting pressure field causes deformation and displacement of the soft tissues. The extent of deformation (or "strain") is not negligible and is different in various components of the tissue, depending on their elastic properties (also called the Young's Modulus). Fat is the softest element and muscle properties are different if deformed along the fibers or perpendicular to them. Fascia can be bent, but not shifted. A special case is the nerve, which, when compressed is elongated (see below). The difference in elasticity can cause adjacent tissues to move differently resulting in sheer forces between them, stretching beyond the elastic range and possible tears.

The radial forces that deform the limb radially cause longitudinal motion of tissues along the limb axis. This was noted already in the early 1970s by Ochoa et al who sought a mechanistic understanding of the cause of tourniquet-induced nerve damage ("tourniquet neurpraxia"). They applied pressurized Pneumatic Tourniquets to primates' limbs for several hours and after sacrificing the animals dissected the nerves for electron microscopy.

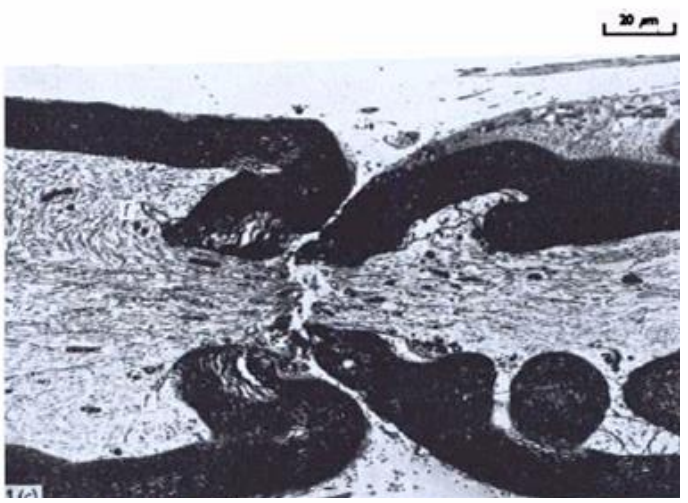



Fig. 6. Diagram to show the direction of displacement of the nodes of Ranvier in relation to the cuff.

They found that the nerves were damaged in a characteristic fashion – they telescoped into themselves at their weakest point, namely the Nodes of Ranvier (Figure 7). At these nodes the Schwan Cells sheet that envelopes the nerve is interrupted for a few microns so that only the axons are continued. The electron micrograph on the left shows an example with a disruption of the axons. To their surprise, the damaged nerves were only seen just proximal and just distal to the Pneumatic Tourniquet cuff as depicted on the two lower panels on the left.

The researchers concluded that the lateral compression of the nerve, which caused it to deform and elongate is the primary cause of the damage, rather than a direct effect of the pressure under the cuff.

The computational analysis by Levenberg depicted below (Figure 8) clearly shows the direction (arrows orientation) and the extent (arrows size) of tissue deformation caused by tourniquet pressure. Areas of excessive axial deformation just before and just after the edges of the tourniquet are marked by yellow arrows.

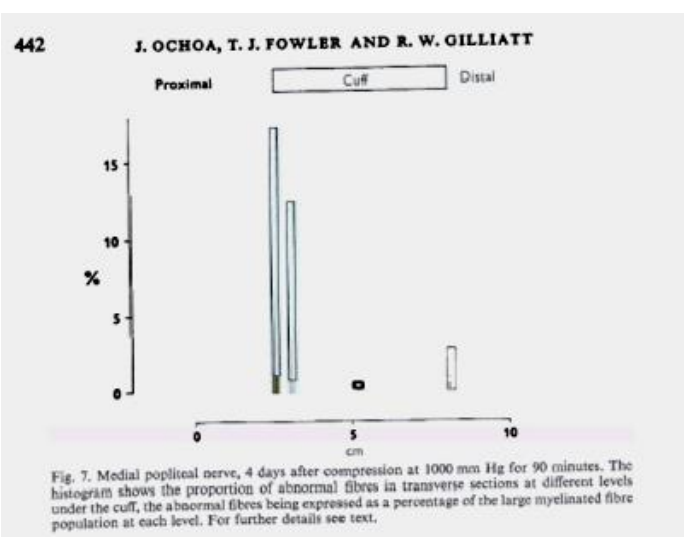

Fig. 7. Medial popliteal nerve, 4 days after compression at 1000 mm Hg for 90 minutes. The histogram shows the proportion of abnormal fibres in transverse sections at different levels under the cuff, the abnormal fibres being expressed as a percentage of the large myelinated fibre population at each level. For further details see text.

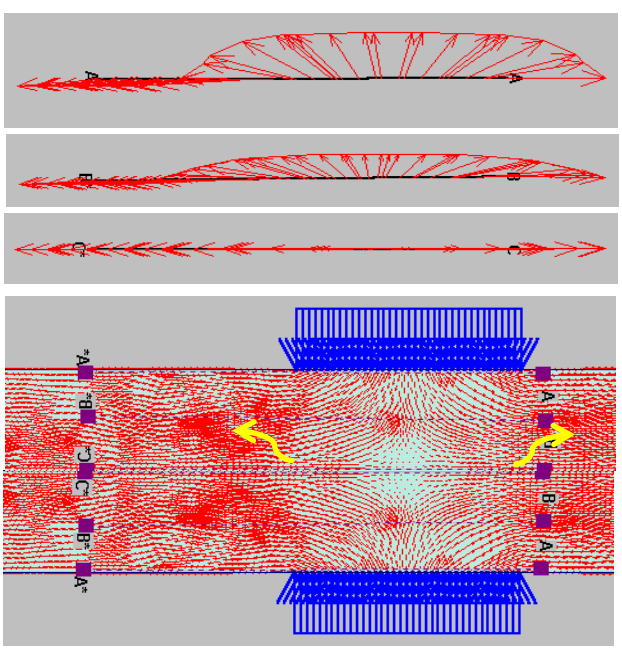

Additional Effects of Tissue Deformation

Two additional adverse effects of the use of wide Pneumatic Tourniquets are also related to tissue deformation, rather than to direct pressure effects or to ischemia. These are (A) skin injury, primarily in the form of blisters; and (B) tourniquet pain. In addition, tissue element motion is also responsible for the desired effect of using a tourniquet, namely the collapsing of the blood vessels beneath the cuff. Below are pictures that illustrate these effects and side effects as MRI (courtesy of Prof Estebe), photo of the skin of a patient who developed tourniquet-related blisters and a computational image showing the closure of the blood vessels by the applied tourniquet pressure.

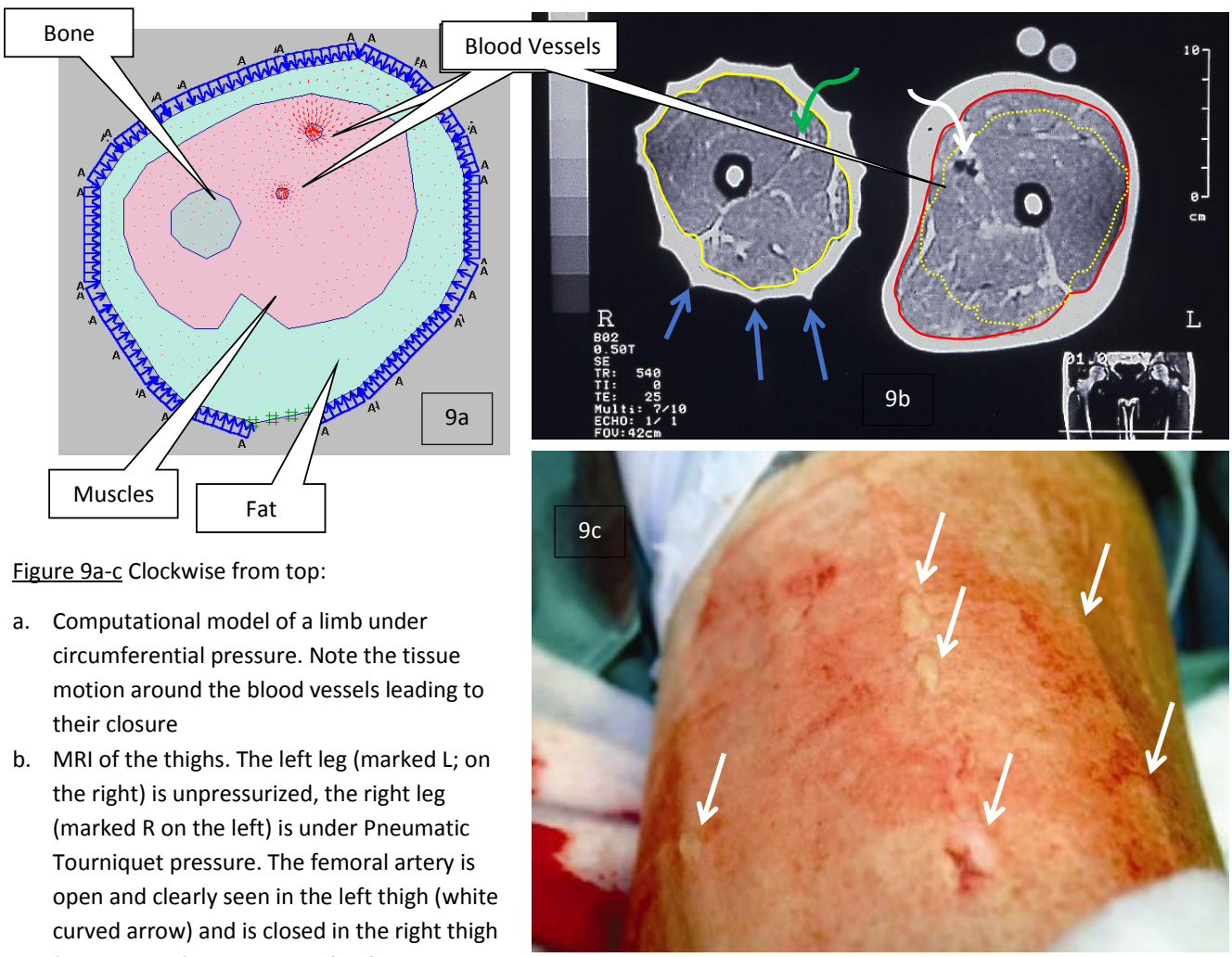

Figure 9a-c Clockwise from top:

a. Computational model of a limb under circumferential pressure. Note the tissue motion around the blood vessels leading to their closure
b. MRI of the thighs. The left leg (marked L; on the right) is unpressurized, the right leg (marked R on the left) is under Pneumatic Tourniquet pressure. The femoral artery is open and clearly seen in the left thigh (white curved arrow) and is closed in the right thigh (green arrow). The extent of deformation can be appreciated from the difference between the red and the dotted yellow perimeters. Note the creases of the skin where the inflated tourniquet pinched the excess skin (blue arrows).
c. These creases correspond to the longitudinal elevations and linear blisters seen in the photo of the post tourniquet skin damage (white arrows). These so called "tourniquet burn" have been attributed to chemicals used in disinfecting the skin. Obviously the main cause is mechanical and associated with the pinching of the skin by the inner surface of the Pneumatic Tourniquet.

Biomechanics of the Elastic Exsanguination Tourniquet

The Elastic Exsanguination tourniquet (HemaClear®, Oneg HaKarmel Ltd., Tirat Carmel, Israel is an elastic ring (torus) which, when stretched, applies circumferential tension around the limb that results in radial force and displacement of the tissue. The relationships between the circumferential force, the radial force and the tissue pressure are explained in Section 2.3.

Ring-induced pressure in the tissue

The Elastic Exsanguination Tourniquet exerts its maximal force on the skin surface where the force is perpendicular to the limb. Further into the limb the force (a vector) principal direction shifts a bit axially and as such the pressure becomes smaller. This results in two pressure gradients, one in the radial direction where the pressure becomes smaller deeper into the limb and the other is in the axial direction. In fact, in a thin limb (e.g. an arm) if the surface pressure is 250 mm Hg, the pressure near the artery may be less than 200 mm Hg. This radial gradient is even greater when the limb is wider (e.g. thigh) and the artery is further away from the skin surface.

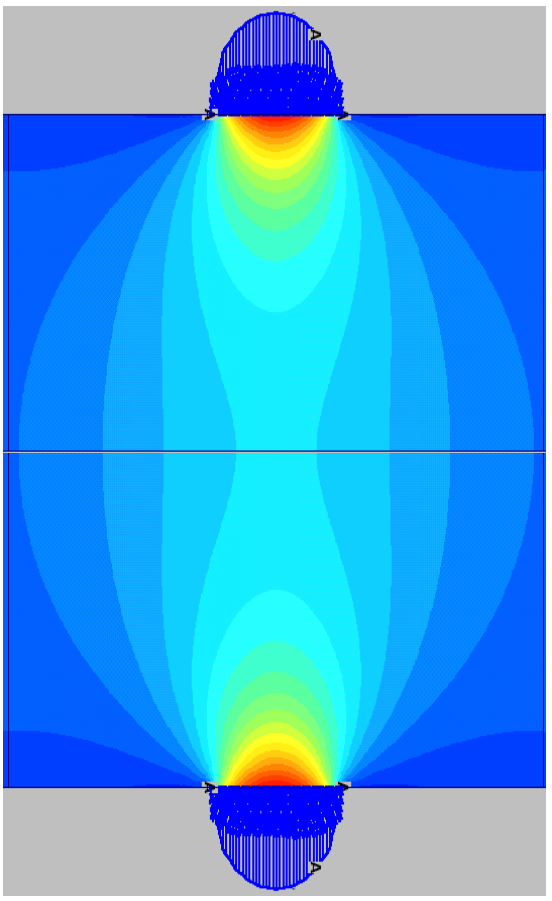

Figure 10

The figure on the right shows the pressure profiles at 4 levels: (A) immediately under the skin, (B) two thirds of the limb radius, (C) third of the limb radius, and (D) at the midline. Note that level B, which is about 68% of the maximum, represents a typical depth of the artery.

Note that the pressure dissipates beyond the width of the Elastic Exsanguination Tourniquet.

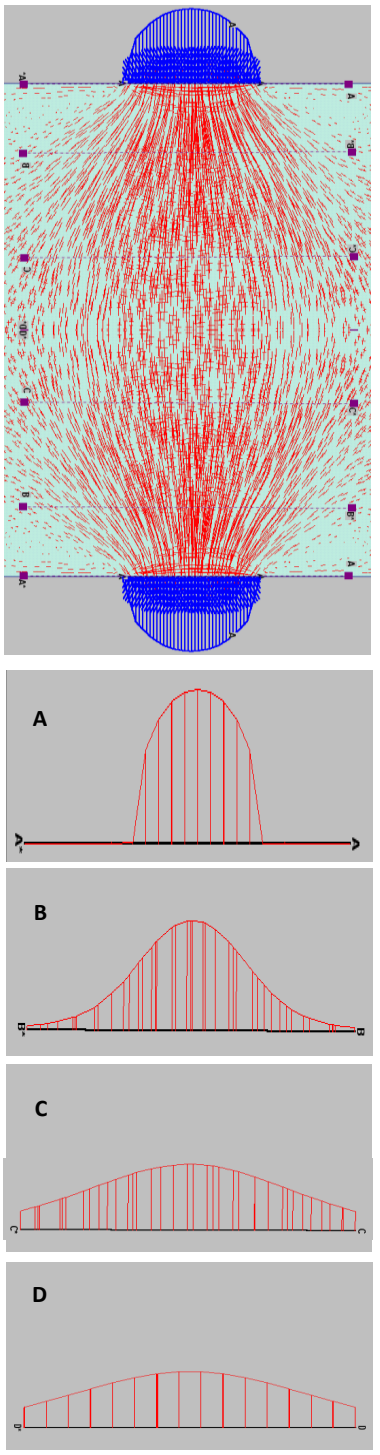

Soft Tissue Deformation by the Elastic Exsanguination Tourniquet

Applying equivalent radial force (stress) on the soft tissue of a limb by an Elastic Tourniquet causes approximately the same level of deformation or strain. This is so because the ratio of Stress/Strain is equal to the Young's modulus, which is a constant depending only on the properties of the tissue and not on the

mechanism by which the tissue is acted on. The images shown below for the Elastic Exsanguination Tourniquet should be compared to those for the Pneumatic Tourniquet shown in Sections 3.2 - 3.4.

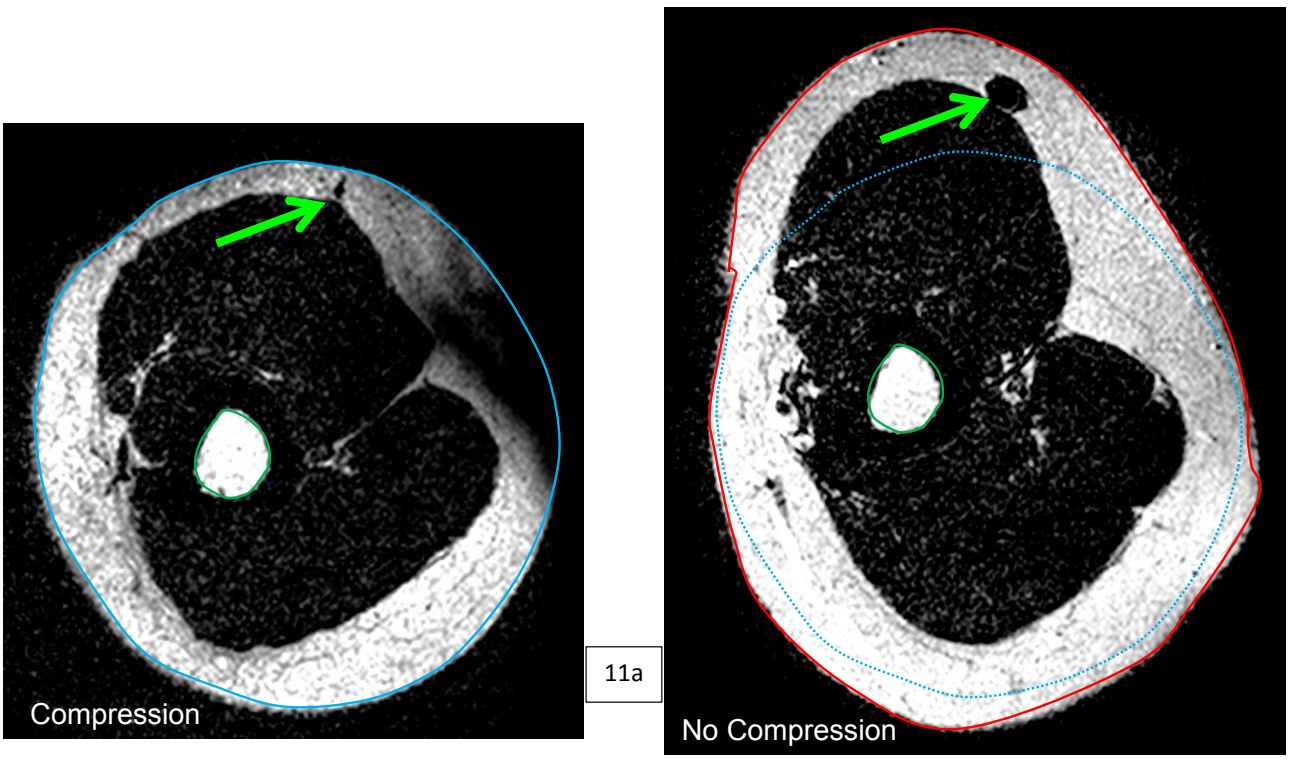

11a

11b

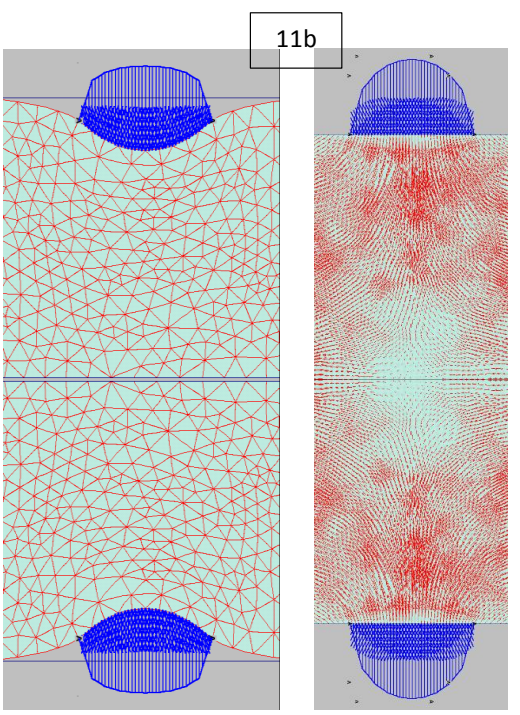

Figure 11 a-b

11a Top: MRI of an arm without (right) and with (left) an Elastic Exsanguination Tourniquet in place (courtesy of Dr. Kovar and Prof. Herzenberg, personal communication). The intra-medullary canal (white spot, perimeter marked in green) was used to verify dimensions. The elastic ring closed the blood vessels (green arrows) and deformed the muscles and fat. The extent of deformation is comparable to that by a Pneumatic Tourniquet, but into a smoothly rounded shape without the pinching side-lobes seen with the Pneumatic Tourniquet.

11b Right: Computational model of the tissue deformation beneath an Elastic ring. The extent of surface and elements deformation can be appreciated from the left-hand panel, while the extent actual motion can be seen in the direction and size of the small arrows shown in the right panel.

Tourniquet Width and the Volume and Surface Area of Tissue Under Compression Force Beneath the Tourniquet and the External Work Applied to the Tissue

We shall now calculate the volume and skin surface area beneath a tourniquet. If we call the cuff width "H" and the limb radius "R" than the volume of tissue beneath the tourniquet "V" can be calculated as

$$V = \Pi * R^2 * H$$

and the skin surface area beneath the tourniquet "A" is given by

$$A = 2\Pi * R * H$$

To calculate the Compression Force "F" we need to recall that the Tourniquet Skin Pressure "P" is given by the applied force divided by the surface area beneath the tourniquet:

$$P = F / A = F / (2\Pi * R * H)$$

This equation can be re-written as a calculation of Force for a given pressure and limb surface area:

$$F = P * A = P * (2\Pi * R * H)$$

When a tourniquet is placed on a limb, it compresses it and causes a change in volume ΔV. External work or applied energy "W" is defined as the product of the pressure applied and the displaced volume ΔV that can be estimated from the MRI images as $\Delta V = \Pi * R^2 * H - \Pi * (R- \Delta R)^2 * H \sim= 2\Pi * R * \Delta R * H$ so that:

$$W = P * \Delta V \sim= P * 2\Pi * R * \Delta R * H$$

Pneumatic Tourniquets cuffs widths vary between 75 mm ("narrow") to 120 mm ("dual bladder") and are typically 100 mm. The SET width is typically 15 mm. For this analysis we shall assume a normal adult upper thigh with a radius R = 100 mm (circumference of 62.8 cm). Table 1 shows the calculated V, A, F and W for a Pneumatic Tourniquet cuff and SET. Both with skin pressure of 250 mm Hg [= 0.33 atmosphere = 0.33 kg/ cm^2).

	Pneumatic Cuff	SET
Volume under constriction [ml]	$V = 3.14 * 10^2 * 10 =$ 3140 ml	$V = 3.14 * 10^2 * 1.5 =$ 471 ml
Skin area beneath tourniquet [cm^2]	$A = 6.28 * 10 * 10 =$ 628 cm^2	$A = 6.28 * 10 * 1.5 = 94$ cm^2
Force applied to the volume of tissue	F = 0.33 * 628 = 209 kg	F = 0.33 * 94 = 31 kg
External Work	W = 0.33 * 3.14 * 5 *1 * 10 = 50 Atm-cm^3	W = 0.33 * 3.14 * 5 * 1 * 1.5 = 7.5 Atm-cm^3 if we assume internal pressure is uniform. Since the internal pressure is lower than the skin-pressure, the external work is even smaller.

It is clear that the constricting force of over 200 kg applied by a Pneumatic Tourniquet on the volume of tissue beneath is excessive. This force has two direct effects: (A) it deforms the tissues beneath the tourniquet and given the fact that the soft tissues of the limbs are essentially non-compressible, the force is primarily causing the tissue to move and when possible to migrate away from the volume under force; and (B) the force is applied as nearly a step change at the two edges of the cuff, thereby creating a steep gradient, also called shear stress at the two edges of the cuff.

Another way to characterize the effect of applying a tourniquet to a limb is by determining the External Work into the tissue. External Work is force times displacement when applied in a unidirectional fashion (e.g. lifting a weight), or pressure time change in volume in three-dimensional compression as with the tourniquet. External Work is equivalent to energy input into the pressurized element and at ~50 Atm-cm is excessive.

The Effect of the Duration of Blood Flow Occlusion by a Tourniquet

When blood flow to a limb is stopped, the supply of oxygen and metabolite substrate (e.g. glucose) is stopped. This results in a quick drop in PO2 and the onset of consumption of alternative sources of ATP. Initially from the muscle stores of creatine phosphate, followed by onset of anaerobic metabolism that results in accumulation of its metabolites such as lactic acid. The graphs below show the kinetics of PO2 levels (top panels), quantity of anaerobic metabolites (e.g. lactate) in the intracellular compartment and the corresponding concentration. The occlusion of blood flow is indicated by the onset of PO2 drop.

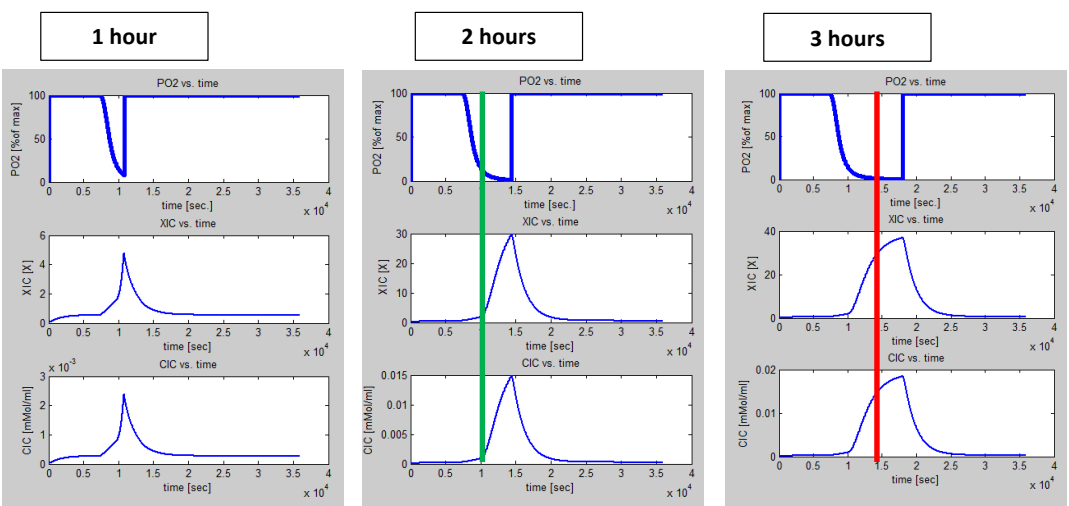

Figure 12 The effect of Tourniquet Time on PO2, quantity of metabolite (e.g. lactate) in the intra-cellular compartment (XIC) and its concentration (CIC). Left panel – 1-hour, Middle panel 2-hours, Right panel 3-hours. Note that the Y-axis is not the same in all the panels; time axis is in seconds X 10^4. (Gavriely, N. unpublished data)

In this example it is possible to see that when intracellular PO2 reaches a critically low level, the anaerobic metabolites start to accumulate (green vertical line). However, when the substrates for the anaerobic metabolism is depleted, the slope of the metabolites accumulation changes (red line). This is when ATP availability to the tissues becomes critically low and ischemic injury is imminent. In this model, the onset is at about 7000 sec after tourniquet onset =~ 2 hours. The situation is reversed when the blood flow occlusion is removed where PO2 returns to normal and the metabolites are washed out.

This model is helpful in pointing out the importance of pre-occlusion conditions and in particular the tissues oxygen levels and the stores of ATP and metabolic substrates. These are typically low in patients with co-morbidities such as peripheral vascular disease, cardio-pulmonary ailments and diabetes.

Location of Tourniquet Placement

An important factor in preventing tourniquet adverse effects is the locations where the tourniquet is placed. The options with the Pneumatic Tourniquet are limited to the thigh (mid or upper), or upper arm. Placing a Pneumatic Tourniquet on the wrist or on the ankle splints the ligaments and result in marked limitation of the motion of the fingers and toes, thereby interfering with the surgical procedures of hands and toes. These sites are associated with marked deformation of the underlying muscles and fascia and cause significant post-operative pain.

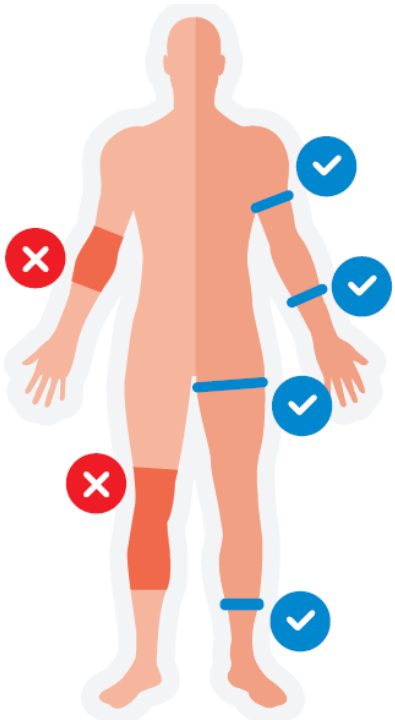

The SET, on the other hand, can be placed away from major muscle masses as shown in the diagram on the right (Figure 12). On the upper limb it is placed over the insertion of the deltoid, just above the biceps or on the wrist, 10 cm above the wrist skin fold. The wrist placement of the SET is possible because it does not splint the ligaments and allows full free passive and active motion of the fingers. The same is true when the SET is placed 10 cm above the lateral malleolus on the ankle. If on the upper leg, the SET should be placed at the groin level (i.e. where the leg connects to the pelvis). In all these sites the underlying muscles and fascia are the least and the result is much less post-op pain.

Summary and Conclusions

This manuscript reviews the biomechanics of tourniquets use and the known adverse effects of the wide Pneumatic Tourniquets including tourniquet neuropraxia, tourniquet pain and tourniquet-related skin injuries and blisters. It is apparent that all are attributed to the width of the tourniquet. An outcome of the analysis is the clarification that the wide tourniquet applies very large force and external work on a large volume the limb's tissues, which are unnecessary in order to occlude the blood flow. The superiority of the narrow elastic SET are brought to light with the markedly better safety track record – no neuropraxia, no skin damage and much less pain in more than 1.1 million cases, which are due to its narrow footprint, the uniform skin pressure, the optimized internal pressure and the ability to place it in optimal positions. The metabolic consequences of tourniquet use are briefly presented. Those are common to all tourniquets (wide, narrow or trauma types) and show the biochemical foundation for the empiric time limit of 120 minutes of continuous tourniquet use.

References

1. References on surgery with and without tourniquet
2. Klenerman L. the Tourniquet Manual.
3. https://www.openanesthesia.org/upper_extremity_tourniquet_pain_prevention/ intraoperative tourniquet pain
4. Cherng CH, Wong CS, Chang FL, Ho SJ, Lee CH. Epidural morphine delays the onset of tourniquet pain during epidural lidocaine anesthesia. Anesth Analg. 2002;94:1614–6.
5. Viscomi CM, Friend A, Parker C, Murphy T, Yarnell M. Ketamine as an adjuvant in lidocaine intravenous regional anesthesia: a randomised, double-blind, systemic control trial. Reg Anaesth Pain Med. 2009;34:30–3.
6. Charlotta Olivecrona, RN, Sari Ponzer, MD, PhD, Per Hamberg, MD, PhD, and Richard Blomfeldt, MD, PhD **Lower Tourniquet Cuff Pressure Reduces Postoperative Wound Complications After Total Knee Arthroplasty - A Randomized Controlled Study of 164 Patients** Department of Orthopaedics, S¨odersjukhuset Karolinska Institutet, Stockholm, Sweden J Bone Joint Surg Am. 2012;94:2216-21
7. David Liu, FRACS,[1] David Graham, MBBS,[2] Kim Gillies, M Hlth.Sc,[3] and R. Mark Gillies, PhD[4] . Effects of Tourniquet Use on Quadriceps Function and Pain in Total Knee Arthroplasty. Knee Surg Relat Res. 2014 Dec; 26(4): 207–213.
8. Tourniquet pain in upper thigh https://bonesmart.org/forum/threads/tourniquet-pain-in-upper-thigh.5622/ Discussion in 'Concerns after knee surgery' started by Josephine, Sep 13, 2017.
9. Worland RL, Arredondo J, Angles F, Lopez-Jimenez F, Jessup DE. Thigh pain following tourniquet application in simultaneous bilateral total knee replacement arthroplasty. J Arthroplasty. 1997 Dec;12(8):848-52.
10. Estebe JP, LeNaoures A, Chemaly L, Ecoffey C. Tourniquet pain in a volunteer study: effect of changes in cuff width and pressure. Anaesthesia. 2000 Jan;55(1):21-6.
11. Kerr DR, Kohan L. Local infiltration analgesia: a technique for the control of acute postoperative pain following knee and hip surgery: a case study of 325 patients. Acta Orthop. 2008 Apr;79(2):174-83.
12. Ochoa J, Fowler TJ, and Gilliatt RW. Anatomical changes in peripheral nerves compressed by a pneumatic tourniquet. J Anat (1972), 113, 3, 433-455.

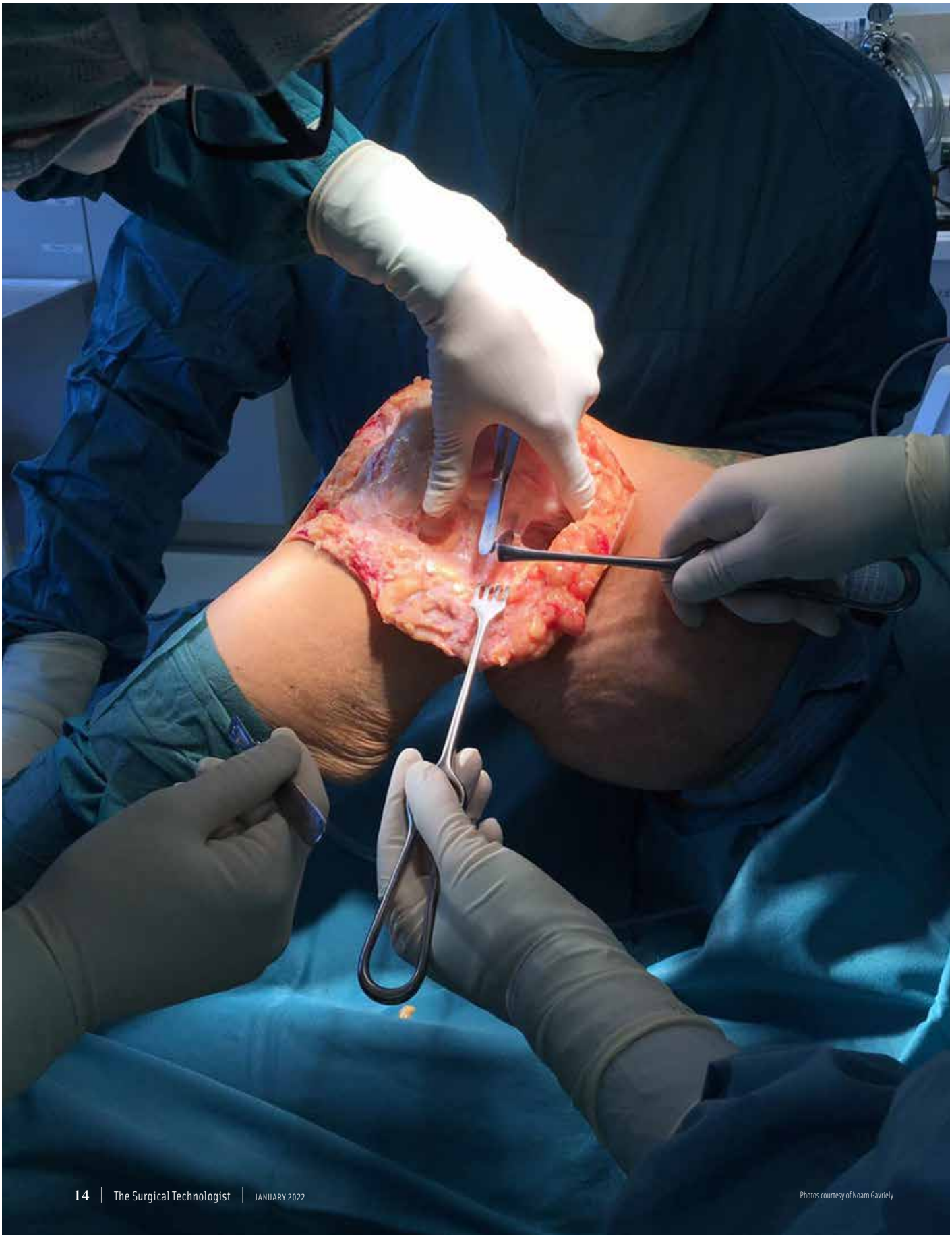

Photos courtesy of Noam Gavriely

Optimizing the Bloodless Surgical Field in Limb Surgery

Noam Gavriely, MD, DSc

Limb surgery under a bloodless field is performed approximately 3,000,000 times a year (10,000 cases a day) in the US. The historical method of using an Esmarch bandage and a pneumatic tourniquet, first introduced in 1873 and 1904, respectively, dominates the practice, despite a high rate of adverse events and complications.

The incidence of post-operative skin injuries and blisters is reported[8] in 20.7% of TKA cases using a state-of-the-art pneumatic tourniquet. The same study reports 39.7% of patients having significant thigh pain on day 4 post-operatively and one case of nerve injury among the 160 patients. A concerning practice is the re-use of non-sterile cuffs in many of the US hospitals and ASCs that perform limb operations which likely contribute to the incidence of SSIs. An alternative safe and effective Surgical Exsanguination Tourniquet (SET) is now used in over 500 hospitals in the US with superior exsanguination, simpler OR logistics and most importantly, an impeccable patient safety track record. Multiple investigator-initiated studies published in peer-reviewed journals report no skin or nerve damage, significantly less pain, much reduced intra-operative blood loss, less SSI, less DVT and longer auto-graft harvesting for ACL reconstruction.

LEARNING OBJECTIVES

- Read about the history of bloodless limb surgery
- Explain the different tourniquet styles mentioned in this article
- Review how the pathophysiology of the skin, muscles and nerve compression are impacted by tourniquets
- Describe the importance of completely exsanguinating the limb before a tourniquet is used
- Compare and contrast patient safety with economic advantages between the two tourniquet styles

This article is intended to provide the surgical technologist the knowledge on the correct application of the SET, model selection, documentation of pressure and the contraindications as well as with the Esmarch bandage and comparison of both. The article also reviews the biomechanics and physiology of applying a tourniquet (SET or pneumatic) to a limb. The decision on which tourniquet to use is the surgeon's, but the surgical technologist should be prepared to safely assist in applying the SET if this option is requested.

HISTORY

Performing bloodless limb surgery was first described in 1873 by Johannes Friedrich August von Esmarch (1823-1908)[1] using a long bandage, now called the Esmarch bandage. Still used to date, when wrapped tightly around the limb from distal to proximal, it expels the blood from the limb into the central circulation. This procedure is called exsanguination. In its original application, the Esmarch bandage was wrapped several additional times at the proximal end of the limb to also block the return of arterial blood into the limb to act as a tourniquet. While this method is still occasionally used in ORs, it is now recognized to apply inconsistent, often excessive, pressure on the soft tissues. In 1904, Harvey Cushing, the well-known neurosurgeon who was concerned about tissue damage from the tight Esmarch bandage, first described the pneumatic tourniquet using compressed gas source.[2] Despite many shortcomings and complications,[3, 28, 29] the Esmarch bandage together with the pneumatic tourniquet are the most widely used method for achieving bloodless surgical field in the US and globally. Recently, a review of the use of pneumatic tourniquets and military tourniquets,[19] advanced the hypothesis that individualizing the cuff pressure can reduce the incidence of tourniquet-induced adverse events including nerve damage. This article aims to broaden the surgical technologist's knowledge and understanding on the newer methods of safely and effectively providing a bloodless limb surgical field for orthopedic, plastic and vascular surgeries, as well as the biomechanics and physiology of tourniquet-tissue interactions.

In recent years, more hospitals and surgical centers in the US are using a novel device that expels the blood from the limb, blocks the blood re-entry and provides a sterile surgical field in one action. The generic name of this free-standing elastic device is the Surgical Exsanguination Tourniquet (SET).[4]

THE SET AND ITS APPLICATION ON THE OPERATED LIMB

The SET is supplied sterile-packed in dual peel-back pouches. The device consists of a silicone circular ring (torus) wrapped around with an elastic tubular stockinet made from woven cotton and spandex and with straps that end with a plastic handle (Figure 1). The SET is placed on the tips of the fingers or toes while an assistant stabilizes the hand/foot. When the handles are pulled proximally along the axis of the limb, the torus rolls upon itself along the limb while the sterile stockinet unrolls on the limb.

Figure 1. *The application of the SET.*

Once the SET has been rolled up the limb to reach its final position, the straps either can be cut away or wrapped around the limb. The correct sequence of preparation for applying the SET is to first disinfect the skin to about 10 cm (4") above the anticipated final position of the ring and drape the proximal portion of the limb so that the edge of the drape is about 4-5 cm below the anticipated final ring position. After a timeout is performed and the patient is properly draped for the procedure, the SET is applied, typically by the surgeon with the help of one or two assistants.

MODEL SELECTION

There are four basic SET sizes: small, medium, large and extra large. In addition, there are two special models: Model F for the forearm and Model A for the ankle. The medium and the large SET models are available at 3 levels of tightness; the least tight models are suitable for patients with low blood pressure, ie, <130 mm Hg systolic (typically children) and the tightest models are suitable for patients whose BP may rise up to 190 mm Hg. The medium tightness is for patients whose highest anticipated systolic BP during the operation is not more than 160 mm Hg.

With each SET unit there is a small envelope with a color-coded measuring tape. Measuring the limb circumference at the site the surgeon decides to place it will immediately show which size to use. SET sizes range from 14 cm to 85 cm. The best practice is to base model selection on the ruler and sizing. If sizes overlap, it is recommended to

use the larger model. SET also is very suitable for placement on the forearm, typically 10 cm above the wrist line and on the ankle, 10-15 cm above the malleolus. This is because it does not trap the ligaments leading to the fingers/toes. If a pneumatic tourniquet is placed on the forearm or on the ankle, the ligaments cannot move and the fingers/toes are frozen. The distal placement of SET has great advantage since distal placement means less tissue is under ischemic conditions for the duration of the case.

The SET is removed by cutting the ring with a scalpel. To do so, the pointed plastic card included with each product is inserted under the ring from its distal side. The rest of the stockinet is best cut with a bandage scissors.

CASES IN WHICH SET CAN BE USED AND ITS CONTRAINDICATIONS

SET can be used in all patients for whom an Esmarch bandage and a pneumatic tourniquet can be used. To date, more than 1.5 million cases were operated on with SET globally, of which about a third were in the US. The breakdown of cases in the US is approximately 48% for leg trauma, TKA and knee arthroscopy, 37% in upper extremity, 7% in pediatric orthopedics, 5% in foot and ankle surgery and 3% in miscellaneous cases such as vascular access for dialysis shunts, plastic surgery and in ER for suturing of hand lacerations. More recently, hand surgeons have been using SET in procedure rooms and clinics for office-based minor procedures such as carpal tunnel release and trigger finger. These clinics are usually not equipped with pneumatic tourniquet pumps, so SET may be the only viable alternative for a dry field.

SET has particular benefits in cases of upper arm (elbow and humerus) surgery where the space is limited. Same is true for thigh cases (eg, ORIF of femoral fractures). SET is also preferred for TKA on obese patients (eg, BMI greater than 32) in cases of TKA revision[36] and in pediatric orthopedic cases. These categories are known to be problematic due to the taper of the thigh that often causes migration of the pneumatic tourniquet distally when it is inflated. Other cases where SET is preferred include patients with low pre-op hemoglobin, patients with bleeding disorders (eg, hemophilia) and patients with weakened immunity (eg, patients on chemotherapy, hemodialysis, steroids and patients with diabetes mellitus).

When SET is used in knee arthroscopy for ACL reconstruction, the length of hamstring autograft is significantly larger, particularly in short patients with conical thigh, where the use of allografts becomes necessary. Allografts are not needed when SET is used.[6]

Note 1: SET and patient's blood pressure. Once a particular model of SET is placed on the patient, the pressure remains constant for the entire duration of the case. There is no "upping" or "downing" of the pressure as is often done with the pneumatic tourniquet. As such, it is imperative to maintain the patient's systolic blood pressure below the designated SET maximal systolic pressure. In general, it is the anesthesia personnel who are responsible for monitoring and maintaining the blood pressure. It is, however, useful for the technical team to know the factors that cause blood pressure to rise during surgery. Pain is the most important cause of BP rise. Premature stopping of the analgesics at the (presumed) end of surgery is not helpful. Also, bringing SET up a leg quickly (i.e. in a few seconds) shifts >500 cc of blood (over 1.1 pints) from each leg to the core. This can easily cause a temporary spike of BP. "Tourniquet Pain," which is common with pneumatic tourniquet, but is not seen when SET is placed in the correct designated sites, is a well-known cause of BP rising during surgery with pneumatic tourniquet, but not with SET. Finally, taking frequent BP readings (eg, every 3-5 minutes) is the best way to notice early that BP is creeping upwards. Paying attention to these details by the entire OR team helps prevent mishaps resulting in rising BP and blood seeping under the SET ring.

CONTRAINDICATIONS AND WARNINGS

The use of SET is contraindicated in the same cases where the use of Esmarch bandage is contraindicated, namely:

1. Active deep vein thrombosis (DVT) in the operative limb; use the Wells Criteria to screen for DVT.*
2. Infection in the operated limb.
3. Cancer in the operated limb.

In addition, the use of SET is limited to 120 minutes (same as for pneumatic tourniquet and military tourniquet). It is also recommended to wrap the limb with an elastic bandage prior to applying the SET if the skin is damaged or paper-thin.

*The issue of DVT deserves special attention. The use of Esmarch bandage[20,21,23,24,25] as well as SET[22] has been associated with dislodging of a thrombus into the circulation causing fatal pulmonary embolus. As such, any patient with even a low level of DVT suspicion must be evaluated carefully using clinical examination, D-dimers, ultrasound or venography to rule out DVT before Esmarch or SET are applied. Using a pneumatic tourniquet without exsanguination is strongly discouraged.

Note 2. SET used during the cementing of an implant (eg, in TKA). Some surgeons prefer to inflate the pneumatic tourniquet only during the application and setting of the cement (with or without Esmarch bandage exsanguination). Likewise, SET can be applied only for this part of the operation. The instruments are removed, the incision is covered with a lap-pad and the SET is applied. The exsanguination guarantees dry field which improves the penetration of the cement into the cut-bone trabeculae. The SET can be cut away as soon as the surgeon feels it is time to do so.

HOW IS SET SKIN PRESSURE DETERMINED?

It is customary to document tourniquet pressure in the patient's OR/anesthesia chart. With the pneumatic tourniquet the cuff pressure is read from the pump's display, assuming that it is properly calibrated. The SET pressure is determined by measuring the limb circumference at the site of the SET ring placement and the distance from the toes/fingers to the ring. A look-up table showing the circumference versus the distance is used to determine the pressure in mm Hg. The pressure tables such as the one shown in is used to determine the exact skin pressure. The measurement of the circumference determines exactly how much the SET is stretched (expanded), and the distance from the toes/fingers tells how much of the stockinet has been removed from the ring thereby reducing the force.

BIOMECHANICS AND PHYSIOLOGY OF APPLYING A TOURNIQUET TO A LIMB

All tourniquets – including blood pressure cuffs, pneumatic tourniquet, the SET and the first aid/military tourniquets used to stop bleeding – exert pressure on the surface of the limb in order to collapse the arteries leading into it and block the inward blood flow. To do so, the pressure applied to the arteries must be greater than the systolic blood pressure over a short segment of the vessel. In normal arteries, just a few mm Hg are sufficient to collapse the artery, but if the arteries are calcified and stiff, the pressure should be much greater in order to overcome the stiffness. In some patients the arteries are so stiff that it is not possible to collapse them at all. Such arteries can usually be visualized on X-ray due to the radio-opacity of the atheromatic calcifications. This X-ray finding is not a contraindication to using a tourniquet, including SET, but the surgeon must be aware of the possibility that the artery may not be occluded, and observe the color of the skin, before making the first incision.

A great deal of debate has been held over the issue of tourniquet width. When measuring blood pressure, it is recommended that the cuff needs to be wide enough to ensure that the pressure in the tissues beneath the cuff is uniform and the same as the cuff pressure. This guarantees accurate BP measurement. Unfortunately, this notion of the use of surgical tourniquets has not been proven with proper scientific evidence. In fact, biomechanical analysis of the pressures beneath wide and narrow surgical tourniquets show that it is exactly the opposite. A finite element analysis of the stresses (pressure) and strains (deformations) of tissues beneath tourniquet[5] shows the pressure field in the tissue beneath a wide pneumatic tourniquet and a narrow SET ring (Figure 2). The analysis shows that, as expected, the pressure beneath a wide pneumatic tourniquet (left panel) is uniform and high with steep gradients at the two ends of the compressed segments. On the other hand, the pressure field beneath the SET is the same at the surface of the limb (ie, skin pressure) of the pneumatic tourniquet, but it dissipates

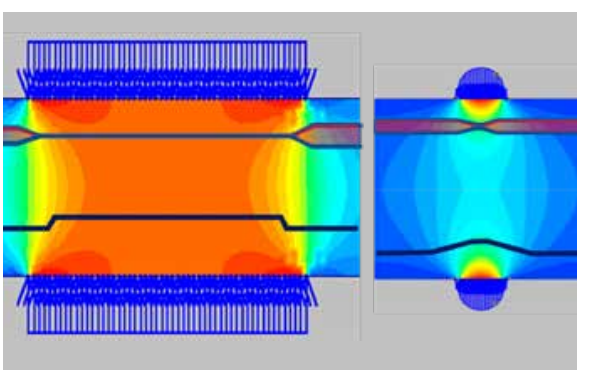

Figure 2. *Pressure fields beneath a pneumatic tourniquet (left) and SET ring (right) obtained from finite element analysis of the forces and pressures in the tissues of a limb.*

gradually as tissue is penetrated deeper (right panel). In normal BMI patients, the artery is about 1 cm deep in the upper arm and about 2.5 cm deep in the thigh. This means that higher skin pressure is needed when SET is applied to the thigh than to the arm. Similarly, in obese or very muscular patients, the artery passes deeper inside the limb and as such, higher skin pressure is required to collapse it and block the blood flow. Figure 2 also shows an artery (top) and a nerve (bottom). The artery beneath a pneumatic tourniquet is collapsed over a larger distance. The nerve is abruptly deformed at the two ends.

PATHOPHYSIOLOGY OF SKIN, MUSCLE AND NERVE COMPRESSION BY PNEUMATIC TOURNIQUET AND SET

Compressing a limb in order to block arterial flow applies pressure and deforms the tissues. This is an inevitable result of applying any tourniquet. However, when applying a wide pneumatic tourniquet, a much larger amount of tissue is compressed than is needed. The compressed tissues tend to migrate toward the distal and the proximal ends of the cuff. This is particularly detrimental when the nerves are concerned, as reported by Ochoa et al in 1973.[7]

Ochoa and co-workers applied tourniquets to baboons' limbs and noted an interesting phenomenon: the nerves that were compressed beneath the tourniquet elongated and telescoped into themselves and the Nodes of Ranvier, causing axonal disruption. Ochoa found these nerve telescoping events only proximally and distally to the cuff, and concluded that the wider the cuff, the higher the risk of nerve damage associated with pneumatic tourniquet. Ochoa also pointed to the steep pressure gradient at the two ends of the cuffs causing transverse shearing effect on the nerves, presenting another potential cause of nerve damage by the wide cuff. The rate of pneumatic-tourniquet-associated nerve damage is between 1:4000 to 1:1000 and is presenting as the leading cause of malpractice litigation in joint replacement surgery.[26] The narrow ring of the SET is not wide enough to cause nerve elongation and the gradients at its two ends are shallower, making for less of a chance for nerve damage.

Skin damage and blister formation is another adverse effect of using pneumatic tourniquet. In a study performed in Stockholm[8] it was found that despite individualization of tourniquet pressure by using LOP, 20.7% of the patients had blisters on their thigh four days after a state-of-the-art pneumatic tourniquet was used to provide a bloodless surgical field during TKA. The mechanism of these blisters is often blamed on chemical effect on the skin beneath the tourniquet cuff. However, the cause is the uneven inflation of the inner surface of the cuff, causing pinching and mechanical detachment of the epidermis and blisters.

Review of FDA depository of medical devices-related problems[27] revealed hundreds of entries related to malfunctions and injuries caused by pneumatic tourniquets. There are two SET-related Maude reports from 2011; one on skin-tear caused by dragging (pushing) the SET up an arm of a hemodialysis patient, instead of rolling it by pulling the straps; the other was a complaint on pain listed by a sales associate who trialed SET without anelgesia.

Perhaps the most concerning and common aspect of using pneumatic tourniquets is the post-operative tourniquet pain. For many patients this pain is more debilitating after surgery than the incisional pain. This is noticed in all uses of pneumatic tourniquets, and often becomes the limiting factor in early discharge of patients after TKA ("fast track"). If a patient has too much pain to ambulate to toilet and requires narcotic drugs, they may be less likely to be discharged early, adding to the cost of surgery and to patient dissatisfaction. In the same Stockholm study[8] it was found that 39.7% of post TKA patients done with the pneumatic tourniquet with individualized tourniquet pressure and curved cuff had significant thigh pain four days after surgery. Other studies done with pneumatic tourniquets have shown similar results.[28-31] Studies comparing post-op pain with pneumatic tourniquet and with SET have all shown significantly reduced post-op pain when SET was used.[30]

The pathophysiology of tourniquet pain can be understood from observing the MRI of a limb done while the subject had an inflated pneumatic tourniquet on the patient's thigh. In addition to the skin and muscle compression and displacement, it is possible to see the fascia of the muscle as a dense white line. The fascia had been deformed and stretched. Pain receptors are mostly present in the fascia. The pain sensation is conducted by the thin, poorly myelinated slow C fibers leading from the fascia to the spinal cord, leading the pain sensation to the brain. This case further illustrates the reason as to why placing tourniquets directly on major muscles is not recommended. It also explains why the use of SET is associated with less tourniquet pain (if any) when placed at the recommended positions. These positions are chosen to be over parts of the limb where there are fewer (or no) muscles and as such less fascia. The specific positions are: 10 cm above the wrist, distal to the forearm muscles groups;

on the upper arm above the biceps and below the deltoid muscle; on the ankle below the calf muscles and in the groin area very high up on the thigh, above the upper pole of the quadriceps muscle.

PHYSIOLOGY AND BIOCHEMISTRY OF TISSUE ISCHEMIA AND TISSUE COMPRESSION BY PNEUMATIC TOURNIQUET AND SET

Whenever a tourniquet is placed on a limb it intentionally causes ischemia. Unlike the heart and the brain that have very little reserves before loss of function (eg, loss of consciousness, cardiac arrest) and irreversible damage occurs, the tissues of the limbs can withstand a relatively long period with no oxygen supply. The muscle has energy reserves in the form of creatine phosphate that can rapidly release its high energy phosphate stores to create ATP directly. These stores are not large, and the cells continue to consume the dissolved oxygen until its level is too low to generate ATP from glucose or fat. At this point, anaerobic metabolism kicks in to generate ATP by glycolysis with the end products being lactic acid and pyruvic acid instead of CO2. This anerobic metabolism is less efficient than the aerobic one and the lactic acid causes acidity (reduced pH). This process continues until there is no more substrate (glucose) and at this point depletion of ATP causes cell membrane disruption and necrosis. The muscle of a fit person with normal blood supply can withstand longer periods of ischemia than in a person suffering from chronic poor blood supply such as in peripheral vascular disease (PVD). Likewise, a person with chronic lung disease may start the ischemia period with less O2 in the limb. The temperature of the limb also influences the metabolic rate. It is recommended that 120 minutes is the maximal duration of safe limb ischemia in all patients. If the case is longer, the tourniquet/SET must be removed for enough time to restore oxygen and ATP stores (typically 15-20 minutes) before ischemia is induced again. If SET is used, it needs to be completely removed and a new one placed. If a pneumatic tourniquet is used, the pressure must be completely reduced to zero to avoid venous occlusion, and excessive bleeding and swelling of the limb. Before the tourniquet pressure is restored, the limb should be exsanguinated again to the greatest extent possible. Excessive tissue hypoxia is thought to be associated with generation of reactive oxygen species[9] and limb swelling.

The other unavoidable effect of applying pressure to soft tissue is the compression of the tissues beneath the tourniquet. This is sort of a localized "crush injury" and its effects should be taken into consideration. When a muscle is compressed for an extended period, biochemical substances may leak from the muscle cells, either by diffusion through cell membrane or due to disruption of the cells' walls. Muscles contain enzymes and large molecules such as creatine phosphokinase (CPK), lactic dehydrogenase (LDH) and myoglobin, but also leak small molecules and ions such as potassium (K+) and lactate. One study measured nerve conduction speed with a wide vs. narrow tourniquets in normal volunteers, showing significantly slower conduction with the wide tourniquet.[11]

THE IMPORTANCE OF COMPLETE EXSANGUINATION THE LIMB BEFORE A TOURNIQUET IS USED

From early on, it was customary to empty the limb from blood as much as possible before a pneumatic tourniquet is applied. The two methods commonly used are limb elevation and tight application of Esmarch bandage from distal to proximal. Blond et al used radioactively tagged red blood cells and a gamma camera to obtain quantitative data on the quality of limb exsanguination with these methods.[12] They found that limb elevation, irrespective of elevation duration from 0.5 to 10 minutes, removed approximately 45% of the blood, while applying an Esmarch bandage removed 67% of the blood. In other words, at least half or a third of the blood remained in the limb for the duration of the tourniquet time with no flow.

However, the clinical importance of incomplete exsanguination is different. In 1979, it was shown that after 15-20 minutes stagnant blood coagulates to form soft-fresh clots.[13] In 1993, Parmet et al[35] used a transesophageal Doppler probe to track the blood flow in the right atrium, at the time a pneumatic tourniquet is deflated at the end of a primary TKA. They observed showers of echogenic material starting 15 seconds after the deflation and continuing for as long as 15 minutes in all patients. This study was repeated by multiple researchers with the same results. The debate whether the echogenic material was blood clots, bone debris, fat, air bubbles, or cement was finally settled by inserting catheters into the femoral veins and pulmonary artery of patients undergoing TKA and aspirating blood right after the tourniquet was deflated. Microscopic examination of the aspirated blood showed only fresh clots and no other types of granular material that could give echo in ultrasonic Doppler examination. The conclusion from these studies is that upon pneumatic tourniquet deflation at the end of surgery, clots migrate from the patients' leg veins to

the right atrium and from there to the pulmonary circulation causing multiple small pulmonary emboli. The physiological consequences of such interference with pulmonary blood flow is a rise in pulmonary arterial blood pressure and a drop in left ventricular output, which contribute to the drop in systemic blood pressure.

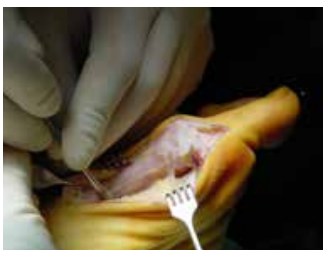

This pulmonary embolization, however, is not the worst part of this sequence. In about a quarter to a third of the population,[14] the embryonic foramen ovale is not completely fused and is only closed with a flap that acts as a one-way valve, preventing blood to pass from the left atrium to the right. However, when the pressure in the right atrium is higher than in the left, right-to-left shunting of blood occurs. If this blood contains clots, the clots will also cross over into the left heart and from there to the systemic circulation, with preference to the carotid arteries that are first to emerge from the aortic arch. It is not surprising that in 1999 Sulek et al,[15] who used transcranial Doppler to monitor blood flow in the Circle of Willis which supplies the entire cerebral circulation, found echogenic material in over 50% of the patients undergoing TKA within 20 seconds after the deflation of the tourniquet.

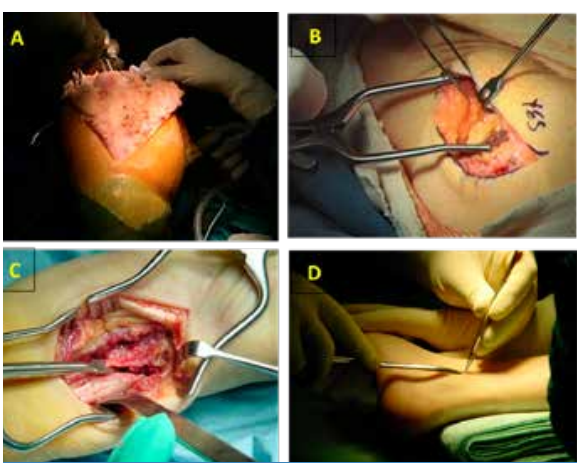

Figure 3. *Images from cases done with SET showing the level of field dryness. A – TKA in an obese patient; B – Elbow surgery in a child; C – ORIF of distal radius fracture in an elderly woman; D – Ankle ligaments lengthening in an 18 years old female CP patient.*

In yet another study, David et al[16] performed MRI studies on TKA patients, once before surgery and again two days after surgery. In five of the patients (23%), they detected cerebral infarcts in the post TKA images that were not present before surgery. Other researchers suggested that these infarcts are the cause of the well-known post-TKA Cognitive Dysfunction Syndrome.

Given the fact that limb exsanguination is 95% complete when SET is used[19] (Figure 3), with the only remaining blood being in the bone marrow, it is unlikely that intravascular clots will be formed during the period of stagnation. While there are no studies that have been performed to date on the incidence of echogenic material after SET is removed, there are also no reports of post TKA cognitive issues when SET is used.

DEFLATING PNEUMATIC TOURNIQUETS AND REMOVING SET AT THE END OF SURGERY

Stopping the blocking of arterial blood flow at the end of surgery is done by deflating the pneumatic tourniquet or by cutting the SET ring with a scalpel. Once this is done, blood returns to the empty blood vessels of the limb. In fact, more blood returns to the limb than was originally removed because of the physiological phenomenon called "reactive hyperemia." This is a normal compensatory vasodilatation of the limb blood vessels after a period of ischemia. It can easily be seen as redness of the skin which lasts from a few minutes to a half hour. If suturing and compression-dressing of the limb is delayed until after tourniquet/SET removal to facilitate meticulous hemostasis, the reactive hyperemia contributes to increased blood loss. It is imperative to deflate the tourniquet completely in order to avoid venous occlusion, which may further increase blood loss and can cause swelling of the limb, and in rare cases compartment syndrome. The removal of the pressure of SET is complete when it is cut with a scalpel.

Systemic blood pressure falls when pneumatic tourniquet is deflated and when SET is removed. This is primarily due to the return of blood from the central circulation to the limb.

SUMMARY AND CONCLUSIONS

SET is a viable safe and effective alternative to the use of pneumatic tourniquets with Esmarch bandage to provide bloodless surgical field during limb surgery. Tables 1-2 compare side-by-side the effects of using each of the methods on patient safety and on OR workflow. Table 3 summarizes the cases categories where using the SET is most advantageous.

Table 1. Patient safety and outcome advantages with SET vs. pneumatic tourniquet

Category	SET	Pneumatic Tourniquet	Comments
Sterility	Always; the ring is cut at the end of surgery	Often re-used as non-sterile	Reprocessed (sterile) pneumatic tourniquets are also available
Intra-operative blood loss	Negligible	May be as much as few hundred CC	
Intra-op tourniquet pain	None	Frequent	Causes rise in BP and need for anesthetics
Post-op tourniquet pain	Seldom	Frequent (39.7% of patients)8	SET needs to be placed on the designated positions
Use of pain medications	Less	Significantly more	
Skin damage	None	Frequent (blisters in 20.7%)8	
Long-lasting nerve damage	None	1:4000 to 1:1000	Also known as Neuropraxia
Use for upper arm surgery	The narrow ring CAN be placed high up on the arm; broader incision space	Often takes too much space, even if sterile	ORIF of humerus without tourniquet may require 1-2 pints of blood
Use for femur/thigh surgery	Easy to place SET all the way up to the groin	Often takes too much space, even if sterile	ORIF of Femur fracture often requires blood transfusion
Exsanguination	95%	45% with limb elevation, 67% with Esmarch Bandage	See text for significance
Tourniquet time	8-10% shorter than with PT		Most important in pediatrics
Tourniquet failure	Occasional, when BP rises	Happens when air leaks or pump fails	
Postop Deep Vein Thrombosis (DVT); Pulmonary Emboli (PE)	Significantly less than with pneumatic tourniquet	3-7% of patients	Mechanism of reduced DVT/PE with SET not known

Table 2. Effects of using SET on OR workflow and logistical considerations

Item	SET	Pneumatic tourniquet	Comments
Pump	Not needed	Pump needs to be bought or leased	Pump pressure must be calibrated periodically
Tubes	Not needed	Tubes need to be replaced periodically	Tubes connection to PT occasionally fails
Positioning	SET never rolls down if placed in the correct sites	Cuff often migrates distally on conical limb when inflated	Distal migration of non-sterile tourniquet requires re-draping
Space ("real estate")	SET is narrow and when placed proximally on the limb, gives optimal space and exposure	Pneumatic tourniquet is wide, limiting incision space	Important when working on the upper arm/elbow and thigh and when revision knee is performed
Mobility	SET does not trap the ligaments or the muscle beneath it, permitting full ROM of fingers, toes and knee	When pneumatic tourniquet is placed on the forearm/ankle, it splints the ligaments, limiting toes/fingers motion	Trying to forcibly flex the knee with pneumatic tourniquet at mid-thigh on the quadriceps muscle may cause muscle fibers tears.
OR air quality due to use of electrocautery	Less frequent use of cautery due to dry field;	Cautery is frequently used.	Cautery pen/forceps can be opened on demand when SET is used
Use on obese patients	XL Model readily used, never rolls distally	Often migrates distally when inflated	PT requires tech repositioning under drapes
Need for cell saver/ autotransfusion	Not needed	Often used in bilateral TKA, trauma	
Preparations for case	Single item needed for a case	Cuff, padding, stockinet, Esmarch bandage, pump setting and manning	
Cleanup after case	SET is discarded, no additional handling	Cuff reprocessing requires handling and cleaning by tech	
Pressure documentation	Requires measuring circumference and distance from toes/fingers	Read directly from pump display	
Timer	No built-in timer; needs an OR clock/timer	Timer built into pump	

Table 3. Cases of clinical importance and/or economic advantage of SET

Type of case	Clinical importance	Economic advantage
Surgery of upper arm and femur	Not enough space for PT, even if sterile, full, free ROM	No intra-operative blood loss, reduced need for transfusion
Knee arthroplasty revision	Larger operative space	Faster procedure, never need to re-do drapes
Bilateral TKA	Less blood loss; can work simultaneously on both knees	
Knee arthroscopy ACL reconstruction	Longer harvested hamstring autograft	Obviates need for allograft
Obese patient; eg, BMI>32	Optimal exsanguination, quicker procedure	Never need to re-do drapes
Pediatric cases; eg, four years old and younger	No migration of tourniquet, larger real estate, no skin injury, shorter case	
Patients with low pre-op hemoglobin; eg, Hb < 9 g%	No intra-op blood loss, reduce the need for blood transfusion	No need for cell saver or auto-transfusion20
Patients with bleeding disorders; eg, hemophilia	No intra-op blood loss, reduce the need for blood transfusion	No need for cell saver or auto-transfusion20
Patients in which blood transfusion is not possible; eg, Jehovah Witnesses, rare blood type, organ transplant candidates	No intra-op blood loss, reduce the need for blood transfusion	No need for cell saver or auto-transfusion20
Patients with immune deficiency; eg, steroids, HIV, diabetes	Lower risk of infection due to SET sterility, less need for cautery, suctioning, pulse lavage	Lower risk for Surgical Site Infection (SSI)

DISCLOSURE

Noam Gavriely is the founder, shareholder and executive of Oneg HaKarmel Ltd., manufacturer of HemaClear® Surgical Exsanguination Tourniquet.

ACKNOWLEDGEMENTS

Ana E. Puig, Certified Surgical Specialists lll, Ortho Trauma - Ortho/Neuro Spine prompted the preparation of this manuscript, read it and commented. Larry Murdock, RRT, assisted in preparing the paper and proofreading it. Both are affiliated with OHK Medical Devices Inc., the distributor of SET (HemaClear®) in USA.

REFERENCES

1. 1911 Encyclopædia Britannica/ Esmarch, Johannes Friedrich August von - Wikisource, the free online library
2. Cushing, H. *Pneumatic tourniquets: with especial reference to their use in craniotomies.* Medical news; 1904. p. 577.
3. Saied, Alireza, et al. Tourniquet in Surgery of the Limbs: A Review of History, Types and Complications. *Iran Red Crescent Med J.* 2015 Feb; 17(2): e9588. https://www.ncbi.nlm.nih.gov/pmc/articles/PMC4353220/
4. Surgical Exsanguination Tourniquet (SET) www.hemaclear.com
5. Levenberg, E. The Mechanical Response of Limbs to a Tourniquet Application Part 1: Axisymmetric and Plane-Strain Analysis and Part 2: A Study of the Interaction between the Auto-Transfusion Tourniquet and a Limb. OHK Medical Press, April 2002.
6. Mehmet, Faruk; Catma M. F.; and A. Ozturk. The effect of tourniquet type and thigh conicity on the length of hamstring autograft. *J of Ortho Surg.* 2019: 26(3) 1–6.
7. Ochoa J., Fowler T. J., Gilliat R.W. *Anatomical changes in peripheral nerves compressed by a pneumatic tourniquet.* J Anat 1972: 113(3): 433-455.
8. Olivecrona, C; Ponzer, S; Hamberg, P; Blomfeldt, R. Lower Tourniquet Cuff Pressure Reduces Postoperative

Wound Complications After Total Knee Arthroplasty - A Randomized Controlled Study of 164 Patients. *Bone Joint Surg Am.* 2012; 94:2216-21.
9. Clanton TL. Hypoxia-induced reactive oxygen species formation in skeletal muscle. *J Appl Physiol.* 102: 2379–2388. https://journals.physiology.org/doi/full/10.1152/japplphysiol.01298.2006
10. Parul Mitta*; Shweta Shenoy; Jaspal S Sandhu. Effect of different cuff widths on the motor nerve conduction of the median nerve: an experimental study. *J of Ortho Surg and Res* 2008, 3:1-6.
11. Blond L, et al. Exsanguination of lower limbs in healthy male subjects. *Acta Orthop Scand*. 2002; 73 (1):89–92.
12. Miller SH, et al. Intravascular coagulation and fibrinolysis within primate extremities during tourniquet ischemia. *Ann Surg.* 1979;190:227-230.
13. P T Hagen, D G Scholz, W D Edwards doi: 10.1016/s0025-6196(12)60336-x. Incidence and size of patent foramen ovale during the first 10 decades of life: an autopsy study of 965 normal hearts. Mayo Clinic Proc. 1984 Jan;59(1):17-20.
14. C A Sulek [1], L K Davies, F K Enneking, P A Gearen, E B Lobato. Cerebral microembolism diagnosed by transcranial Doppler during total knee arthroplasty: correlation with transesophageal echocardiography. *Anesthesiol.* 1999 Sep;91(3):672-6.
15. Peter, David. SAFE-TKR Study Group; the SAFE-TKR study group. Tourniquet use in total knee replacement surgery: a feasibility study and pilot randomised controlled trial (SAFE-TKR study). *BMJ.* Open. 2021 Jan 22;11(1).
16. Gavriely O, Nave T, Sivan S, Shabtai-Musih Y, Gavriely N. Auto Transfusion and Blood Pressure Elevation by Elastic Leg Compression in Normal Subjects. Rappaport, Technion. Haifa: Israel Institute of Technology; 2000. http://www.emergencyeed.com/ uploads/1/9/1/4/19141635/study_-_auto_transfusion_mk0036200_ compressed_2.pdf. Accessed October 20, 2013.
17. B. Borghi, E. Pignotti, M. Montebugnoli, A. Bassi, M. Corbascio, N. de Simone, K. Elmar, U. Righi, A. M. Laguardia, S. Bugamelli, F. Cataldi, R. Ranocchi, M. A. Feoli, T. Bombardini, G. Gargioni, A. G. Franchini and G. C. Caroli. Autotransfusion in major orthopedic surgery: experience with 1785 patients *Brit J of Anaesthe*. 1997; 79: 662–664 Also, http://www.aetna.com/cpb/medical/data/600_699/0639.html
18. Masri B.A., Eisen A, Duncan C.P., and James A. McEwen. Tourniquet-induced nerve compression injuries are caused by high pressure levels and gradients - a review of the evidence to guide safe surgical, pre-hospital and blood flow restriction usage. *The Surg Technol*. 2021, Vol 53 p 67-74.
19. Darmanis S, Papanikolaou A, Pavlakis D. Fatal intra-operative pulmonary embolism following application of an Esmarch bandage. *Injury.* 2002; 33(9):761-764.
20. Desai S, Prashantha PG, Torgal SV, Rao R. Fatal pulmonary embolism subsequent to the use of Esmarch bandage and tourniquet: a case report and review of literature. *Saudi J Anaesth.* 2013; 7(3):331-335.
21. Viktor Feldman, MD; Ahmad Biadsi, MD; Omer Slavin, MD; Benjamin Kish, MD; Israel Tauber, MD; Meir Nyska, MD; Yaron S. Brin, MD Pulmonary Embolism After Application of a Sterile Elastic Exsanguination Tourniquet. *Ortho.* 2015; 38(12):e1160-e1163
22. Lu, Chen-Wei MD*; Chen, Yi-Sharng MD†; Wang, Ming-Jiuh MD, PhD‡ Massive Pulmonary Embolism After Application of an Esmarch Bandage Anesthesia & Analgesia. 2004. 98(4):1187-1189.
23. M Páez , E Herrero Gento, F Buisán Garrido Rev Esp Anestesiol Reanim. Pulmonary embolism after placement of an Esmarch bandage for ankle surgery. 2003. 50(4):192-6.
24. A case of pulmonary embolism associated with pneumatic tourniquet deflation. Tsubota S, Watanabe T, Hamaura M, Miyamoto Y. Masui, *The Japanese J of Anesthe*. 2001 Mar; 50(3): 293-5.
25. Ashish Upadhyay, Sally York, William Macaulay, Brian McGrory, Jennifer Robbennolt, and B. Sonny Bal. Medical Malpractice in Hip and Knee Arthroplasty. *The J of Arthroplasty*. 2007. 22(6):2-7.
26. FDA Maude Depository of Medical Device Malfunctions and Adverse events. https://www.accessdata.fda.gov/scripts/cdrh/cfdocs/cfmaude/textResults.cfm
27. David Liu, FRACS,[1] David Graham, MBBS,[2] Kim Gillies, M Hlth.Sc,[3] and R. Mark Gillies, PhD[4] . Effects of Tourniquet Use on Quadriceps Function and Pain in Total Knee Arthroplasty. *Knee Surg Relat Res.* 2014 Dec; 26(4): 207–213.
28. Tourniquet pain in upper thigh. Discussion "Concerns after knee surgery." September 2017. https://bonesmart.org/forum/threads/tourniquet-pain-in-upper-thigh.5622/
29. Worland RL, Arredondo J, Angles F, Lopez-Jimenez F, Jessup DE. Thigh pain following tourniquet application in simultaneous bilateral total knee replacement arthroplasty. *J Arthroplasty*. 1997 Dec;12(8):848-52.
30. Estebe JP, LeNaoures A, Chemaly L, Ecoffey C. Tourniquet pain in a volunteer study: effect of changes in cuff width and pressure. Anaesthe. 2000 Jan;55(1):21-6.
31. Sanjay Bhalchandra Londhe, Ravi Vinod Shah, Shubhankar Sanjay Londhe, Pritesh Omprakash Agrawal, Nicholas A Antao, Sushil Churhe. Comparison of local pain and tissue reaction between conventional pneumatic tourniquet and disposable silicone ring tourniquet during Total Knee Arthroplasty. J Clin Orthop Trauma. 2020 Sep 9; 15:152-155.
32. Vicente J. León-Muñoza,*, Alonso J. Lisón-Almagroa, César H. Hernández-Garcíaa, Mirian López-Lópezb Silicone ring tourniquet versus pneumatic cuff tourniquet in total knee arthroplasty surgery: A randomized comparative study. J of Orthopae. (2018) 15:545–548.
33. Ismail Demirkale, Osman Tecimel, Hakan Sesen, Kasim Kilicarslan, Murat Altay, and Metin Dogan. Nondrainage Decreases Blood Transfusion Need and Infection Rate in Bilateral Total Knee Arthroplasty. The J of Arthroplasty. 2014. 29(5):993-997.
34. J L Parmet 1, A T Berman, J C Horrow, S Harding, H Rosenberg Thromboembolism coincident with tourniquet deflation during total knee arthroplasty. Lancet. 1993. 341(8852):1057-8.
35. Ved A, Kempshall PJ, Sharma H, Morgan-Jones RL. A comparison of operative field space between sterile single use and re-useable pneumatic tourniquets in revision total knee arthroplasty. *Inter J of Orthopae Scien.* 2015. 1(1): 01-03.

Optimizing the Bloodless Surgical Field in Limb Surgery

#457 JANUARY 2022 3 CE CREDITS $18

1. **Complete removal of blood from the limb (exsanguination) prior to occluding the blood flow is important because:**
   a. To prevent intra-vascular clotting of stagnant blood during surgery
   b. To avoid post-operative embolization of the lung and brain when the tourniquet is removed
   c. To facilitate a dry field and minimize cauterization
   d. All of the above

2. **The true statement(s) about post-operative thigh pain after TKA is:**
   a. Thigh pain is caused by stretching and deforming fascia beneath the pneumatic tourniquet
   b. Placing SET in areas where muscles and fascia are minimal help avoid post-operative pain
   c. Opiates are optimal for treating post-operative tourniquet pain
   d. Both a and b

3. **The recommended tourniquet time, irrespective of which tourniquet is used is:**
   a. 120 minutes
   b. 150 minutes
   c. 220 minutes
   d. 240 minutes

4. **Who first described the usage of a pneumatic tourniquet:**
   a. Harvey Cushing
   b. Johannes Friedrich August von Esmarch
   c. Christian Doppler
   d. None of the above

5. **Optimal placement of SET is:**
   a. By pulling the straps to the sides, perpendicular to the limb
   b. In the middle of thigh
   c. On the elbow
   d. None of the above

6. **Which statement about limb exsanguination is false?**
   a. Limb elevation removes about 45% of the blood
   b. Esmarch bandage exsanguinates 67% of the blood from the limb
   c. It is safe to inflate a pneumatic tourniquet without exsanguination
   d. Blood that remains in the limb for the duration of the case clots

7. **Contraindications for use of Esmarch and SET are:**
   a. Pre-existing deep vein thrombosis in the operated limb
   b. Infection in the operated limb
   c. Cancer in the operated limb
   d. All of the above

8. **When does right-to-left shunting of blood occur?**
   a. When blood passes from the right atrium to the left atrium
   b. When pressure in the right atrium is higher than in the left
   c. When the right atrium is higher than the left atrium
   d. When clots form in the left atrium

9. **The correct statement regarding tourniquet pressure is:**
   a. Pneumatic tourniquet applies pressure and compresses a larger volume of tissue
   b. SET skin pressure is the same as with pneumatic tourniquet, but is 30-40% lower inside the limb
   c. The pressure on the artery must be greater by at least 50-100 mm Hg to stop the blood flow
   d. It is necessary to collapse at least 5 cm of the artery in order to block the blood flow

10. **Tourniquet time should be limited to 120 minutes to:**
    a. Prevent surgeon fatigue
    b. Avoid complete depletion of all ATP in the muscle in all types of patients
    c. Be able to reuse the tourniquet another time
    d. Only b and c

OPTIMIZING THE BLOODLESS SURGICAL FIELD IN LIMB SURGERY #457 JANUARY 2022 3 CE CREDITS $18

AST Member No. _____

☐ My address has changed. The address below is the new address.

Name _____

Address _____

City _____ State _____ Zip _____

Telephone _____

☐ Check enclosed ☐ Check Number _____

If you want to mail in your CEs, but still want to pay by credit card, give us at call at 800-637-7433.

	a	b	c	d
1	☐	☐	☐	☐
2	☐	☐	☐	☐
3	☐	☐	☐	☐
4	☐	☐	☐	☐
5	☐	☐	☐	☐
6	☐	☐	☐	☐
7	☐	☐	☐	☐
8	☐	☐	☐	☐
9	☐	☐	☐	☐
10	☐	☐	☐	☐

Make It Easy - Take CE Exams Online

You must have a credit card to purchase test online. We accept Visa, MasterCard and American Express. Your credit card will only be charged once you pass the test and then your credits will be automatically recorded to your account.

Log on to your account on the AST homepage to take advantage of this benefit.



Earn CE Credits at Home

You will be awarded continuing education (CE) credits toward your recertification after reading the designated article and completing the test with a score of 70% or better. If you do not pass the test, it will be returned along with your payment.

Send the original answer sheet from the journal and make a copy for your records. If possible use a credit card (debit or credit) for payment. It is a faster option for processing of credits and offers more flexibility for correct payment. When submitting multiple tests, you do not need to submit a separate check for each journal test. You may submit multiple journal tests with one check or money order.

Members this test is also available online at ***www.ast.org.*** No stamps or checks and it posts to your record automatically!

Members: $6 per credit
(per credit not per test)

Nonmembers: $10 per credit
(per credit not per test plus the $400 nonmember fee per submission)

After your credits are processed, AST will send you a letter acknowledging the number of credits that were accepted. Members can also check your CE credit status online with your login information at ***www.ast.org.***

3 WAYS TO SUBMIT YOUR CE CREDITS

Mail to: AST, Member Services, 6 West Dry Creek Circle Ste 200, Littleton, CO 80120-8031

Fax CE credits to: 303-694-9169

E-mail scanned CE credits in PDF format to: ***memserv@ast.org***

For questions please contact Member Services - ***memserv@ast.org*** or 800-637-7433, option 3. Business hours: Mon-Fri, 8:00a.m. - 4:30 p.m., MT

Check us out on Pinterest!

AST
Association of Surgical Technologists

Pinterest

Follow us.

www.pinterest.com/assnsurgtechs

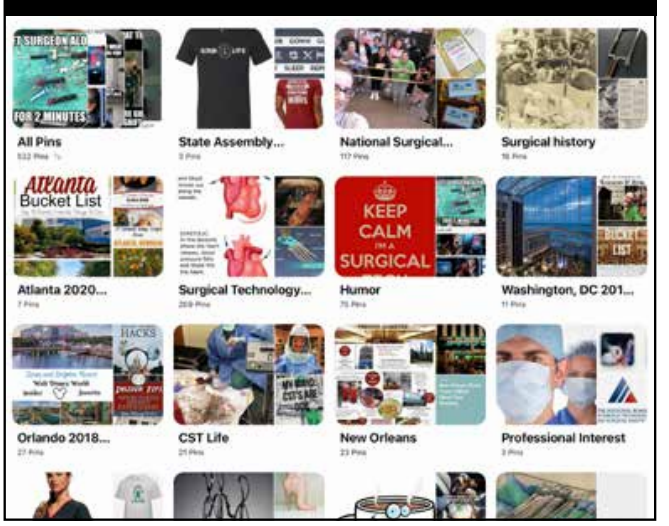

HemaClear®

Sterile & Bloodless Surgical Field

www.HemaClear.com